28.D.252

OPHTHALMIC SURGERY

MELLER

OPHTHALMIC SURGERY

A Handbook of the Surgical Operations on the Eyeball and Its Appendages as Practised at the Clinic of Hofrat Prof. Fuchs

BY

DR. JOSEF MELLER

PRIVATDOCENT AND FIRST ASSISTANT K. K. II, UNIVERSITY EYE CLINIC, VIENNA.

EDITED BY

DR. WILLIAM M. SWEET

CLINICAL PROFESSOR OF OPHTHALMOLOGY, JEFFERSON MEDICAL COLLEGE; PROFESSOR OF DISEASES OF THE EYE, PHILADELPHIA POLYCLINIC; ATTENDING SURGEON, WILLS' EYE HOSPITAL, PHILADELPHIA

WITH 173 ORIGINAL ILLUSTRATIONS

SECOND EDITION, THOROUGHLY REVISED

PHILADELPHIA

P. BLAKISTON'S SON & CO.

1012 WALNUT STREET

1912

The Right of Translation is Reserved.

Copyright, 1912, by P. Blakiston's Son & Co

THE · MAPLE · PRESS · YORK · PA

PREFACE.

In presenting the second edition of the work on Ophthalmic Surgery I desire to express to my former students and to the profession in general my gratification at the cordial reception which has been accorded the book. The text of the volume has been entirely rewritten, and the subject matter rearranged. Descriptions of new operations which have been found to be of value are added, and many new illustrations inserted to more fully demonstrate the operations described in the first edition and to render clear the additional material.

The revision and rearrangement of the descriptions of the various operative procedures are the result of personal consultation between the editor and myself. As all the chapters were read by me in the printed pages before the publication of the book, it was not considered necessary to follow the usual custom in translated books of indicating in brackets the comments of the editor.

As stated in the preface to the first edition, the volume is based on the lectures which I have given for years during the course in Ophthalmic Surgery at the Clinic of my Chief, Hofrat Professor Fuchs, in Vienna. It is not to be regarded as a complete treatise on Operative Surgery, but is designed to describe the most important operations as performed at his Clinic. My clinical education has been acquired under his valuable guidance, and a large part of the operative procedures herein set forth I have learned from him personally. Although designated by the names of their originators, many of the operations are described with the modifications and improvements which the extensive experience in our Clinic has gradually led us to adopt. Some of the methods, however, are essentially my own.

To Dr. W. M. Sweet are due my heartiest thanks and sincerest appreciation for his most thorough revision of this book, for his valuable suggestions and his numerous improvements.

JOSEF MELLER.

VIENNA, AUSTRIA, 1912.

Digitized by the Internet Archive
in 2011 with funding from
Open Knowledge Commons and Harvard Medical School

http://www.archive.org/details/ophthalmicsurger00mell

CONTENTS

CHAPTER I.

PAGE

EXCISION OF THE LACHRYMAL SAC 1

CHAPTER II.

EXCISION OF THE PALPEBRAL LACHRYMAL GLAND 22

Lachrymal probing, 25.

CHAPTER III.

ECTROPION 36

Spasmodic ectropion, 36; Snellen suture, 36; senile ectropion, 37; Kuhnt-Szymanowski operation, 38; paralytic ectropion, 45; cicatricial ectropion, 45.

CHAPTER IV.

TRICHIASIS AND ENTROPION 51

Trichiasis, 51; Hotz-Anagnostakis operation, 51; Snellen operation, 55; Panas operation, 56; Kuhnt tarsal enucleation, 58; Flarer operation, 59; Jaesche-Arlt operation, 59; Spencer Watson operation, 59; spasmodic entropion, 62; Gaillard suture, 63; senile entropion, 63.

CHAPTER V.

CANTHOTOMY—CANTHOPLASTY—TARSORRHAPHY 65

Canthotomy, 65; canthoplasty, 66; Kuhnt operation, 67; tarsorrhaphy, 69; Arlt operation, 73

CHAPTER VI.

PLASTIC OPERATIONS ON THE EYELIDS WITH PEDICLED FLAPS—SYMBLEPHARON . . 75

Fricke operation, 75; Dieffenbach operation, 75; Dieffenbach-Büdinger operation, 77; symblepharon, 80; Rogman's operation, 81

CHAPTER VII.

PTOSIS 84

Eversbusch operation, 85; Hess operation, 90; Pagenstecher's sutures, 95; Motais operation, 96.

CHAPTER VIII.

THE EYE-MUSCLES 101

Convergent strabismus, 102; tenotomy of the rectus internus, 103; advancement and resection of the rectus externus, 108; advancement of the rectus externus with

PAGE

tenotomy of the rectus internus, 114; divergent strabismus, 116; tenotomy of rectus externus, 116; advancement of the rectus internus with tenotomy of the rectus externus, 116; exophoria, 117; paralytic squint, 118.

CHAPTER IX.

ENUCLEATION OF THE EYEBALL AND THE SUBSTITUTE OPERATIONS 119
Enucleation, 122; abscission, 128; evisceration, 129; evisceration, with insertion of a globe in the sclera, 129; enucleation, with implantation of a globe in Tenon's capsule, 129; enucleation, with implantation of fat in Tenon's capsule, 129; optico-ciliary neurotomy, 130; exenteration of the orbital cavity, 131.

CHAPTER X.

CATARACT 133
Extraction with iridectomy, 136; extraction without iridectomy, 153; extraction with peripheral iridectomy, 156; extraction of the lens in the capsule, 157.

CHAPTER XI.

CATARACT (CONTINUED) 178
Discission of congenital cataract, 178; discission for high myopia, 180; discission of secondary cataract, 183; iridotomy, 184; discission through the sclera, 186; linear extraction, 188

CHAPTER XII.

GLAUCOMA 193
Iridectomy, 193; anterior sclerotomy, 203; sclerectomy and irido-sclerectomy, 207; posterior sclerotomy, 211; cyclodialysis, 212; de Vincentiis's operation, 217; scleral trephining 219; operations for secondary glaucoma, 220; tonometry, 223.

CHAPTER XIII.

OPTICAL IRIDECTOMY—CONJUNCTIVOPLASTY—OPERATIONS FOR IRIS PROLAPSE AND ANTERIOR SYNECHIA 227
Optical iridectomy, 227; prolapse of iris, 231; conjunctivoplasty, 234; operations for anterior synechia, 237.

CHAPTER XIV.

OPERATIONS ON THE CORNEA 241
Paracentesis and cauterization, 241; Saemisch section, 241; tattooing the cornea, 242; conical cornea, 244; corneal staphyloma, 245; corneal transplantation, 246.

CHAPTER XV.

EXTRACTION OF FOREIGN BODIES FROM THE INTERIOR OF THE EYE 249
Magnetic foreign bodies, 252; non-magnetic foreign bodies, 255.

CHAPTER XVI.

MINOR OPHTHALMIC OPERATIONS 258
Subconjunctival injections, 259; operative treatment of pterygium, 261; operative treatment of trachoma, 264; the ophthalmic assistant, 267; anesthesia, 272.

INDEX 277

OPHTHALMIC SURGERY.

CHAPTER I.

THE LACHRYMAL APPARATUS.

EXCISION OF THE LACHRYMAL SAC.

Anatomy.—The operator should study in each individual case the relation of the *internal palpebral ligament* and the *anterior lachrymal crest.*

The Internal Palpebral Ligament.—If the finger is placed against the outer canthus, and both lids stretched toward the temple horizontally, the ligament is seen between the inner canthus and the nose as a well-outlined and prominent cord immediately beneath the skin. This ligament, also known as the tarsal ligament, arises from the lachrymal process of the superior maxillary bone, and divides into two branches, each of which is continuous with the upper and lower tarsus, respectively, thus fastening them to the bone. The upper extremity of the lachrymal sac lies immediately behind the horizontal part of the tendon, the remainder of the sac extending downward for its entire length.

The anterior lachrymal crest is the most important landmark throughout the operation. In thin individuals it may at times be seen through the skin; in others it may be found by gliding the finger or a pair of closed forceps along the lower orbital border in a direction upward and inward. It may be prominent or flat, superficial or deep. It is also subject to variations in its own contour. Where the crest forms a part of the lower bony orbital margin, it is always prominent, but in its upper half it is usually quite flat. The more superficial the crest, the more readily it is reached, and the easier is the extirpation of the sac; the deeper the crest, the more difficult the operation.

Indications for Excision of the Lachrymal Sac.—Operation is indicated in all cases of chronic blennorrhea of the lachrymal sac, (1) which lead to marked thickening of its walls and eventually to its dilatation, to total obstruction of the naso-lachrymal duct, or to the formation of a fistula; (2) when an operation (iridectomy, extraction of a cataract,

etc.) is to be performed on the eye of the corresponding side; (3) when a purulent infiltration of the cornea has taken place (infected erosion, ulcus serpens, etc.), as cauterization would not prevent the discharge from the diseased sac flowing over the denuded area and by its microörganisms producing new infections; and (4) in all dispensary patients who have not the time for a long course of treatment with sounds, a method that usually promises but indifferent results. Particularly is resection recommended if the treatment with probes has previously been carried out without substantial improvement.

Rendering the Operative Area Anesthetic and Anemic.—Most descriptions of the operation call attention to the probability of profuse hemorrhage and the difficulties that this accident entail. Cocain injected subcutaneously neither produces complete anesthesia nor anemia of the parts. The addition of adrenalin solution to the cocain accomplishes the desired result, and renders possible an almost

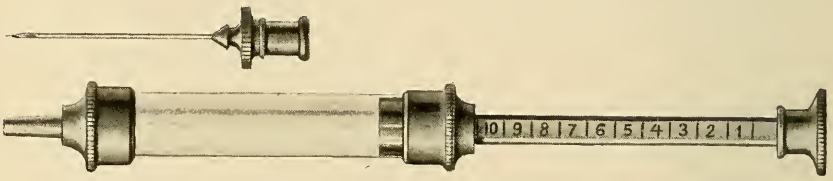

FIG. 1.—Pravaz's syringe. Capacity 1 c.c. Piston pulled out. The division lines represent tenths.

bloodless and painless operation. General anesthesia has many disadvantages and is seldom indicated.

After the conjunctival sac has been rendered anesthetic by a few drops of 3 per cent. cocain-solution, the lower canaliculus is dilated with a conical probe and a 1 per cent. solution of cocain injected into the sac by means of a lachrymal syringe. To prevent the fluid from flowing into the nose and eventually into the mouth, the patient should be placed in a sitting position with the head bent slightly forward. In most instances the fluid will escape through the canaliculi, particularly the upper. This preliminary procedure not anly anesthetizes but cleanses the sac, which is of decided advantage, for, although the sac itself is not injured during the operation, the canaliculi and nasolachrymal ducts are cut through, and the contained secretion may escape and contaminate the wound. But, in my experience, infection of the wound is of rare occurrence, and, should it occur, is never serious.

The injection into the deeper tissues is made with a syringe of 1 c. c. capacity (Pravaz's preferred, Fig. 1), which is filled with a solution composed of eight to nine parts of 1 per cent. cocain-solution and one to two parts of adrenalin or suprarenal solution (1–1000). One-third of the contents of the syringe is injected beneath the skin, the needle entering slightly below the tarsal ligament. This produces a slight bulging forward of the lachrymal-sac region, but massage causes the immediate disappearance of this swelling. The point of the needle is now inserted above the tarsal ligament and pushed vertically down to the bone. The syringe is then twisted forward 90° so that the needle is turned in the direction of the orbit. Holding it in this position the point is pushed forward closely along the periosteum and the second third of the solution injected, so that the tissue around the top of the lachrymal sac is infiltrated. With the remainder of the solution the region immediately about the entrance into the naso-lachrymal duct is anesthetized. The needle is now inserted below the tarsal ligament in a direction vertical to the lachrymal crest, the syringe turned so that the needle lies parallel to the bone, when it is pushed slightly backward. Should the point of the needle enter the lachrymal sac itself, recognized by the escape of fluid from the puncta, it must be pulled out somewhat and turned in a slightly different direction.

The stated quantity of adrenalin ($\frac{1}{10}$ to $\frac{2}{10}$ c.c.) suffices fully for the production of anemia. In my experience it has never been followed by bad after-results, either local, such as marked secondary hemorrhage or necrosis of the tissues, or constitutional. Occasionally a patient may complain of sudden distress, such as a sensation of oppression and palpitation of the heart, but these symptoms disappear shortly. In elderly patients with advanced arteriosclerosis, not more than $\frac{1}{10}$ c.c. of the adrenalin should be injected, and this amount will be sufficient. Dropping the adrenalin into the wound is unsatisfactory. After the sac has been peeled out, and before the probe is inserted into the nose, cocain should be dropped into the wound. The cocain will diffuse itself into the duct along the probe, and make the curetment almost painless.

Immediately after completing the injections, the operation may be commenced. In the majority of cases layer after layer of tissue may be removed without hemorrhage, as in the dissection on the cadaver. I have frequently resected lachrymal sacs in a few minutes without assistance. The incision through the skin may bleed more than

expected, as occasionally the skin contains abnormally large veins. The deeper parts are always absolutely anemic.

The method recommended for the extirpation of the sac has proved eminently satisfactory. It requires an accurate knowledge of the topographic anatomy of this region, which will be discussed as the various stages of the operation are described.

The Skin Incision.—The incision through the skin begins at a point 3 mm. above the ligament of the internal canthus and 3 mm. to the inner side of the canthus. The direction of this incision is downward, the upper half perpendicular or nearly so, and the lower half

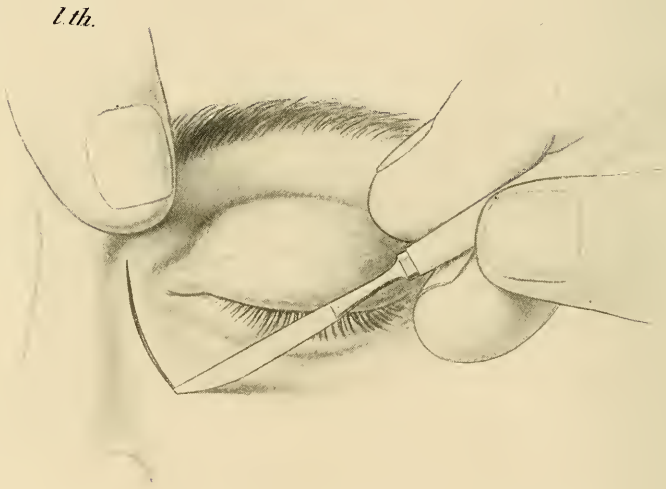

FIG. 2.—With the thumb of the left hand (l. th.) the skin is fixed, but not pulled or stretched. The cutting edge of the knife is directed vertically against the bone. The incision is downward, slightly outward and somewhat curved, 3 to 4 mm. distant from internal canthus.

curved slightly outward (Fig. 2). If, for instance, the upper half of the cut is not straight, but curved toward the upper lid, an ugly fold of skin is frequently produced at the upper angle of the incision during the healing process. While making the incision, which, by the way, corresponds to the direction of the crest but is situated several millimeters internally from it, the lids must not be pulled outward with the idea of making the skin tense. This prevents the incision from being made in the desired line. It is sufficient to press the upper inner part of the skin backward against the bone with the thumb. If we use a

sharp knife, slight pressure of the blade against the skin will indicate the direction of the incision, and then to deepen it the skin may again be stretched.

The length of the incision is not of much importance. The beginner should make a long incision (about $1\frac{3}{4}$ cm.), as this facilitates the dissection of the sac. The expert operator usually prefers a short incision. The length of the cut may vary, therefore, from 1 cm. to $1\frac{3}{4}$ cm. If the incision is more than 3 mm. from the internal canthus the difficulties of dissection are greatly increased, because the distance from the sac is proportionately greater.

Introduction of the Tear-sac Speculum.—After the cut is completed the lateral edge of the incision is lifted up and dissected from the underlying tissue with the scalpel turned toward the canthus, and the tear-sac speculum (Müller's) is introduced. This instrument is of great value, as it takes the place of an assistant and, by compressing the surrounding tissues, aids materially in hemostasis. The speculum is introduced closed, with its handle turned downward and slightly outward. The edges of the wound are first gently lifted with forceps, and the hooks fastened securely into the wound edges, so that no injury of the cornea be produced by any sudden jerk. An erosion is dangerous because of the great liability of infection. The patient must keep his eyelids closed throughout the entire operation.

The Superficial Fascia.—In the wound stretched by the speculum is exposed a delicate, thin, white membrane, the superficial fascia. The fascia may be considerably thickened toward the palpebral fissure by layers of connective-tissue fibers, some of which are joined with the ligamentum canthi, and radiate from it. They must not be confounded with the true ligament of the canthus, which belongs to a deeper stratum.

The scalpel with which the incision was made is put aside, and, until the completion of the operation, a pair of small slightly curved scissors is used, the blades of which have sharp points. With tooth-forceps a fold of the superficial fascia is picked up, transfixed with one blade of the scissors, and slit throughout the entire length of the wound, pushing it back toward both margins.

The Orbicularis Muscle.—In this way there is exposed a layer of red fibers, the orbicularis muscle (palpebral portion), the fibers of which, as is known, arise from the internal palpebral ligament. After locating the position of the anterior crest, the muscle overlying it is

slit up, and the fibers pushed back toward both sides with the closed scissors.

The Deep Fascia.—This brings to view in the floor of the operative wound a dense white membrane, the deep fascia, covering the lachrymal sac (Fig. 3) and extending from the anterior to the posterior lachrymal crest. Above, below and at the inner side the fascia becomes continuous with the periosteum of the neighboring bones; but at the

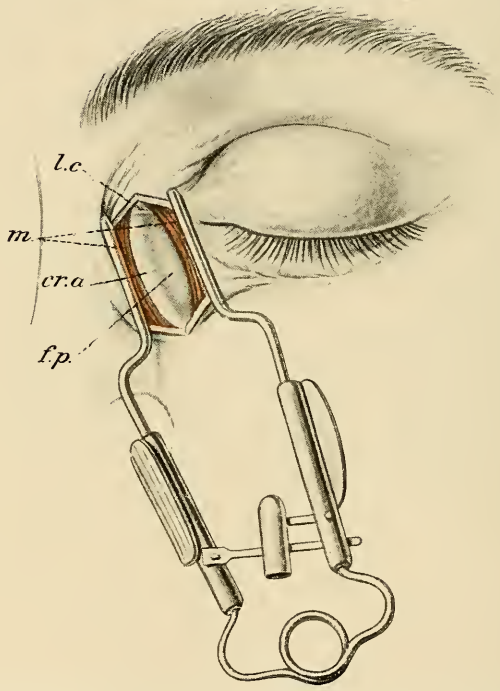

FIG. 3.—The separation and pulling to either side of the muscle-fibers (m.) exposes the deep fascia (f. p.) in the wound; behind this the sac must be looked for. In the upper angle of the wound are the transverse fibers of the ligament of the internal canthus (l. c.). Through the fascia the anterior lachrymal crest (cr. a.) can always be felt and can occasionally be seen.

posterior lachrymal crest it fuses with the orbital septum, thus completing the membrane which separates the lachrymal fossa from the orbit. The specially thickened upper portions of this fascia form a prominent dense cord which has already been referred to as the internal canthal ligament.

The fibers visible at this point may also be referred to as the anterior branch of the ligament. From it radiate bundles of fibers into the tarsus of the upper and

lower lid. In contradistinction to this, the portion of the fascia attached to the posterior lachrymal crest is spoken of as the posterior branch of the ligament. This arrangement, useful also because of the differences in insertion of the muscle-fibers, is understood without difficulty when a horizontal section of the skull made through the region of the canthal ligament is viewed. By pulling the lids outward an angular folding of the deep fascia is produced, which bounds a triangular space with the lachrymal fossa. Its floor is formed by the fossa itself, its branches (anterior and posterior) by the corresponding portions of the internal canthal ligaments. In this triangle is to be found the cross-section of the lachrymal sac.

At this stage of the dissection the operator sees neither the crest, unless it is abnormally prominent, nor the lachrymal groove. To note their exact positions, he must feel around with the forceps, gliding from the side of the nose toward the orbit. The anterior lachrymal crest must serve as landmark during the entire operation. By not dissecting too near the median line he will, on the one hand, escape the mistake of incising the periosteum of the dorsum of the nose, instead of freeing the lachrymal sac; and on the other hand avoid going in the wrong direction from the sac toward the orbit.

Exposing the Sac.—The deep fascia is now split with the scissors, inserted to the outer side of the anterior lachrymal crest, and ½ mm. behind it. This is not easy, even on the cadaver, if we wish to escape injuring the sac. The fascia is tense, and it is difficult to pick up a fold of the tissue for transfixion by the scissors. We are, therefore, forced to perforate it with one of the points of the scissors held almost parallel to the plane of the fascia. It is our custom to make the cut through the fascia ½ mm. behind the crest, and not, as done by others, directly on the crest. This makes dissection of the lateral wall easier.

As the sac lies immediately below the fascia, its anterior wall may be injured by cutting too brusquely. This is particularly true when the sac is not diseased, as on the cadaver, and the walls are thin and friable through beginning decomposition. For purposes of demonstration (it may also be done with the best of success on the living subject), it is as well to slit the fascia along its entire length with a narrow, pointed knife (the Graefe linear knife), holding it obliquely with the cutting surface forward. I prefer to use the scissors for this cut. The danger of injuring the tear-sac may be diminished by drawing away the fascia, grasping the ligament with the forceps, and pulling it outward and forward. Moreover, since the diseased sac is thickened, the danger of injuring it is reduced to a minimum. However, the operator should begin with a very short cut through the fascia so that,

even in case the sac is perforated, the wound need not be extensive. This cut should extend through the whole length of the membrane, and sever the ligament of the canthus at the same time. In the slit-like opening thus produced may be seen the lachrymal sac, readily distinguished because of its bluish color (Fig. 4). In operating on living patients, it is not uncommon to have the anterior wall of the sac bulge through the opened fascia in the form of a hernia.

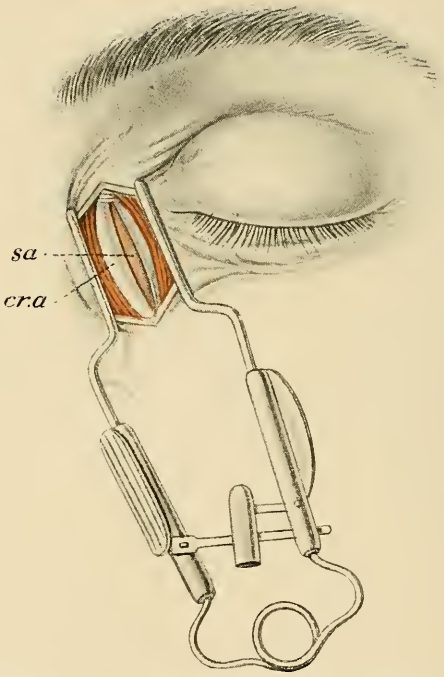

FIG. 4.—The deep fascia is incised throughout the entire length of the wound ½ mm behind (*i.e.*, to the side of) the crest (cr. a.). This lays bare the bluish-red lachrymal sac (sa.). The ligament of the internal canthus, which the figure shows to have been preserved, is cut through at the same time.

Removing the Sac.—The remainder of the operation consists in peeling the sac out of its bed. From now on, the operator must constantly keep close to the wall of the sac, and not injure the fascia or cut it away at the same time. There are no large blood-vessels in the loose tissue connecting the sac with its fascial capsule, and, therefore, during the dissecting there will be no annoying hemorrhage.

For the purpose of explanation it is best to distinguish only two walls of the lachrymal sac, the lateral (orbital), which is turned toward

the fascia, and the inner or median (nasal), which lies adjacent to the bone of the fossa. The designation anterior and posterior wall are altogether avoided in the description.

It is my custom first to separate the lateral wall of the sac from the fascia. For this purpose I pick up the lateral margin of the fascial wound with tooth-forceps and separate with closed scissors the delicate

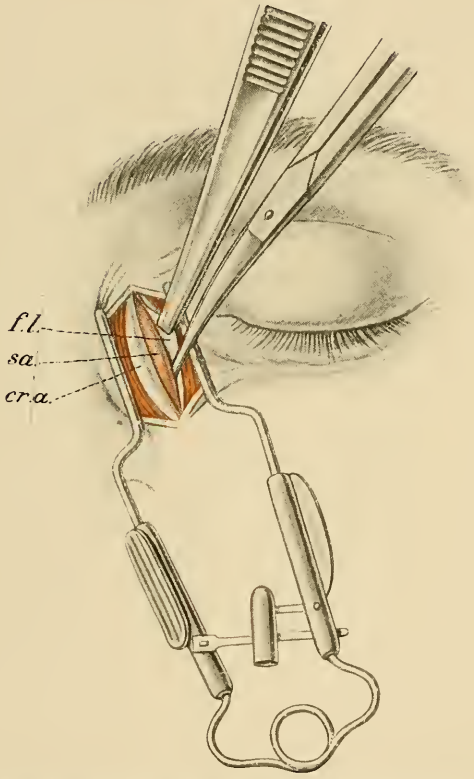

FIG. 5.—The lateral margin of the fascial wound (f. l.) is grasped with the forceps, and the closed scissors made to separate the loose areolar tissue between sac (sa.) and fascia, as far back as the bone.

connective-tissue fibers which connect the sac with the lateral wall of the fascia, *beginning in the lower half* of the wound (Fig. 5). With a few strokes the lateral wall is separated back to the bone.

It is only when the upper part is reached that a disturbing factor is met. At this point a bluish cord is seen going to the lid, the canaliculi (Fig. 6) which must be cut as close to the fascia as possible (Fig. 7)

—and not dissected by the closed scissors—or else a piece of the mucous membrane will be left hanging to the fascia.

The median wall of the sac is next loosened. Should the portion of the fascia left behind at the anterior crest be too broad to free the crest easily, it should be incised (i in Fig. 9). Gliding along the upper flat half of the crest with the point of the closed scissors, the wall of the sac may be readily separated from the bone as far as the posterior

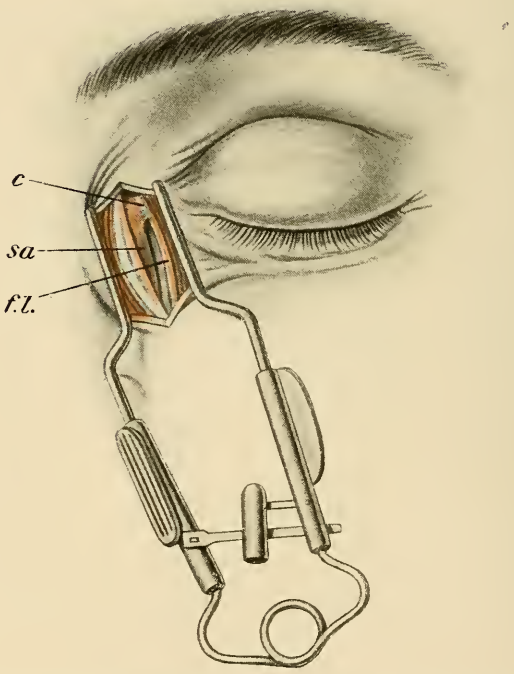

FIG. 6.—The lower half of the lateral wall of the sac is dissected from the deep fascia. The canaliculi (c.) are visible as a bluish cord above. f. l., lateral margin of the fascial incision; sa., sac.

lachrymal crest (Fig. 8). Although the periosteum of the lachrymal fossa could be spared with proper precautions we usually remove it together with the sac. The denuding of the bone is not significant of future disease.

When the upper half of the median portion of the sac has been freed, its lower half is peeled out from behind the prominently projecting crest without injuring the sac; but if the excision has been begun at the

lower steep portion of the crest, the sac will usually be injured. This is a mistake frequently committed by beginners.

The sac has now been cleared from all sides, but the upper extremity is still fastened to the surrounding structures, and the lower is continuous with the mucous membrane of the duct. For the first time since the operation began we can now grasp the entire sac with the

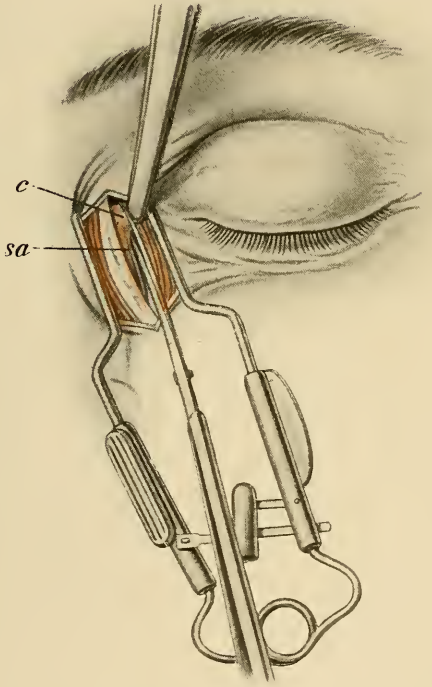

FIG. 7.—Cutting the canaliculi. One blade of the scissors, which must be applied parallel and close to the lateral fascia, is introduced far up behind the canaliculi (c.), the other is in front of them. One cut severs the canaliculi; sa., sac.

forceps without risk of tearing it, and dissect it out of the fascia, with which its top is intimately united, by making small nicks with the scissors as near as possible to the wall of the sac (Fig 9).

In freeing the top care is taken not to cut much tissue because of the danger of injury to large blood-vessels. In spite of the greatest caution, we sometimes have profuse hemorrhage. Because of this, I have recommended that the dissection of the upper extremity shall be

postponed until the entire sac has been completely shelled out. Even should a considerable bleeding then occur, it need not cause much annoyance, as the entire sac is safely held in the forceps.

As soon as the upper portion has been freed, the entire sac may be pulled forward. Should the posterior surface still be attached to the

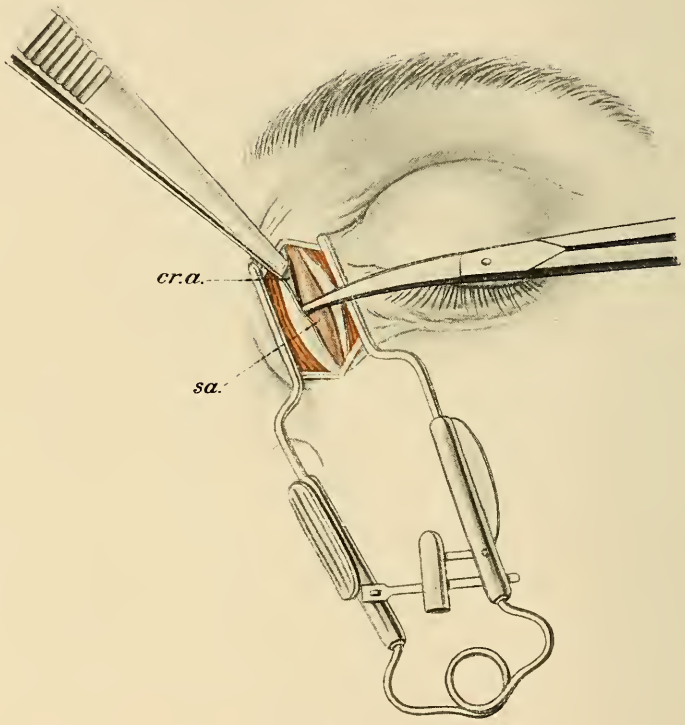

FIG. 8.—A short transverse cut (easily seen in Fig. 9 (i.), while in this drawing it is pulled to one side by the forceps) into the median margin of the fascial wound exposes the anterior crest (cr. a.); this makes it easy to push the closed scissors between the bone and sac (sa.) at the upper part of the crest and to loosen the sac. The point of the scissors is directed toward the bone.

bone by a few connective-tissue fibers, a few strokes with the closed scissors will suffice to separate it.

The sac is next dissected downward as far as possible. For this purpose I grasp the sac with the forceps at its lowest portion (Fig. 10), and, with the scissors from above downward near the wall of the sac, make several cuts in front and to both sides, freeing the path to the beginning of the naso-lachrymal duct. Finally, the vertically held

scissors are pushed down into the bony portion of the duct from the anterior or lateral surface, and the sac is cut through. While the assistant tampons the wound, I put the sac over a Bowman probe to convince myself by the intactness of the wall, that it has been removed as a whole. If the stricture is complete, the sac will have

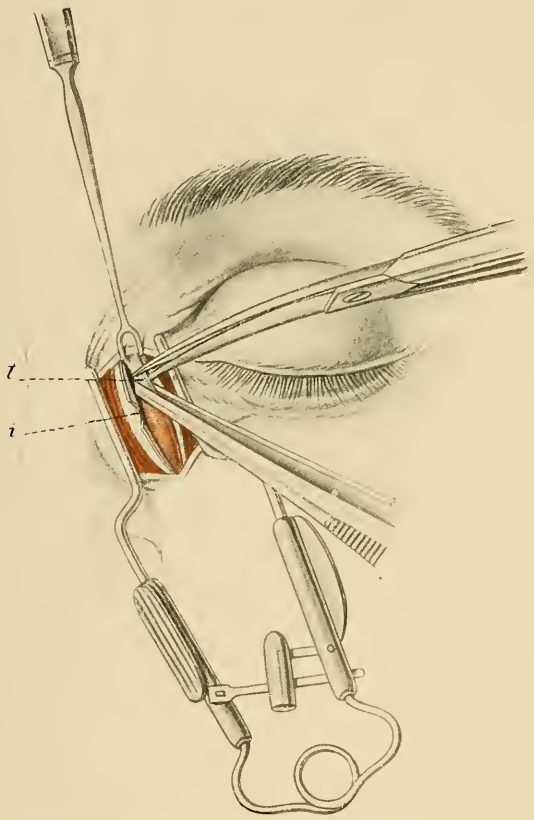

FIG. 9.—The sac, having been freed on both sides, is now for the first time grasped with forceps near its apex (t.) and separated from the surrounding structures with sharp cuts of the scissors as near the sac wall as possible. The upper margin of the wound is lifted up with a double tenaculum. i., transverse cut into fascia.

the appearance of a closed cyst, and the mucous lining is brought to view only after the sac has been cut open. If we now examine the wound cavity (Fig. 11), and this should never be omitted, we will see as the median boundary the lachrymal crest and the bony lachrymal fossa, deprived of its periosteum; and as the lateral wall the dense,

white, smooth, glistening deep fascia (the posterior branch of the internal ligament of the canthus), which completely separates the wound from the orbit. The sac does not properly lie within the orbital cavity, but rather outside it.

Cureting the Naso-lachrymal Duct.—The final procedure is to find the opening of the naso-lachrymal duct. The probe is placed ver-

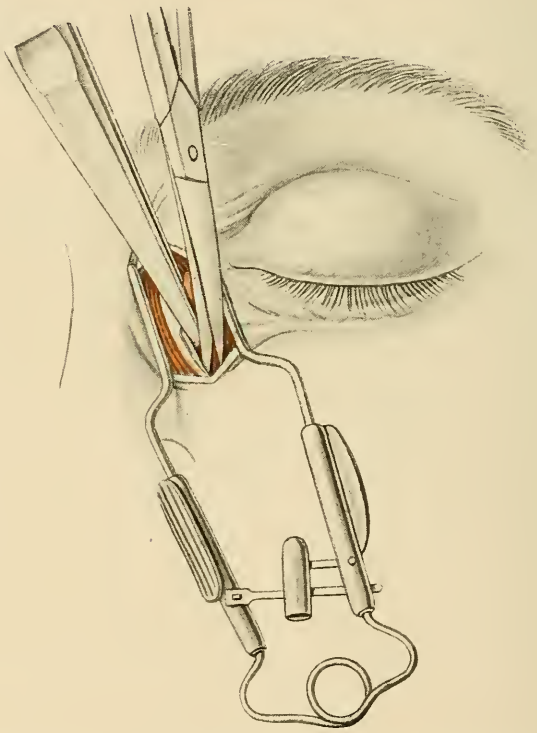

FIG. 10.—The sac, having been freed from the surrounding structures at all points except at its lowest portion, is grasped with the forceps low down; the vertically held scissors are made to cut away all the tissue attached to its lateral wall as close to it as possible until the naso-lachrymal duct is reached.

tically close to the bone immediately behind the anterior lachrymal crest and pushed downward. Should the passage be closed, the probe must be forced through the cicatricial tissue. In every instance this passage must be enlarged with a sharp curet, and all the mucous membrane found in the duct scraped away. Curetment of the cavity which contained the sac is not only unnecessary, if the sac has been excised properly, but superfluous. The naso-lachrymal duct is

probed in every case and made patulous by curetment, both to prevent possible secretion from the mucous membrane, and to provide drainage. Before closing the wound with sutures, it must be washed out with a weak corrosive sublimate solution, care being taken that the fluid will not enter the opened naso-lachrymal duct and through it reach the mouth of the patient.

The Sutures.—The skin of the neighborhood is thin, often easily torn, and usually curled up at the margins of the wound, and, if the

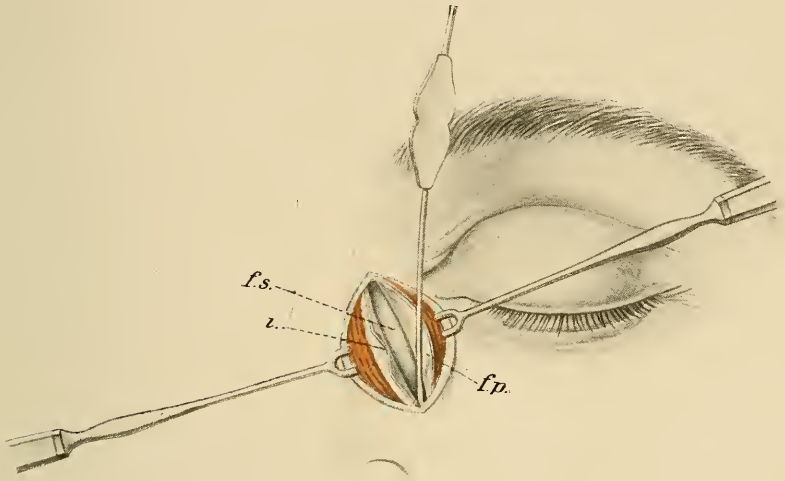

FIG. 11.—Operative field after completed excision.—The small portion of the deep fascia, which has been left behind, is seen hanging to the anterior lachrymal crest; on it the transverse incision (i.) is still visible. The saccal fossa (f. s.) is quite empty. The outer border is formed by the deep fascia (f. p.) which is firmly attached to the posterior lachrymal crest; it is of a white color and has a distinct luster. Behind the anterior crest is the probe, which passes through the duct into the nose.

edges are not perfectly apposed, primary union is impossible, and the relatively large wound must fill in by granulation. This retards healing and produces a broad and conspicuous scar, while the delicate scar following well applied sutures and healing by first intention is often hardly visible.

Three sutures suffice, if the wound is $1\frac{1}{2}$ to 2 cm. in length; if shorter, perhaps only two. Thin silk is the best material for the purpose. Small hooks, sharp and somewhat bent, are inserted into both the upper and lower wound-angle, and the wound somewhat stretched. The thin, sharply curved needles containing the thread are then pushed through near the margins of the wound. The assistant must well

adapt both margins with two pairs of forceps. He then turns the forceps to one side, so that the operator, who holds the looped threads parallel to the wound, can apply the knot readily at the side. The knots should only be drawn tight enough to maintain perfect adaptation, as the silk readily cuts through the easily lacerated skin. The threads must then be cut short. In order to prevent the possibility of secretion of the epithelium of the canaliculi, it is advisable to destroy the membrane by introducing the pointed end of a galvano-cautery.

The Dressings.—Before applying the dressing, the intactness of the corneal surface must be investigated. I have already called attention to the danger of an accidentally produced corneal erosion. The closed eyelids are first covered with a small pad of gauze to prevent erosion of the cornea by threads from any part of the dressing. A tightly rolled pad of iodoform gauze is pressed slowly and with gradually increasing force against the wound, thus obliterating the sac cavity. A second small pad made of the sterile gauze is placed on top of the iodoform gauze to ensure permanent compression. The eye is then covered with a few layers of gauze, and the entire dressing secured with a strip of adhesive plaster, which should be drawn tightly. Lastly the bandage is applied. The other eye remains open.

After-treatment.—On the following day the layers of gauze covering the eye are removed for the purpose of inspecting the cornea. The compression-pad, however, is not removed from the wound, the outer angle of the palpebral fissure being opened but slightly with the fingers. If the case progresses satisfactorily, the first complete change in dressings is made on the third day. On the fifth day the dressing is taken off, the stitches removed and the wound is found healed by first intention. Should the suture-openings bleed, it will suffice to dust them with xeroform or to close them for a day with adhesive plaster.

If, however, blood has collected in the wound-cavity, the progress of the healing is retarded. The cause of the accumulation of blood is nearly always incomplete compression of the wound. In this complication the patient complains of pain within a day or two after the operation, and upon removal of the dressings the wound is found to be bulging, and the skin dusky red and tender to the touch. It then becomes necessary to remove the sutures, and forcibly open the wound with a sharp sound or probe, in order to afford free drainage for the accumulated fluid. A small drain of iodoform gauze should be inserted and a moist antiseptic dressing applied.

Although this complication is annoying, it is usually found that in the course of a few days the wound fills with granulations and cicatrizes in a short time.

It is an entirely different matter, however, if the inflammation and accumulation are due to retained particles of mucous membrane of the sac—in other words, if the excision has been incomplete. This may happen occasionally to the most experienced operator; in the case of beginners it is not at all a rare occurrence.

Varieties of Sac Disease.—Inflammation of the lachrymal sac is met with in several different forms.

Acute Dacryocystitis.—In this affection no incision through the skin should be made unless perforation seems imminent. Applications of warm, moist, antiseptic dressings are to be continued until the inflammation has completely disappeared. At the end of a few weeks extirpation of the sac should be performed to prevent a return of the inflammation. Prior to the employment of cocain-adrenalin injections, profuse hemorrhage from the dilated blood-vessels was to be expected.

If perforation is unavoidable, an incision must be made down to the bone, and a tampon of moist iodoform gauze inserted.

Chronic Dacryocystitis.—Operation will often be required in patients who have been treated without success by repeated curetings, and it is then necessary to dissect the entire lateral wall and apex of the sac before a cure is effected. The operator should endeavor to remove layer after layer, at least as far as possible in the scar-tissue, instead of following the usual practice of cutting down in the first incision to the anterior lachrymal crest.

The anemia produced by the cocain-adrenalin infiltration in the dense scar-tissue is of decided advantage, as it permits the operator to see every step of the operation clearly. The bluish color of the mucosa readily differentiates it from the white of the scar-tissue, and in most instances the mucous membrane can be peeled off easily. This is then followed by a close scrutiny of the wound to determine that all the lining has been removed, and then, as in a completely performed excision of the lachrymal sac, the wound is closed by sutures.

Fistulous Dacryocystitis.—The most difficult cases are those in which a fistula has formed either after an acute dacryocystitis or following attempted extirpation. A much longer incision (2 cm.) is required to conveniently reach the fossa, and the fistula must be completely

excised. The incision, which at first is only through the skin, is at once deepened to the crest after the wound-edges have been dissected up and the cut well stretched with the speculum. The entire fossa is now cleaned out, thus excising all of the exposed scar-tissue. The lateral fascial boundary may often be found, so that after completing the operation there is presented the usual picture of the wound, *i.e.*, the median border formed by the bone with its prominent crest and the lateral border by the fascia. It is not advisable to use the curet, but prove by close inspection of the wound that none of the mucous membrane has been forgotten. Suturing the wound is unfortunately often impossible, as the skin, particularly if several attacks of dacryocystitis have preceded the operation, is easily torn. By packing the wound loosely, the rapid development of granulations is favored, and the cavity will soon fill up. Even after such an operation the scar may be remarkably insignificant. It is not uncommon for the repeated mistreatment of the tissues to result in an ectropion through shrinking of the scar. Success in elevating the lid and retaining it permanently in its proper position may be achieved by sutures going obliquely through the wound-edges from without inward and from below upward.

Dilated Sac.—If there is great dilatation of the lachrymal sac, which acts like a tumor and pushes the skin forward, the operation cannot be performed by the rules laid down. The tissues covering the sac may be so atrophic that immediately after cutting through the skin the wall of the sac may be exposed. In other respects, however, the removal of the sac does not differ in the slightest from that of other tumors in this region.

Tuberculosis of the Sac.—Tuberculous infiltration, which is seen especially in children, results frequently in destruction of the wall of the sac and necrosis of the bone, so that a radical operation is difficult. The diseased tissue must then be cut away, the necrosed bone removed, and the wound packed with iodoform gauze and permitted to heal by granulation. Recurrence is common in this type of disease, and is usually accompanied by formation of fistulæ, which then make secondary operations necessary.

Accidents and Complications of Excision.—The proper excision of the lachrymal sac is one of the most difficult of operations, and many of the accidents that arise are due to faulty technic.

Locating the Sac.—The beginner experiences considerable difficulty in finding the sac, except in cases in which it has become so dis-

tended as to be visible as a tumor through the skin. Error is often made in severing the fibers of the orbicularis muscle. The speculum broadens the wound, and the surgeon must first be clear as to the location of the crest. This usually lies close to the lateral branch of the speculum. If the muscle is severed too far nasally, the surgeon will strike the periosteum to the inner side of the crest, where he will look in vain for the sac. The anterior lachrymal crest must serve as a landmark throughout the operation; and the operator should always keep *as close as possible to the bone.* He will then not be misled into looking for the sac too near the nose in the periosteum of the bone, and also avoid penetrating the orbital tissue with *which he should never even come in contact.*

Opening into the Orbit.—If the surgeon loses his bearings and dissects toward the orbit, the connective-tissue septum is usually injured and considerable disturbance is produced by the entrance of orbital fat into the wound. The fat prevents a good view of the operative field, retards the operation considerably by the hemorrhage following its excision, and may lead to infection of the orbit and orbital abscess. Infection, however, does not necessarily follow, and the chief disadvantage is delay in the operation by the protrusion of the fat and the hemorrhage. The beginner enters the orbit not from injury to the fascia but because he fails to work toward the crest.

Injury to the Sac.—Should the sac be injured, the accident is of no importance provided the operator remedies the mistake at once and returns to dissect at the proper point. It may happen that during the opening of the deep fascia (especially if done quickly) not only the fascia but also the anterior wall of the sac, which lies immediately beneath it, are slit open. If the operator is not aware of the accident, he may dissect off only the lateral half of the wall, thinking that he has the entire sac before him. If he is sufficiently careful, however, and notes the injury, he can retrace his steps and without much difficulty find the right spot for continuance of the dissection on the outer side of the sac wall. The cleaner the dissection of the sac, *i.e.*, the closer to the wall of the sac the operator keeps by constantly dissecting between it and the covering fascia, the more satisfactory will be the course of the operation. It is remarkable with what perfect freedom from hemorrhage and pain the operation may be performed. The operator who lacks sufficient knowledge concerning the exact position and surroundings of the sac, and resects it together with all the attached tissues so

as to be certain to have the sac in the excised portion, will be greatly annoyed by hemorrhage, and his patient will suffer much pain.

Retained Portions of the Sac.—If small particles of the mucous membrane are allowed to remain, there is a continuation of the discharge, and, still more unpleasant for the patient, the formation of a fistula. Experienced operators may fail in extirpating the entire sac, and to obtain a perfect cure must resort to future operations. The failure to remove every particle of the sac may be due to an exceptionally profuse hemorrhage preventing accurate dissection, tearing of the sac during operation, or, finally, partial destruction of the anterior wall of the sac from rupture of the abscess into the surrounding tissue without having gone so far as perforation of the skin. The beginner finds greater difficulty in the resection of the lateral than of the median wall, because the bony landmarks are less prominent. It is also quite a common error to sever the sac some distance below the apex, and to leave the apex behind. It must be remembered that the apex is closely adherent to the fascia covering it and should, therefore, be removed with the sharp edge of the scissors. Cureting blindly with a sharp spoon is a crude procedure, and entirely without value. Inspection of the wound is important to determine that the bony walls are healthy and that no part of the sac has been retained.

Hemorrhage.—Should profuse hemorrhage occur before every portion of the sac has been excised, the speculum must be removed and the wound well packed with tannin-iodoform gauze until all bleeding has been checked. The wound is then held widely open with the speculum, and a careful examination made. In most instances the retained segments of the wall are seen, and may be separated from the underlying fascia and bone. It is only by removing all the mucous tissue that a cure and healing by first intention can be expected.

Suppuration.—Unless every particle of the sac is removed primary union of the wound will not take place. The secretion from retained portions of the mucous membrane soon distends the wound, and the sutures cut out or must be removed to allow escape of the fluid, otherwise persistent suppuration will be the inevitable result. In the event of suppuration the wound must be loosely packed with iodoform-gauze and washed with weak bichlorid solution or a 6 per cent. solution of hydrogen peroxid. Immediate curetment of the operated area is an error, because the granulations in the wound mask the tissues, and the mucous membrane of the lateral wall, not having the support of bone,

always escapes the sharp instrument. Cure will follow only after careful dissection of the entire lateral wall and apex of the sac.

Results of Operation.—The final results of excision of the lachrymal sac are eminently satisfactory. In a short time the scar is hardly visible, the conjunctival catarrh constantly associated with the blennorrhea soon disappears, and also the epiphora, the latter probably through a nervous influence. Should the catarrh and epiphora persist, a careful examination should be made of the canaliculi, and if any mucopurulent discharge can be squeezed from them, some of the mucous membrane has surely been left behind. If excessive lachrymation continues for several months the palpebral lachrymal gland must be resected.

CHAPTER II.

THE LACHRYMAL APPARATUS (continued).

EXCISION OF THE PALPEBRAL LACHRYMAL GLAND.

The palpebral portion of the lachrymal gland is the lobule of gland-substance which surrounds the excretory ducts of the orbital lachrymal gland at the point where they pass toward and through the superior conjunctival fornix. Toward the nasal side the excretory ducts do not extend beyond the temporal quarter. The lowest excretory duct lies at a level of the ligamentum canthi externum, or a little beneath it. This so-called inferior lachrymal gland may be seen at the outer part of the lid in many individuals by lifting or everting the upper lid, while the patient is looking downward and inward; sometimes it bulges forward in the form of a small lobulated tumor.

Indications for Excision of the Palpebral Lachrymal Gland.—The operation is required (1) in the occasional cases in which the lachrymation does not spontaneously disappear after excision of the sac; (2) in patients who come from a long distance for removal of the sac, and who would find it difficult to make a second journey; and (3) when the chief symptom of the disease of the sac is a constant epiphora. There is no objection to excision of the palpebral lachrymal gland immediately following extirpation of the sac, and this course should always be followed when constant lachrymation is associated with lachrymal duct stenosis.

De Wecker's Method.—The gland is conveniently reached by everting the lid with the finger in the usual manner, and inserting an opened lock-forceps at the junction of the outer and middle thirds, so that one blade is pushed beneath the lid into the conjunctival fornix and the other lies anteriorly on the tarsus. The lock is closed and the lid everted the second time by turning the forceps upward.

If the conjunctival sac has been well cocainized at the outset, the lid may be everted without pain. Before the incision is made, one-third c.c. of a 1 per cent. solution of cocain should be injected under the conjunctiva into the tissues between the point of the forceps and

the external canthus. The gland should be resected in one piece, and not in fragments.

Conjunctival Incision.—The incision through the conjunctiva is made with a small pair of curved scissors, and extends horizontally from the point of the forceps toward the external canthus for a distance of about 1 cm. The lobules, which may be numerous and well developed, at other times few and small, protrude through the wound as soon as the connective-tissue membrane which encapsulates the lachrymal gland is opened. (The cocain-injection may obscure the outlines of the structures at this time.)

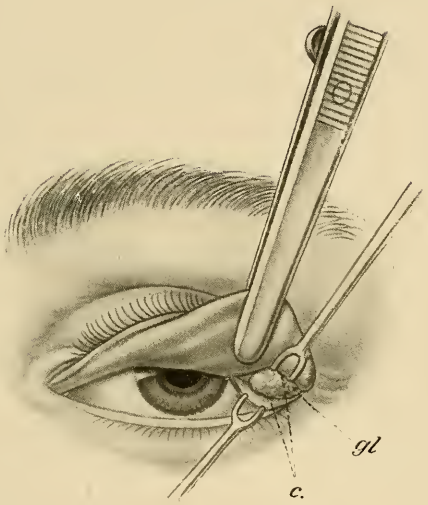

FIG. 12.—Extirpation of the lachrymal gland. The upper lid is turned upward twice—*i.e.*, upon itself—and is maintained in this position by a lock pincette held by an assistant at the outer third of the lid. The conjunctiva (c.) is freed on both sides of the gland. The wound is held open with double tenacula. In it is seen lying perfectly free the lower lachrymal gland (gl.), appearing as a small nodule.

The Conjunctiva is carefully dissected loose both in an upward and downward direction toward the tarsus and the ocular conjunctiva. The assistant retracts both portions of the conjunctiva with a double tenaculum. The lachrymal gland, which appears as a small node in the center of the wound (Fig. 12), is grasped with forceps and separated from the orbital lachrymal gland with scissors, beginning at the nasal end. It is not necessary to dissect high up into the orbit, but it is important that the lobules are shelled out for their *entire length*, as only then can all the excretory ducts of the large gland be cut through.

The amount of glandular substance removed is of no significance. The white membrane laid bare in the floor of the wound is the tarso-orbital fascia. It lies in front of the gland and does not interfere with its extirpation. It must not be injured, as unpleasant consequences will follow on account of its connection with the tendon of the levator palpebræ and hence the possibility of resultant ptosis. Fastening of the forceps at the outer third of the lid will prevent injury even if the dissection is carried too deep and the fascia cut. An injury to the outer skin or the external rectus muscle can be produced only by reckless cutting; this is clearly apparent if the position of the gland is considered. The hemorrhage during the operation is slight, although usually disturbing, and the assistant is kept busy sponging. One catgut suture, bringing the wound together from above downward, suffices, and the dressing may be removed after twenty-four hours.

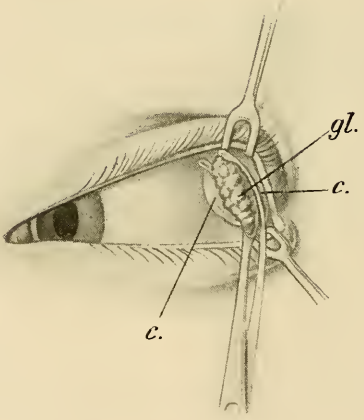

FIG. 13.—Axenfeld method of gland extirpation. c., conjunctiva; gl., gland.

Axenfeld Method.—Instead of doubly everting the lid, this operator employs two blunt double hooks, one inserted directly below the external canthus into the border of the lower lid, and one about half a centimeter from the canthus in the margin of the upper lid (Fig. 13). The hooks are separated upward and slightly backward, and the summit of the palpebral lachrymal gland is exposed and pushed forward. The usual incision in the conjunctiva and fascia is made, the gland seized and drawn forward with forceps, and the branches of the Axenfeld peans introduced as deep as possible along each side and closed. The

gland is excised with scissors close in front of the instrument. Sutures are not necessary.

This method of operation avoids the somewhat painful double eversion of the lid, makes a smooth exposure of the upper surface of the gland, relieves the tissues of abnormal tension, and escapes the folding which contributes to injury of the surrounding structures. No gland lobules or shreds of tissue should remain in the wound to cause conjunctival irritation.

Fricker's Method.—Fricker employs a thread to expose the gland. After the lid is everted, a medium-sized bent needle is passed through the tarsus, 2 to 3 mm. from its free border and somewhat near the center. The two ends of the thread are drawn upward and inward, which causes the palpebral gland to curve outward.

Results of Operation.—After excision of the gland the eye is usually ecchymotic for some days because the blood subsides to lower levels. Swelling of the upper lid produces slight ptosis, but this soon disappears. The final result is generally good, even though occasionally lachrymation is but little diminished. In one such case, even though the operation was performed according to every rule mentioned, weeping persisted to such a degree that it became necessary to remove the entire orbital lachrymal gland. This operation is performed through an incision from the skin.

Dryness of the conjunctiva or the cornea need not be feared either after extirpation of the inferior or the entire lachrymal gland, as the glands of the normal conjunctiva provide sufficient secretion. However, after extirpation of the lachrymal gland, an obstinate and long-lasting catarrh of the conjunctiva associated with thick mucoid discharge is occasionally seen.

LACHRYMAL PROBING.

Indications.—Constant epiphora indicates probable stenosis of the naso-lachrymal duct, and probing will be required until the lachrymation ceases or the duct is large enough to permit a No. 5 probe to be readily passed. If the epiphora is associated with a decided blennorrhea, stenosis exists in nearly all cases. Conservative measures (passing of probes and lavage) are only employed in those cases of blennorrhea which are not yet too far advanced. If the walls of the sac are already markedly thickened, or the sac dilated or perforated after acute inflammation, conservative treatment is of uncertain value. The

blennorrhea itself is treated with a $\frac{1}{4}$ per cent. silver solution, in preference to all other agents.

Diagnosis of Stenosis.—Stenosis of the duct is determined by cocainizing the conjunctiva, dilating the canaliculus, and inserting the canula of the lachrymal syringe into the sac. If the naso-lachrymal duct is passable, very little pressure will carry the fluid through into the nose of the patient, as he holds his head forward. If the passage is narrow, the fluid will not flow through for a short time, and then only in small quantities, while the greater part escapes through the superior lachrymal canaliculus. The latter occurs if the lachrymal sac and the naso-lachrymal duct are completely occluded. Only moderate pressure is to be used or the fluid will be forced into the surrounding tissues. After once making certain that the passage is narrow or completely occluded, the probes should be employed beginning with No. 2. If

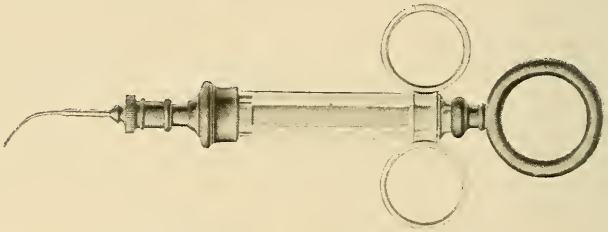

Fig. 14.—Anel's syringe. One-half size.

cocain cannot be injected before passing even the small probe, the attempt will be rather painful; at the second attempt, however, one can usually force a few drops of a 3 per cent. solution through.

Chronic epiphora does not, however, always mean stenosis of the naso-lachrymal duct, nor does this condition always rest on a mechanical basis. It may be a reflex symptom of diseases of the conjunctiva, the lachrymal passages, the nose, etc.; or may depend upon central disturbances.

If a marked blennorrhea of the sac exists, the examination, as before, is preceded by testing the permeability of the lachrymal passages. In nearly all the cases a stenosis will be found, and the treatment as above described must be instituted.

Anesthesia.—Before probes are inserted the naso-lachrymal duct is made anesthetic with an injection of a 3 per cent. solution of cocain. The best instrument for this purpose is Anel's syringe (Fig. 14). The most suitable model has a ring at each side; the second and third

fingers are placed in these, while the thumb presses the piston down. The syringe-point is placed upright into the lachrymal canaliculus, is then changed to a horizontal direction and pushed into the lachrymal sac just as if it were a probe. In this position the fluid flows in with the slightest pressure. If there is a stenosis of the naso-lachrymal duct, a small amount of fluid will slowly run from the nose as the patient bends the head forward. If considerable resistance is felt, the fluid should not be forced out of the syringe under too great pressure, as it will either escape through the superior lachrymal canaliculus or it will be forced

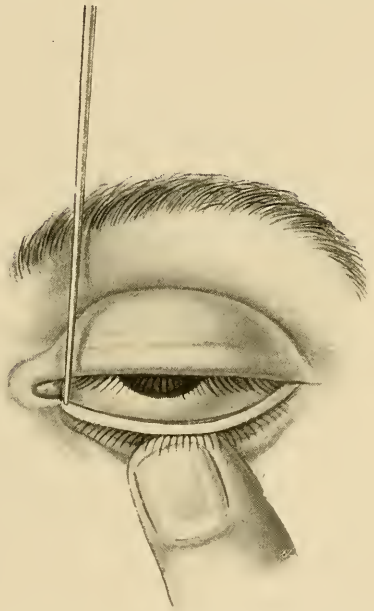

FIG. 15.—Introduction of the conical probe into the lower lachrymal canaliculus. The lid is pulled outward with one finger, and the lachrymal punctum thus turned slightly forward. The probe is inserted vertically.

into the surrounding tissues from the lachrymal sac, setting up swelling of the lids which persists for several days, and for which the patient usually blames the physician. The douching of the lachrymal sac should never be performed with the *patient lying down*, especially if the fluid is a cocain or bichlorid solution, as, should the naso-lachrymal duct be open, the fluid will flow into the pharynx.

Dilatation of the Canaliculus.—Before attempting to pass a Bowman's probe, the *lachrymal canaliculus* must be dilated with a conical probe. Before using the probe the patient is asked to look

up and the lower lid is pulled outward and slightly away from the bulb, thus making the lid tense. The lower lachrymal canaliculus at first passes for a short distance downward, the upper a short distance upward, and each then describe an almost right angle to empty into the lachrymal sac. To dilate the left canaliculus, the physician, sitting in front of his patient, employs his right hand. For the right canaliculus the left hand is used, or the surgeon may stand behind the patient to dilate the latter, and work with the right hand.

After the point of the vertically applied conical probe (Fig. 15) has entered the first portion of the canaliculus, the probe is depressed into a horizontal position and then pushed slowly forward, employing a slight twisting movement until the bone is reached (Fig. 16). If no

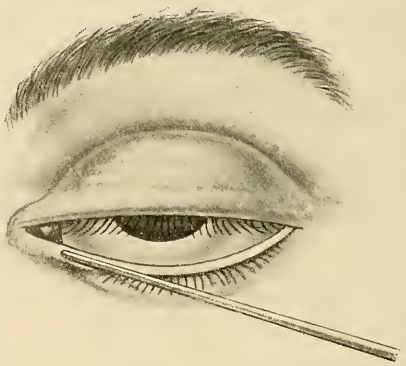

FIG. 16.—Second step in the dilatation of the lachrymal canaliculus with the conical probe. The probe is placed in the direction of the canaliculus, and is pushed forward with short twisting movements to the median wall of the sac.

retraction of the skin follows lightly drawing the probe backward and forward, it is known that its point has passed through the canaliculus into the lachrymal sac and has come in contact with its median wall. The operator must use no *force* in dilating the lachrymal canaliculus, as the point of the probe penetrates the wall easily, and a false passage not only makes proper probing difficult, but opens up a channel for fluids injected for anesthesia or cleansing to diffuse through the subcutaneous tissues, producing marked swelling of the structures in the neighborhood of the sac and lids. The conical probe enlarges the mouth of the lachrymal canaliculus so that there is usually no difficulty in passing a No. 5 probe.

Slitting the Canaliculus.—The slitting of the lachrymal canaliculus for the purpose of passing these probes is not necessary, and, therefore,

not to be recommended. The canaliculus is a good guide for Bowman's probe and with its aid the sac is always easily entered. When the canaliculus has been slit open, it may become difficult to find the beginning of the portion which has been left intact and which forms the point of entrance to the lachrymal sac. Bitter experience has shown how fruitless such efforts may be, as occasionally the probe

Fig. 17.—Weber's knife.

cannot be passed at all, the aperture after the slitting contracting secondarily through the formation of delicate scar-tissue around it.

The canaliculus should be slit only if through eversion of the inferior lachrymal punctum the course of the tears has been diverted and they trickle down the cheek, or if an ectropion of the lower lid has

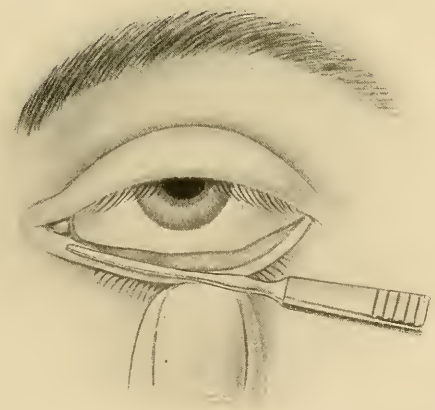

Fig. 18.—Weber's knife introduced in the lower canaliculus. Cutting edge looks upward and slightly backward.

begun to develop. Slitting the lower canaliculus converts it into a channel which communicates freely with the conjunctival sac; the tears are thus guided into their normal path and one of the main causes of ectropion is removed. This operation is performed with a Weber's knife, which has a delicate probe point, shaped like an olive, that rests upon the short neck near the blade (Fig. 17). The knife is

inserted into the dilated canaliculus and pushed in until the probe point touches the bone. The cutting edge of the knife is directed upward and *slightly backward* (Fig. 18). The finger pulls the lid outward, making it tense, and the knife, the probe point of which remains against the bone, is turned up, thus cutting the lateral part of the canaliculus (Fig. 19). The hemorrhage is slight. To prevent healing, the wound-edges must be separated occasionally during the next few days with the conical probe until the epithelium has grown over them.

Probing the Duct.—For this purposes we use Bowman's probes, Nos. 1 to 6. The point of the probe is placed vertically into the dilated lachrymal canaliculus, and, after it has passed the lachrymal punc-

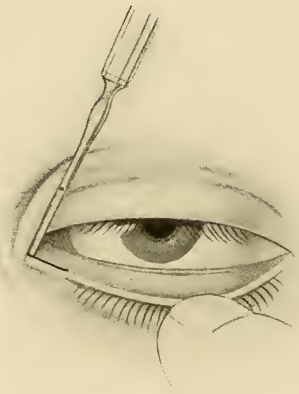

FIG. 19.—Weber's knife turned up.

tum, its direction is changed to the horizontal, the skin of the lid being drawn outward at the same time. When the tip of the probe strikes the bone, the lid is released and the instrument raised to the vertical position.

Unless the probe is kept in contact with the bone while it is raised from the horizontal to the vertical position, the duct will not be entered and a false passage will be made. The common error is to draw the point away from the bone as the probe is carried upward. Strong pressure should not be made, however, otherwise the probe point may penetrate the lachrymal bone. If an attempt is made to push the probe down before it has reached the vertical position, the oblique angle may lead to perforation of the inner wall of the sac or duct, and possibly also the bone. If the probe is in the correct position, a slight

push downward causes it to glide into the duct provided there are no adhesions. Stenosis and adhesions will be indicated by resistance, but if the probe is positively in the duct slight force may be employed to push it through. An indication that the probe is in the upper part of the duct is shown by its remaining standing when the hand is taken away. If the probe has been inserted properly, its plate will be on a level with the eyebrows (Fig. 20) and it will have retained the slightly curved shape and position into which it has been brought. If the probe has entered a false passage, it can be recognized by its unusual position. Ordinarily the rough ends of the perforation in the bone, through which the probe has been pushed, may be felt.

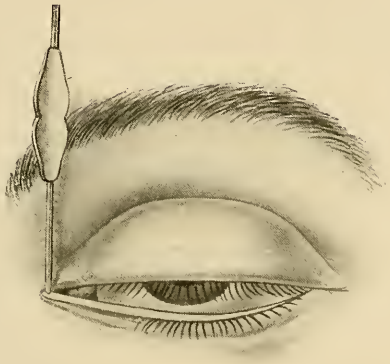

FIG. 20.—Bowman's probe is passed through the naso-lachrymal duct. The small plate of the probe is on a level with the eyebrow.

The probing is begun with No. 1, and is repeated every second or third day, the size of the probe being gradually increased until No. 5 is reached. It is well to remember that a thick probe may at times pass by a fold easier than a thinner instrument. The passage of the probe may be considerably facilitated by the addition of a small amount of adrenalin solution to the cocain. This contracts the blood-vessels in the wall of the duct, thus increasing its lumen and with it the space for the penetration of the instrument.

The instrument should be permitted to remain in the naso-lachrymal duct at least fifteen minutes each time. The probing must be continued until the fluid from Anel's syringe flows easily through the channel. If epiphora continues it may considered a proof that, in spite of the normal permeability of the lachrymal canaliculus, tear-

conduction and possibly even tear-secretion is disturbed. Tear-conduction, as is well known, is not dependent alone on the normal permeability of the nasal duct, but also, and perhaps to a greater degree, on the normal activity of the sac. In such cases it does not improve the symptoms to continue the ordinary probing or to employ the larger instruments.

Probing through the Superior Canaliculus.—It may be impossible to pass probes through the inferior lachrymal canaliculus in the manner described, owing to occlusion by scars following burns or injuries. The probes must then be passed through the superior canaliculus. Its course is analogous to that of the lower; first, vertically upward, followed by a curve toward the sac. After dilating with the conical probe, cocain is injected into the sac with Anel's syringe. Bowman's probe is inserted in the direction of the naso-lachrymal duct, *i.e.*, in vertical position.

Occlusion of the Duct in New-born Children.—The secretion of the sac is occasionally retained in the new-born, leading to considerable dilatation. This is the result of a congenital, but only epithelial, occlusion of the duct, and it is relieved in most instances by pressure over the course of the sac, with expression of the retained fluid, and the use of a mild alkaline and astringent wash. Should this treatment fail the passage of a small probe will effect a cure. The operation is not more difficult in the new-born than in the adult, but the distance between the lachrymal punctum and the nose is much less than in the adult, and therefore the probe does not penetrate so great a distance.

Hollow Probes.—To avoid the inconvenience of having to pass Anel's syringe into the canal after the probe has been taken out, the operator may employ hollow probes, to which Anel's syringe can be fastened while the probe lies in the naso-lachrymal duct. When such a probe is pulled out, the solution washes the duct most thoroughly.

A fistula in the tissues about the sac is an indication for the lavage of the sac. To determine whether the fistula is connected with the sac, a blue douche solution should be used. If a tumor exists in this region, it may be necessary to pass probes to determine whether or not the sac is free.

Contraindications to the Use of Probes.—Probes must not be passed in acute inflammatory conditions. If the lachrymal-sac disease is associated with disease of the bone (tuberculosis), the passage of

probes is contraindicated; in such cases extirpation of the diseased sac must be performed. As already mentioned, total stenosis of the naso-lachrymal duct is also an indication for extirpation of the sac.

Toti's Dacryocysto-Rhinostomia.—The operation is a substitute for excision of the sac, and is designed to secure a broad communication between the sac cavity and the nose by resection of the nasal wall of the sac and the surrounding bone and mucous membrane. This converts the sac into a part of the main nasal cavity. Its lateral wall, in which the mouth of the canaliculi is located, thus assumes the function of the large piece of the resected nasal mucous membrane. The operation is performed as follows:

The Skin Incision.—A cut is made through the skin, soft parts and periosteum above the inner canthus, 3 mm. in front of the lid attachment of the internal canthal ligament, and sweeps around in a half

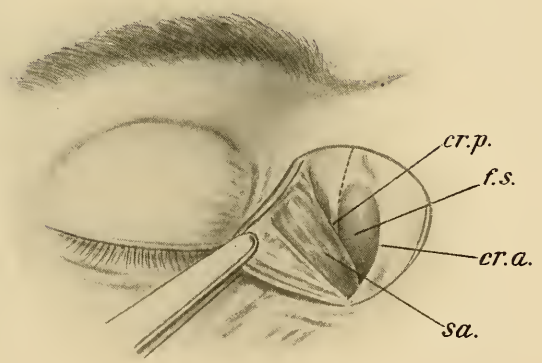

FIG. 21.—Toti's dacryocysto-rhinostomia. cr. a., crista lachrymalis anterior; cr. p., crista lachrymalis posterior; f. s., fossa sacci lachrymalis; sa., internal wall of the tear-sac.

circle and approaches the lower lid border. After cessation of the hemorrhage, the periosteum, with the attached soft parts which contain the entire lachrymal apparatus, is detached from the bone as far as the posterior lachrymal crest (Fig. 21).

Resection of the Bone.—The anterior border of the line of bony resection corresponds with the periosteum incision, the situation of which is 3 mm. in front of the attachment of the canthal ligament. From this point the anterior line of resection is upward and outward, and ends outward on the prolongation of the base of the posterior lachrymal

crest and below and outward on the outer border of the nasal duct. This anterior border line includes resection of not only the anterior lachrymal crest but also its posterior nasal continuation, the posterior border of the rising superior maxillary process. Toti places particular stress on the resection of this process. The posterior resection line lies a little in front of the posterior lachrymal crest, and vertically as far as the upper and lower end of the anterior resection line.

Resection of the Inner Wall of the Sac and the Piece of Nasal Mucous Membrane Exposed after Resection of the Bone.—The relation of the resected parts is shown in the illustration (Fig. 22).

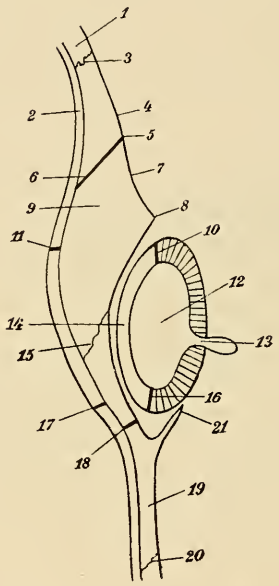

FIG. 22.—After Toti. 1. Section of nasal bone; 2, nasal mucous membrane; 3, bone suture between nasal bone and superior maxilla (frontal process); 4, outer surface of the frontal process; 5–6, resection line of the superior maxillar frontal process; 7, insertion of the lig. canth. int.; 8, anterior lachrymal crest; 9, central portion of the piece of bone to be resected; 10, anterior outline of the posterior sac-wall to be resected; 11, anterior outline of the nasal mucous membrane to be resected; 12, sac-cavity; 13, anterior sac-wall with common orifice of the canaliculi; 14, posterior sac-wall; 15, bone suture between superior maxillar frontal process and lachrymal bone at the base of the lachrymal fossa; 16, posterior outline of the sac-wall resection; 17, posterior outline of the nasal mucous membrane to be resected; 18, resection line of the lachrymal bone at the base of the crista lachrym. post.; 19, bone suture between lachrymal bone and os planum; 20, section of the os planum; 21, crista lachrymalis posterior.

Suture of the Wound.—The incision in the skin is closed by fine silk sutures, and a sterile gauze dressing held in place by a bandage.

Previous resection of a part or the whole middle turbinated bone,

with possibly some of the ethmoid cells, is usually required, otherwise an obstruction is offered to free drainage. The remnant of the sac containing the canaliculi must enter freely into the main nasal cavity. Unless the entire inner wall of the sac is resected the wound-edges will unite from the smallness of the opening.

Results of Operation.—The ideal result of the operation is not achieved if the canaliculi have been slit.

Chronic and progressive affections of the nasal mucous membrane are a contraindication to the operation, as the gap in the mucous membrane may later close, or the nasal affection implicate the canaliculi and the conjunctival sac.

The pathogenic bacteria in the conjunctival sac disappear less rapidly after the Toti operation than following extirpation of the sac, so that the latter procedure should be preferred when an intraocular operation is to be performed.

Complete restoration of normal lachrymal drainage follows in about half of the operated cases. In others no secretion appears by pressure over the remains of the sac, although the epiphora continues. Occasionally the mucous membrane gap closes, and the symptoms of purulent sac disease return. A certain proportion of failures may arise from fault in operative technic.

CHAPTER III.

ECTROPION.

Eversion of either lid, more frequently the lower, is: (1) Spasmodic or acute, and is commonly seen in children with scrofulous inflammation of the conjunctiva; (2) senile, the result of relaxation or loss of tone of the orbicularis muscle; and (3) chronic or cicatricial, which follows lacerations of the lid, burns of the face and lids, or caries of the orbital margin or body of the malar bone.

SPASMODIC ECTROPION.

Snellen Suture.—Two threads, double-armed with long, flat, strong needles, are required. One needle is inserted through the con-

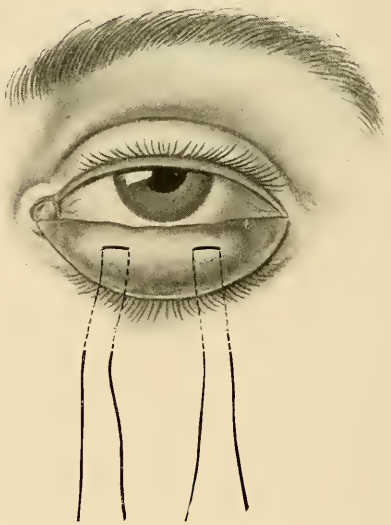

FIG. 23.—Snellen suture. Position of the sutures. A suture 3 mm. long overlying the conjunctiva corresponding to the most marked anterior curvature. Under the skin the sutures extend to the region of the lower orbital margin.

junctiva at the junction of the inner and middle third of the highest point of the ectropion, *i.e.*, usually at the lower (upper when the upper lid is everted) tarsal margin, and carried downward under the skin 2 cm., where it is brought out. The second needle is passed

in the same manner with the other end of the suture, 3 mm. distance from the first (Fig. 23). A loop is formed which overlies the palpebral conjunctiva at the most prominent part of the ectropion, while below the two ends of the suture hang free. The second thread is passed in the same manner at the junction of the middle and outer third of the ectropion. The two ends of each suture are now tied over a small pad of iodoform gauze and tightened so as to bring the lid back to its normal position. The loops exert their action on the highest point of the affected lid (Fig. 24), which is drawn down again to its proper position.

FIG. 24.—Vertical section through the everted lower lid with the sutures in position.

The same suture may be employed in the treatment of spasmodic ectropion of the upper lid, the threads being drawn through the skin slightly above the upper orbital margin.

The sutures are allowed to remain in position for at least three or four days, or until the edematous infiltration of the conjunctiva has disappeared, as the swelling tends to push the lid away from the eyeball. Since spasmodic ectropion is most commonly associated with catarrhal secretion, the eye should not be bandaged, but a strip of plaster applied over the knots.

SENILE ECTROPION.

In senile ectropion the lid border becomes relaxed, the tarsus and conjunctiva thickened, and the skin loose and incapable of supporting the lid. The Snellen suture is of no value, and operation must be directed to shortening the border of the lid.

The simplest method of operation, and one of the first devised, is excision of a triangular piece from the whole thickness of the lid. The results of this operation are not satisfactory. Either a coloboma or an unsightly indentation of the lid-margin follows from the contraction which the orbicularis muscle exerts on the two edges of the wound. The operation has, therefore, long since fallen into disuse.

Kuhnt endeavored to avoid this disadvantage by an incision along the intermarginal border of the lid, securing the necessary shortening by the excision of a triangular piece exclusively from the tarsus. The surplus fold of skin which remained as an ugly prominence, Müller attempted to remove by obliquely suturing it to the tarsus.

Szymanowski suggested that the lid-margin be shortened by the excision of a piece of skin from the region of the external canthus, and in this way attempt to draw the lid outward and at the same time elevate it somewhat. The relaxed skin, however, stretches after a time, and the ectropion recurs.

Kuhnt-Szymanowski Operation.—This is a combination of the tarsal and cutaneous operations, yields perfect results, and should be employed exclusively for the treatment of senile ectropion.

The Intermarginal Incision.—Splitting the lower lid in the intermarginal border is difficult in patients with senile ectropion, as the lid-

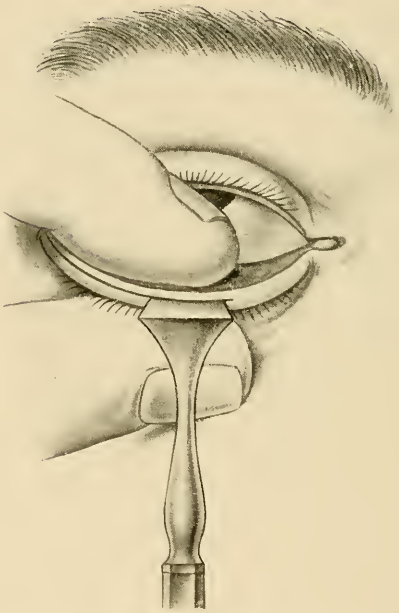

FIG. 25.—Kuhnt-Szymanowski operation. The lid is fixed between the thumb and index finger of the left hand. The lance is pressed forward, its flat surface parallel to the surface of the lid, in the intermarginal border, at first in the center of the lid. The incision is next continued outward to the external canthus, as the line indicates.

margin is usually indistinct, the posterior border rounded, and the conjunctiva thickened. The incision is made with the lancet, its point resting on the intermarginal border, while its plane lies parallel to the surface of the lid. This avoids perforation of the tarsus or wounding of the skin with the point of the lancet. A wound of the tarsus, in the region of the piece excised, has no particular significance, but if it lies to the side, the placing of the sutures in the tarsus may be made ex-

tremely difficult. The incision in the intermarginal border usually bleeds freely, and it is therefore advisable while making the cut to grasp the lid between the thumb on the skin side and the index finger on the conjunctival side (Fig. 25). This fixes the lid and permits the incision to be made without annoying hemorrhage. Satisfactory anesthesia and anemia of the whole field may be produced with the usual cocain and adrenalin mixture injected into the thickened substance of the tarsus. Occasionally the solution spurts out of the openings of the Meibomian glands.

The intermarginal incision is started slightly to the inner side of the middle of the lid and is extended to the external canthus. Precaution must be observed not to wound the skin, which may produce a coloboma of the lid or injure the roots of the eyelashes. The point of the lancet, held parallel to the lid-surface, enters the intermarginal border between the two layers of the lid, and sinks without much resistance between them. The lengthening of the incision to the external canthus by pushing the lancet forward laterally is not to be recommended, as there is always a risk of the blade leaving the intermarginal border and deviating forward, injuring the skin, or backward and penetrating the tarsus. It is decidedly safer, after an incision has been made corresponding in length to the breadth of the lancet, to insert the point of the lancet in another place on the intermarginal border and bury it in the tissue; and, when necessary, even to insert it in a third place. The several incisions may be readily united by cutting through the separating fibers. In this manner the lid is divided without injuring the anterior or posterior layers.

If it is desirable to make the intermarginal incision in one cut, a fine line must first be drawn with the point of the lancet and gradually deepened by making short cuts. It is almost impossible to draw this line if the intermarginal border cannot be distinctly seen, as is the case when the whole lid-margin is rounded by the ectropion. Therefore, we must be satisfied to keep behind the lashes near the posterior margin of the lid. The intermarginal incision is deepened until it has reached the lower margin of the tarsus.

Excision of the Tarsus.—The length of the triangular piece of the tarsus removed depends upon the degree of the ectropion. If too little is excised, the ectropion is not corrected; if too much, the two edges of the tarsal wound cannot be re-united by sutures. The operator should raise a fold of the tarsus with two pairs of forceps, and determine exactly

how much must be removed to allow the shortened lid to lie properly against the eyeball (Fig. 26). The forceps should be held in a vertical

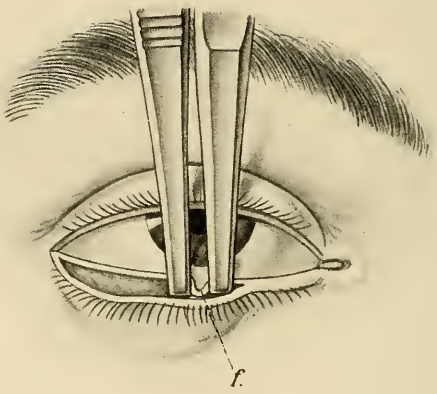

FIG. 26.—Kuhnt-Szymanowski operation. Two vertically-held forceps raise a fold (f.) of the tarsus, so that it projects prominently forward. In this manner we determine how much must be excised from the tarsus so that it can subsequently be properly attached to the bulbus.

position, near the eye, and the fold (*f*) allowed to protrude forward. The excised portion may be only 5 mm. or 10 mm. or more.

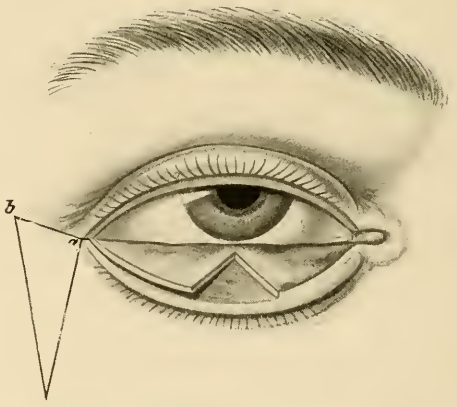

FIG. 27.—Kuhnt-Szymanowski operation. The measured part of the tarsus has been excised. The triangle is drawn in the region from which the skin is to be excised.

The piece of tarsus is taken exactly from the middle of the lid with a pair of short, straight scissors. A cut is first made from the inner corner through the tarsus, and the piece excised by cutting from

the other side obliquely downward from the edge of the lid for a corresponding distance. The excision includes only the tarsus and the overlying conjunctiva. The conjunctiva posterior to the tarsus must not be touched by the incision. The bleeding is usually insignificant, but, if severe, may readily be checked by two hemostatic forceps.

Excision of the Skin.—The excision of the triangular piece of skin is made from the region of the external canthus (Fig. 27). The first incision is made with a scalpel or lancet from the canthus outward and

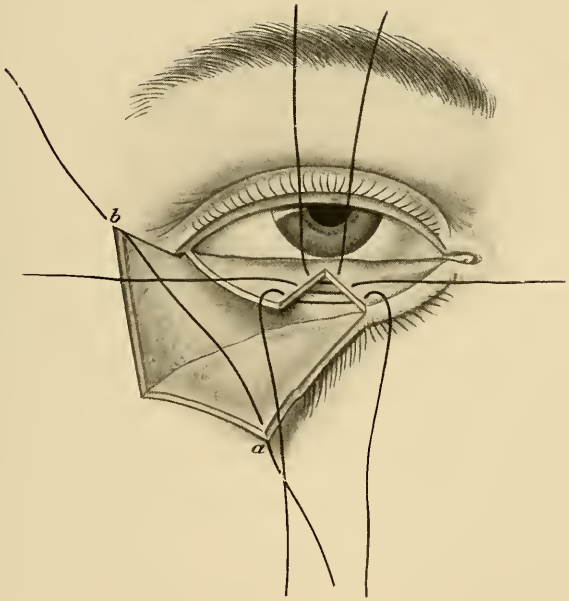

FIG. 28.—Kuhnt-Szymanowski operation. The triangular piece of skin is excised, and the skin of the lid undermined and turned outward. The three sutures through the tarsus lie in their proper position. The principal fixation suture of the flap (a. b.) is likewise drawn through. The cilia are excised from the corresponding part.

is carried a trifle upward to *b*. Its length equals, or exceeds somewhat, that of the piece excised from the tarsus.

The second incision starts from the canthus and is carried downward and a trifle outward. It is easily twice as long as the first, so that its lower point lies vertically below the outer end of the first incision. The ends of these two incisions are united by a third, and the piece of skin so isolated is excised. The skin of the lid is now completely

undermined so that it may readily be drawn outward to cover the defect produced.

The Tarsal Sutures.—The open wounds are now united. The triangular opening in the conjunctiva and tarsus is united by three fine silk sutures (Fig. 28). The fine, curved needle is inserted below, near the point of the triangle, pushed from the conjunctival side through the tarsus out to the wound, and carried on the opposite edge from the wound side through tarsus and conjunctiva. The needle must not be passed too close to the edge of the wound, because the tarsus, as has already been mentioned, is easily torn, and, if the sutures have once cut through, a second fixation is difficult. Both ends of this suture are turned upward. The second suture is inserted through the middle of the tarsus, and both ends should be placed horizontally. Special care is taken to properly place the last suture, to insure exact union of the wound and re-establish the margin of the lid, by passing the needles through the tarsus close to the edge. The threads are turned downward.

The pair of sutures turned upward are tied first. Nothing is more unpleasant for the operator than to be compelled to search for the threads belonging together by drawing one end to find its fellow; for this reason, detail description of the arrangement of the suture ends is dwelt on. As soon as the first suture is tied, and the edges of the wound in the tarsus approximated, the lid begins to roll inward. This movement is assisted by holding the threads upward in tying, thereby avoiding separation of the lid from the eyeball. After the three sutures are tied, the threads are cut off close to the knots.

On the cadaver the union of the two margins of the wound is more difficult than on the living, because the tarsus presents only as a thin membrane. In patients, the wound-surfaces lie in much better apposition in consequence of the thickened tarsus presenting a broad surface. Usually the help of an assistant is not necessary in bringing the margins of the wound together.

If the two portions of the lid-margin do not fit, the small superficial projecting wedge may be removed from the longer portion by scissors.

Closing the Skin Opening.—Before the skin of the lid is drawn over to close the triangular opening, a small strip of the skin of the lid margin which would lie beyond the external canthus is excised in order to remove the eyelashes. The first suture is inserted to the outer

angle of the defect (*b*), and the suture immediately tied. As in every skin-suture, accurate approximation of the edges of the wound is absolutely necessary. Next follows a suture (*e*) along the upper margin of the flap and the skin to the outer side of the upper lid. In addition two skin-sutures, (*c*) and (*d*) are inserted. A suture between the tarsus and the skin of the lid-margin must be made if not already in good apposition. A gaping fissure is occasionally found between the tarsus and the center of the lid-margin, so that primary union is not possible. This may be corrected by a suture, double-armed, the two needles passing from the conjunctival side out, at a distance of 1 mm

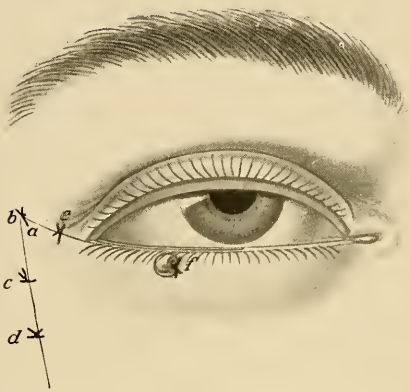

FIG. 29.—Kuhnt-Szymanowski operation. Appearance after the operation. The lower lid lies in its proper position; 4 (ab., c., d., e.) sutures suffice for the fixation of the flap. One suture for the fixation of the skin to the tarsus is tied over a bead (f.).

from the margin of the lid and 2 mm. from each other, through the tarsus and forward through the skin and tied over a small pad of gauze or a bead (Fig. 29). An ordinary suture would produce an unsightly indentation on the margin of the lid.

After the operation is completed the shortened lower lid lies closely against the eyeball and is at the same time slightly elevated.

Dressing.—A small amount of iodoform ointment is placed in the conjunctival sac, and a light pressure bandage applied to keep the flap firmly in contact with the underlying structures. Both eyes should be bandaged for four days. This ensures immobility of the orbicularis muscle, allows the cornea to rotate upward and lie behind the upper lid, avoiding the danger of ulceration from friction of the knots, and aids in prompt healing of the wounds.

The bandage should be carefully lifted on the day following the operation to see the condition of the cornea. After four days the sutures may be removed from the tarsus, and a day later from the skin. Should one or more of the sutures in the tarsal wound tear out prematurely, the tear must be allowed to heal by granulation. Beyond delay in the course of healing, this occurrence has no significance.

After-treatment and Results.—The result of the operation is always brilliant if the excised piece has been of a sufficient size. The resultant scar is scarcely visible. The existence of a corneal ulcer does not contraindicate the operation; on the contrary, it can readily be seen how healing of such an ulcer might be effected without any further treatment than replacing the protecting lid into its proper position.

On account of the softness of the tissues, the suture in the tarsus may cut through at once, especially if the excised portion has been too large and the structures are markedly stretched. For this reason the needle must not be passed too close to the margin of the wound, but far enough away to allow the suture to have proper support.

The greatest advantage of this operation is that if the sutures in the tarsus should cut through there is no danger of a coloboma, as the skin, which forms the plate of the lid, remains uninjured. Care must be taken, therefore, not to injure the skin in making the intermarginal incision. As the skin itself is frequently highly friable and atrophic, the skin-suture may also cause trouble.

In excising the triangular skin-flap, the upper incision must not be carried directly upward, as Szymanowski has advised, but only slightly inclined upward. Otherwise, the skin of the lower lid will be drawn too far over the tarsus, and the union made much more difficult. If the pressure-dressing is properly applied, no secretion is retained beneath the flap to cause rupture of the skin-sutures and compel their removal. If the skin is stretched too far outward, it exercises so much tension in the region of the lower border of the tarsus that this pressure backward against the bulb causes the free margin of the lid to turn outward, and ectropion again arises. A Snellen suture is the only method to bring back the lid to its normal position.

In cases of bilateral ectropion the operation should be performed on both eyes at one sitting, because when the operation is confined to one eye both eyes must be bandaged, and thus time and annoyance are saved.

If the ectropion is not far advanced, the ordinary Kuhnt operation,

with possibly Müller's modification, is recommended. In such cases the intermarginal incision is made from the middle outward toward the canthus; the corresponding piece is excised from the tarsus; the tarsal sutures are made as above described; and the skin is attached to the tarsus by several sutures inserted obliquely, to avoid the formation of one large fold of skin. The several small folds of the superfluous skin later become entirely invisible.

PARALYTIC ECTROPION.

For correction of this deformity, resort must be had to the operation of tarsorrhaphy, which is described on page 69.

CICATRICIAL ECTROPION.

No uniform method for the relief of cicatricial ectropion exists, and a description of the operative procedures is incomparably more difficult than for the other forms of ectropion. In general, all operations require first the division of the cicatrix which is holding the lid in an abnormal position, then the fixing of the lid in its proper situation, and finally the closing of the area made by drawing away of the lid with sutures or skin-flaps.

Operation for the relief of ectropion following burns should not be attempted until cicatrization of the skin has been completed. When the ectropion is due to caries, with a discharging fistula, operation must be postponed until the diseased bone has been laid bare by an incision and cureted, and the sequestrum removed. To protect the cornea from the danger of subsequent ectropion, a tarsorrhaphy is made. In this operation, by fixation of the upper lid to the lower, the eversion of the upper lid is prevented. Then the diseased process is allowed to run its course, but the operation of dividing the scar and obliquely suturing the wound is not to be performed until healing is complete.

Ectropion from Caries.—The cicatrix which holds the lid in the abnormal position is divided by an incision made with a scalpel, parallel to and usually quite close to the margin of the lid, throughout the whole length and depth of the scar, so that the lid, entirely free and movable, can be brought back to its normal position. As the cicatrix often extends to the bone, after caries and deeply penetrating corrosions, the orbital margin, covered only with periosteum and cicatricial tissue, may be exposed.

The next step is to fix the lid in its proper position, and to cover the area caused by the drawing away of the lid. This is manifestly the most important part of the operation, as otherwise, during the healing of the wound, the new cicatrix would draw the lid back again to its former position. This may be prevented by undermining and directly approximating its margins, or, if extensive, by a plastic operation.

The Sutures.—The defect may be closed by sutures if the wound is relatively small and the surrounding skin in a normal condition; for instance, ectropion of the external portion of the upper lid produced by a small scar following caries, and the lid-margin appears to be fixed to the bony orbital margin. After thorough separation of the scar and reposition of the lid in its normal position, the approximately horizontal wound may be converted into a vertical one by sufficiently undermining the surrounding skin and making traction on the middle of the upper and lower edges of the incision with two blunt hooks. Then by horizontal sutures the incision may be drawn into a *vertical* line.

By approximation in a slanting direction, that is, vertical to the earlier direction of contraction of the scar, the upper lid is placed correspondingly deeper, and in slight cases actually remains permanently in its normal position. Such approximation is only possible when the scar is small and the incision a short one, and when the surrounding skin is in a normal state. This procedure is impracticable in cicatricial changes following corrosives or lupus, which have so affected the skin as to make it unyielding.

Flaps without Pedicle.—The cases are few in which suturing suffices for the repair. Usually, after separation of the cicatrix, the defect must be covered with a skin-flap. In opposition to many operators we believe that it is better to use, whenever possible, flaps without pedicles. As is well known, in the greater number of cases of cicatricial ectropion (corrosion, lupus), the contraction of the surrounding skin by the cicatrix prevents the use of pedunculated flaps. Here, particularly, we recommend delicate flaps without pedicles. Pedunculated flaps project from the surrounding skin as thick, irregular elevations and produce a marked disfigurement, whereas the extremely thin, non-pedunculated flaps apply themselves smoothly against the denuded tissue and after some time present the same folds as the healthy lid and are differentiated from their surroundings only

by their somewhat lighter color. The claim that non-pedunculated flaps constantly contract and destroy the results of the operation is not justified. We have formed new upper and lower lids by means of non-pedunculated flaps, and they are still, after some years, in a faultless position. Utilization of the surrounding skin was absolutely impossible in consequence of marked cicatricial contraction following corrosion with vitriol.

Ectropion from Extensive Burns.—The results to be obtained from the use of flaps depend upon the method of transplantation. A marked over-correction of the defect is the first essential. In severe cases the whole upper and lower lids are found turned outward to the region of the orbital margin, and the upper lid closely adherent to the eyebrow. Occasionally the margin of the lid is relatively well preserved.

The division of the scar and the releasing of the lid is similar to that described for ectropion due to caries. On the upper lid it is often difficult to keep within the narrow zone between the eyebrow and margin of the lid, so far up has the lid been drawn from its normal position. If no lid-margin is present, the incision is made, if possible, at a distance of 2 mm. from the margin of the conjunctiva. After the scar is completely divided or excised, the lid, which is now freely movable, is drawn well over the other lid—the upper down over the lower, or the lower up over the upper. Three strong sutures are now passed through the margin of the freed lid and are fastened, either on the cheek (if the upper lid) or on the forehead (if the lower lid); both suture-ends must be passed through the skin and tied over a small pad of iodoform gauze. Thus, the defect to be covered by a flap will considerably exceed in size the dimensions of the normal lid.

The hemorrhage may be checked either by compression or by temporary clamping with hemostatic forceps. The latter may be twisted off after a short time. Ligature with catgut is only necessary for the larger vessels. The bleeding from the small vessels in the scar soon ceases. The wound has an irregular, obtuse, triangular appearance, its surface showing as a depression below the orbital margin and toward the side of the nose. It is now temporarily covered with a tampon saturated with warm normal salt-solution.

Preparing the Skin-graft Flaps.—These are taken from the inner side of the upper arm. In order to form an idea of the size and shape of the flap to be excised, a piece of gutta-percha tissue, corresponding to the

wound in form and size, is laid on the part from which the skin is to be excised. After thorough disinfection, the skin of the arm is well stretched in an oblique direction by the assistant. As the skin retracts considerably after being loosened, the flaps must be made much broader and a trifle longer than the size of the gutta-percha pattern. The flap should not be wholly separated at once. An incision is first made on one side with lateral prolongations from each end for a short distance. The flap is now ready to be dissected with the lancet (keratome). Only the superficial epithelial layers should be removed in the form of a single flap, and the lancet serves better than any other knife for this purpose. If the blade is placed parallel and close to the skin, it is not difficult by a stroking motion to separate the superficial epithelial layers if done slowly and with great care.

After a small strip has been freed, it is rolled outward with a pledget, from which the salt-solution has been well squeezed out, so that the further dissection can be continued at the adhering point. The flap detached is so thin and superficial that bleeding only occurs from the apices of the cut papillæ. Care must be taken not to button-hole the skin, as the openings, although small at the outset, increase in size by retraction and are undesirable because their margins roll up and later make proper adaptation of the flap to the wound difficult.

Rapid and careless work in preparing the flap results in deep cuts, and the sections are thick and heavy and retract too much. When a section of the desired size has been prepared, it is separated from the point at which it is still attached to the skin, and is covered at once with two pledgets saturated with warm salt-solution. Before transferring the flap, the denuded surface of the wound should be stroked with the edge of the lancet in different directions, in order that a small amount of blood and serum may exude to ensure rapid adhesion of the flap to the wound.

Adaptation of the Flap to the Surface of the Wound.—The flap, which until now has been spread out on the pledget, is placed with its wound-surface on the defect. The middle of the flap is then pressed well against the raw surface by means of a pair of closed forceps, and the pressure continued until it conforms to the surface of the wound. Especial care is taken not to allow spaces to separate the various pits in the wound from the flap, more particularly at the inner angle. Then follows the exact adaptation of the margin of the flap to the margin of the wound. To properly spread out the flap, as its margins roll up in

every instance, the latter should be drawn out with Carlsbad needles,[1] and applied to the margin of the wound so that not even the slightest interstice remains between the two. If the flap is somewhat too large, and the margins project over the edges of the wound, it must be reduced to the proper length with a pair of scissors. This adaptation must, naturally, be made along the whole periphery of the flap. Sutures are not recommended.

Dressings.—After completing the adaptation, the flap and its surroundings are covered with an oiled gutta-percha paper, over which is loosely placed sufficient dry gauze to cause slight compression. The gauze is held in position by two broad strips of adhesive plaster. The other eye is also included in the bandaging, in order to prevent all movements of the lid. An outer starch-bandage makes the dressing stiff within a short time. The operation is performed under general anesthesia. The wound on the arm need not be sutured; the skin regenerates within a short time from the islands of epithelium remaining between the papillæ.

The dressing is changed for the first time on the second day after operation. It is encouraging, when the bandage is taken off, to find the flap in the desired position and already adherent. As no wound-surface exists, there is naturally not the slightest secretion. The flap is usually quite white, but occasionally the upper epithelial layers are somewhat darker in color. Simply because of this, no necrosis of the flap need be feared. Within a few days the delicate normal young skin makes its appearance beneath. Two days later, the bandage is again renewed. The fixation-sutures of the lid have by this time usually cut through, and are now removed. The lid remains at first in the abnormal position, but the flap has, by this time, healed sufficiently to prevent its being displaced during a change in the position of the lid. Gradually and slowly the lid returns to its normal situation. The final results in most cases are excellent. The skin is gradually thrown into folds as is the normal skin of the lid, and is differentiated from its surroundings only by its paler color.

A non-adhering flap is of a greenish-black color at the first change of dressings, and separated by profuse secretion from the granulations beneath. Nothing remains to be done in these cases but to wait until the cicatricial process is concluded; then the original condition returns, and the same operation may again be tried.

[1] A kind of long hat pin, the end of which has the form of a small lancet.

If, however, the first operation is completed without error in technic, this undesirable occurrence will be met with only exceptionally. Should an ectropion exist on both lids, the upper lid should be operated on first, and, some weeks later, the lower lid.

The plastic operation with pedicled flaps is described elsewhere (p. 75).

CHAPTER IV.

TRICHIASIS AND ENTROPION.

The turning inward of the cilia (trichiasis) and the inversion of the border of the eyelid (entropion) are often associated, and their surgical treatment is in many particulars similar.

TRICHIASIS.

The deformity may be partial, situated at either end of the lid and affecting a few lashes; or may be total, in which the disease extends along the entire length of the lid, although the cilia may be arranged in regular order.

Of the numerous operations employed for the relief of total trichiasis, several are worthy of consideration.

Hotz-Anagnostakis Operation.—This method gives the best cosmetic results, and is preferable in all cases following trachoma. After an ivory or hard-rubber plate has been placed beneath the lid to protect the eyeball and provide a firm base, and by compression assist in checking hemorrhage, an incision is made along the entire length of the lid, either with a scalpel or a lancet, 3 mm. above and parallel to the border. Lying exposed in the wound are the reddish fibers of the orbicularis muscle, parallel to the edge of the lid. After the skin has been freed downward for a short distance, and upward to the upper border of the tarsus, the fibers of the muscles are lifted up at one end of the lid with forceps (Fig. 30) and excised, in a breadth of about 4 mm., to the other end of the lid with one stroke of the scissors, applied flat. This frees the entire surface of the tarsus.

In most cases of trachoma, the tarsus is usually several millimeters thick, is firm in texture and curved convexly forward. The normal striations of the Meibomian glands are not shown in the tarsus of a trachomatous patient, as only some indistinct traces of the glands remain. It is best to excise, or rather to diminish, the thickness of this useless scar-tissue, which is the cause of the distortion of the lid. For this purpose a sharp scalpel is entered (Fig. 31) somewhat below the upper margin of the tarsus and parallel to its plane, and with a sawing

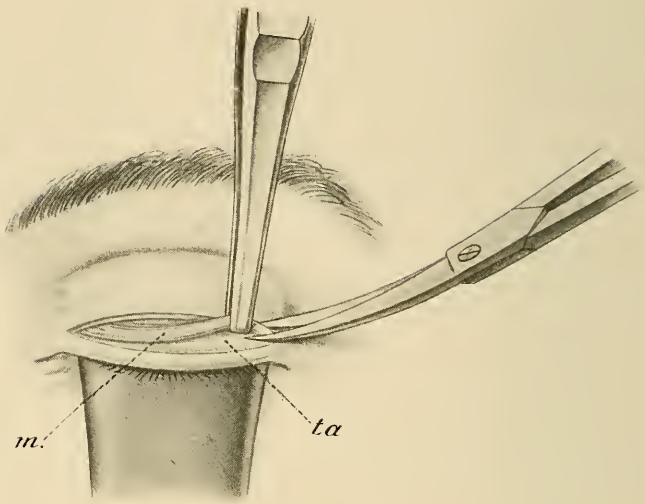

FIG. 30.—Hotz-Anagnostakis operation. Excision of the fibers of the orbicularis muscle (m.) covering the tarsus (ta.). With forceps the fibers are grasped at the left angle of the incision; a small pair of curved scissors is applied close to the tarsus, and with short cuts the muscle is separated along the entire length of the lid.

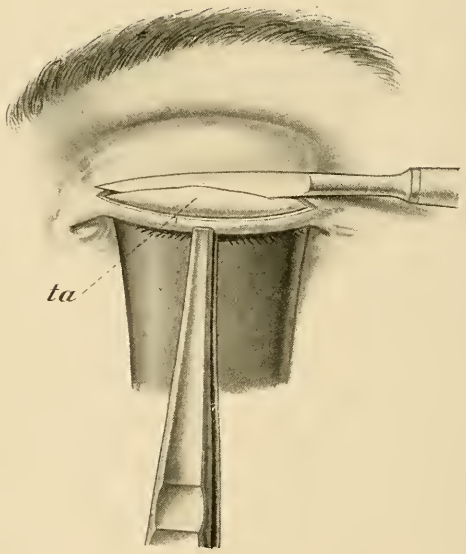

FIG. 31.—Hotz-Anagnostakis operation. With the knife applied flat against the convex anterior surface of the thickened tarsus (ta.), thin slices are cut. The upper border of the tarsus and the margin of the lid are not disturbed.

movement downward thin slices are cut away. In a normal tarsus, as found in the cadaver, this procedure cannot be demonstrated, as the fibrous structure is thin and would immediately perforate. In a trachomatous patient there is little danger of cutting through the thickened tarsus. Perforation, however, should be avoided. The uppermost part of the tarsus and the margin of the lid are not included in the area thinned.

Insertion of the Sutures.—The purpose of the sutures is to stretch

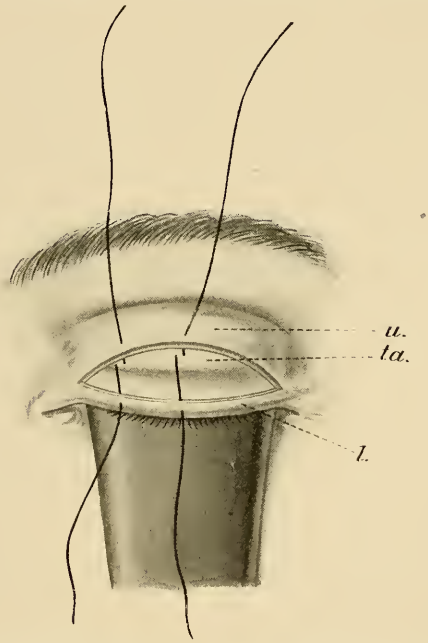

FIG. 32.—Hotz-Anagnostakis operation. Two of the sutures are applied. They pass from above through the skin (u.); then through the upper border of the tarsus (ta.), in which they are firmly fastened; and lastly through the lower margin of the skin (l.) above the cilia. Corresponding to the convex form of the upper tarsal border, the tarsal point of insertion of the outer and inner suture is nearer the lower margin of the wound than that of the middle suture.

and straighten the tarsus which has been bent backward by the disease. This is effected by fastening the lower margin of the skin-wound to the upper border of the tarsus. Because of the difference in the height of these two points, union is possible only if the lower border of the tarsus bends forward on itself and carries the cilia into the desired position. The sutures which include only the cutaneous wound-edges and the upper border of the tarsus are inserted as follows (Fig. 32):

The central suture is entered through the upper wound border at a point corresponding to the middle of the lid. The skin is then retracted by an assistant, and the needle passed through the upper border of the tarsus in a horizontal direction, which prevents perforation through the conjunctiva, an accident, however, of little consequence. The assistant releases the upper cutaneous wound, and the needle pierces the lower border of the skin-wound in a line corresponding to the upper point of entrance. One suture is inserted in exactly the same manner on either side of the first, making three in all. Frequently four or five sutures are employed. The central suture is tied first. The two margins of the skin-wound are approximated with two tissue-forceps in the hands of the assistant. As the suture is tightened, the tarsus with the free border of the lid bends forward and somewhat upward (Fig. 33). It is well to induce moderate over-correction at first, so that the margin of the lid is at a slight distance from the eyeball. The remaining sutures are tied with the same care, and the ends are cut off short.

FIG. 33.—The tarsus has been bent forward during the closing of the skin-wound. The eyelashes are directed forward and slightly upward.

Dressing.—A simple dressing is then applied and kept from adhering to the wound by gutta-percha tissue covered with ointment. The other eye need not be bandaged. The dressing, as in every other lid-operation, is changed on the following day. The sutures should be removed after four days.

Results.—If performed in the manner indicated the operation gives good results. As the edge of the lid is not injured, its normal outlines are preserved, which from a cosmetic standpoint is of great importance. The main advantages of the operation are that the pathologically heavy tarsus is rendered light by the excision, and the lid returns to its normal position without becoming shortened in the slightest. There are several disadvantages. The tarsus is crescentic in shape, broadest in the middle of the lid and tapering off somewhat toward both angles. Therefore, the effect of the operation is better in the middle of the lid than at the ends. As it is not necessary to turn up the ends far enough to attach the cutaneous wound-margin to the upper border of the tarsus, the trichiasis at the margin of the lid may not be completely overcome. The excision of a small piece of skin will, however, slightly shorten and raise the lid. At the same time a small incision may be made into the intermarginal border at a cor-

responding point, so that the sutures raise the cutaneous layer of the lid with its cilia away from the eyeball. The small wound produced in the intermarginal border is allowed to undergo cicatrization.

Beyond this provisional incision no cut is made into the intermarginal border; in fact, a primary intermarginal incision would prevent the stretching of the tarsus, for, as soon as the anterior cutaneous layer of the lid is separated from the tarsus by such an incision, the rolling forward of the lower tarsal border can no longer be accomplished by the suture. Correction of the position of the tarsus is not intended in the secondary provisional intermarginal incision, but rather a displacement of the layer of skin containing the hair-roots, similar to that in the Jaesche operation. This latter operation, unsupported by the Hotz method, would allow the thickened and heavy

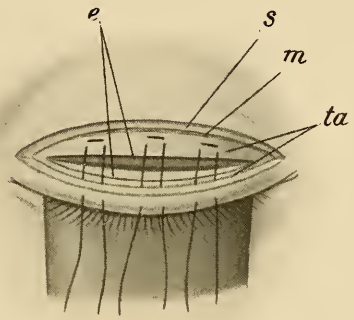

FIG. 34.—Snellen operation. A wedge-shaped piece (e.) of the tarsus is excised. Sutures in place. s., skin; m., muscle; ta., tarsus.

tarsus to retain its curvature toward the cornea, keeping up the irritation as before. Again, the wound produced in the intermarginal border must heal gradually by cicatrization, which would interfere with the best cosmetic results. The lower suture must not be carried through the intermarginal border, but kept above the eyelashes; otherwise, it will cut through the skin, injure the hair-bulbs, and possibly give rise to an ugly indentation in the edge of the lid.

The possibility of recurrence need not be feared if the tarsus has been treated as above described. The thinning of the tarsus is an essential advantage, resembling in this respect Snellen's method.

Snellen Operation.—The incision in the skin of the lid and the excision of the muscle fibers on the anterior surface of the tarsus are

the same as in the Hotz-Anagnostakis operation (Fig 30). The thickened tarsus is then incised horizontally across its entire length with a thin scalpel, two cuts being made 2 to 3 mm. apart, the lower one 2 mm. above the lid margin. The two incisions cut through the tarsus obliquely and meet near its posterior portion without injuring the conjunctiva or opening into the culdesac. The wedge-shaped section of the tarsus is then completely excised (Fig. 34). The two needles of the double-armed silk suture are passed through the upper edge of the tarsal opening near its center, and then entered at the lower cut and passed in the tarsus to emerge from the skin immediately above the cilia (Fig. 35). The two ends of the suture are knotted over a small glass bead, which causes the lid-margin to turn upward. The skin-wound is closed by several sutures.

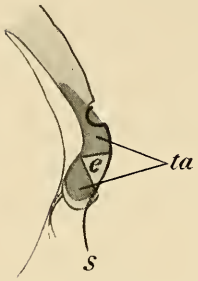

FIG. 35.—Snellen operation. Vertical section through the upper lid, showing the cuneus-shaped excision (e.) of the tarsus (ta.), with the suture (s.).

The broader the wedge of tarsus excised, the greater will be the eversion of the border of the lid. The operation is indicated in thickened lids with deformed tarsus, especially if the entire lid-margin is filled with hairs. The skin-sutures may be removed in three to four days.

Panas Operation.—This is a more radical and serious procedure. The eyeball is protected by an ivory plate, and an incision made through the skin of the upper lid, as in the Hotz operation, dividing the muscle bundle of the orbicularis, which need not be excised. The tarsus is freed as far as its upper margin. With a sharp scalpel a cut is made through the tarsus and conjunctiva immediately above and parallel to the margin of the lid along its entire length, converting the margin into a movable flap, connected with the surrounding tissues only at both lid-angles. The object of the operation is to fasten the exposed tarsus so that the eyelashes are directed forward. Four sutures are inserted, doubly armed with thin and strongly curved needles. The needle of one of the sutures is passed deeply into the tarsus at the upper margin of the wound close to the cut, and brought out horizontally close to its point of insertion. This fixes the suture firmly into the anterior portion of the tarsus, and both ends of the thread are passed between the muscle and tarsus of the free flap and brought out in the intermarginal border. The other sutures are introduced in a similar manner (Fig. 36).

Perforation of the thickened tarsus is easily avoided, but should it occur, is of little importance, as the suture is drawn into the conjunctiva without injuring the cornea.

The assistant now turns the edge of the lid forward with forceps, thus bringing it perpendicular to the plane of the tarsus, and the operator ties the central suture, drawing a glass bead over it (Fig. 37). He should be careful that the suture is not tied so tightly that the glass bead will press upon the edge of the lid, and lead to circumscribed necrosis and subsequent loss of eyelashes, but tight enough to allow firm attachment of the flap. The other sutures are treated in exactly

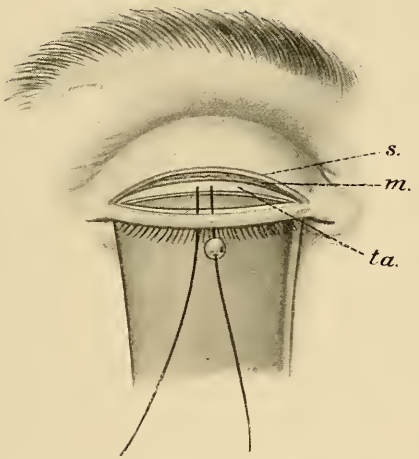

FIG. 36.—Panas operation. After cutting through the skin (s.) and muscle (m.), the tarsus (ta.) and conjunctiva are incised, over an ivory plate placed between lid and bulb, along the entire length of the lid. The central suture has already been introduced. Above it is fastened to the tarsus near the edge of the tarsal wound. Both ends of the suture pass downward between tarsus and muscle and emerge in the intermarginal border behind the cilia. Over one end of the suture a glass bead is drawn.

the same manner, and the ends of the threads cut off short. The cutaneous wound must then be closed with several sutures, and an ointment-dressing applied. The sutures may be removed as early as the fourth or fifth day.

Results.—If the sutures are not attached to the proper place in the tarsus, an unsightly disfigurement will result. If fastened at too high a point, the free edge of the lid is pulled up above the margin of the tarsal wound, and the tarsus projects free into the palpebral fissure. The wound-surface then heals by slow granulation, and terminates finally in the formation of a scar. As this rough cicatrix is directed

inward, owing to the pathological curve of the tarsus, irritation of the cornea follows. If the sutures have been properly inserted, the flap fits in accurately and without any disfigurement. The *possibility of recurrence is excluded by this method of operation.*

There are several disadvantages which must be considered. The base, from which the flap derives its nourishment, is small in proportion to the length of the flap, and is, therefore, in danger of necrosis. Should this unpleasant complication arise, the patient has not only been disfigured by the operation, but is probably even in worse condition than before, as now the upper lid is shorter by the necrosed piece, and a resultant lagophthalmos may be produced. Even if the operation is without complication, the upper lid has been shortened by the width of the flap, which has been turned out of the plane of the lid to one perpendicular to it. Short lids in patients seeking surgical aid must, therefore, be considered another contraindication to the operation.

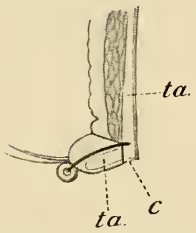

FIG. 37.—Sagittal section through the upper lid after completion of the operation. The margin of the lid, now placed vertically to the plane of the lid, is so adjusted to the tarsus (ta.) that no part of it projects into the palpebral fissure; in fact, only a small portion of the wound-surface (the cut edge (c.) of the tarsus) remains exposed.

The lower lid may be operated on after the methods of Hotz and Panas in exactly the same manner as the upper lid. Because of the small size of the tarsus, however, the Hotz operation is less favored.

Kuhnt Tarsal Enucleation.—This operation is of especial value in trichiasis of the lower lid which occurs in the cicatricial stage of trachoma, as the conjunctiva is then readily detached from the shrunken and deformed tarsus. At an earlier period the gelatinous infiltration prevents separation of the two tissues without fenestration of the conjunctiva. Both entropion and trichiasis are permanently relieved by removal of the tarsus, and healing of the trachoma is materially hastened.

After the lower lid had been everted with forceps, an incision, 1½ to 2 mm. from and parallel to the lid-margin, is made through the conjunctiva and tarsus from the lachrymal punctum to the outer commissure. The conjunctiva is separated by flat cuts of a knife from the tarsus, and the latter dissected from the underlying attachments as far as its inferior margin and removed. Double-armed sutures are now placed in the edge of the cut conjunctiva, each loop about 2 mm.

broad, and passed on the inner surface of the remaining margin of tarsus and brought out through the skin near the border of the lid. The threads are drawn taut until the cilia and lid-margin are in proper position, and fixed with adhesive to the skin. They may be removed in four or five days. The results of the operation are permanent.

Flarer Operation.—After the usual intermarginal incision, a cut is made in the skin 3 mm. back of the lid-border and parallel to it, the two ends of the incision turning to join the opening made in the margin of the lid. The flap formed, containing the cilia, is removed with scissors, and the wound-edges brought together with fine thread. As this excision sacrifices all the cilia, it is only indicated in severe affections of the lids in which only a few deformed lashes remain, and is then usually combined with the plastic mucous membrane operation.

Jaesche-Arlt Operation.—By this method the border of the intramarginal incision containing the hair bulbs is displaced upward by the excision of the crescent-shaped piece of skin from the upper lid. The wound is closed by vertical sutures. The excised piece of skin serves to cover the exposed anterior surface of the tarsus along the lid-margin. Like all skin-transplantations on the lid-margin, it sets up fresh irritation of the cornea because of the fine hairs always present in the skin.

Partial Trichiasis.—Special consideration must be made of cases in which the trichiasis is confined to one end of the lid only, and also of those in which the cilia are no longer in a regular row, but stand out from the lid-margin in various directions, occasionally projecting obliquely backward from the posterior edge of the lid.

Spencer Watson Operation.—This method is of value for partial trichiasis at either end of the lid near the canthus (Figs. 38 and 39). An intermarginal incision is made the length of the affected area, and a cut made in the skin of the lid, 2 mm. distant from and parallel with the margin. By turning downward the lid-margin, the cutaneous incision is made to terminate at the canthus and join the intermarginal incision. In this way the cilia are contained in a flap, the base of which lies on the side away from the canthus. A second skin incision, 2 mm. above and parallel to the first, is made, forming another flap, the base of which lies on the side of the canthus. The flaps are undermined and exchanged, the flap with the lashes moved above, while the upper is placed at the margin of the lid. The flaps are held

in the new positions by sutures passing through their angles, and within a few days permanent union takes place.

If this method were applied to trichiasis extending the whole length of the lid, the flaps would have too small bases as compared to their

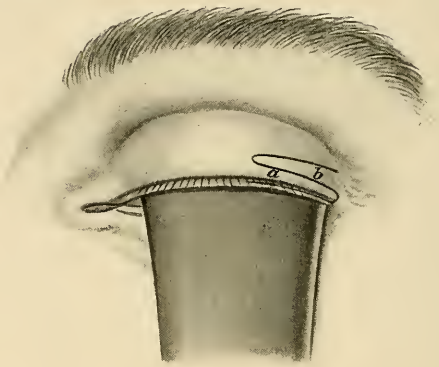

FIG. 38.—Spencer Watson operation. Position of the intermarginal and skin-incisions. a., base of the skin-flap containing the eyelashes. b , base of the upper skin-flap.

length, and in consequence would easily break down. Like all skin-transplantations, the operation has the drawback of inducing renewed symptoms of irritation from the fine hairs in the skin-flap. However, as the flaps lie to one side of the cornea, this is not an important disturbing factor.

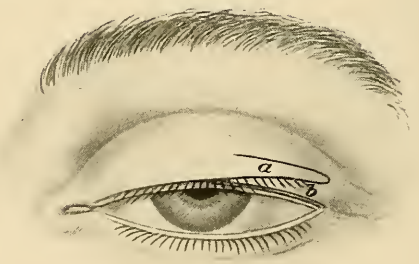

FIG. 39.—Spencer Watson operation. The flaps interchanged.

Mucous Membrane Flaps.—If there is irregularity in the arrangement of the cilia, a characteristic of severe types of trichiasis, with corneal complications, a plastic operation must be performed. An incision is made along the intermarginal border, and the skin, with the

cilia, is separated from the tarsus to about its upper border. As the skin is usually short, there is some retraction, and a few fine silk sutures are used to attach the edge to the tarsus a few millimeters above the margin of the lid. The wound-surface produced is covered with a flap obtained from the mucous membrane of the inner surface of the lower lip. After the flap has been separated from the lip, it is placed on a pad saturated with warm normal salt-solution, with its mucous surface downward, and a pair of scissors, applied flat to the surface, is used to free it of all adhering shreds of fat, so that only the delicate mucous membrane remains. This flap is then placed upon the defect in the lid with its wound-surface down, and its edges are brought into exact coaptation. Sutures are not necessary and not to be recommended. The operated eye is then bandaged, and a piece of gutta-percha tissue covered with ointment is applied over the upper lid to prevent adhesion of the dressing. The flap soon heals firmly, and in four to five days the dressing can be left off.

The operation is successful in relieving the trichiasis, but the contrast between the white flaps and the normal skin is conspicuous. In these severe cases, however, cosmetic appearance is not considered, as the danger of grave ocular complications makes reliable interference absolutely compulsory. Skin from the arm must not be used. We have repeatedly been compelled to remove a skin-flap from individuals in whom a plastic lid-operation for trichiasis had been performed, because the fine hairs of the flap irritated the eye. In such instances the skin-flap should be replaced with mucous membrane. The patient suffers more from the fine hairs of a skin-flap than from misdirected eyelashes; the latter he can at least see sufficiently well to pull out regularly with forceps, while the fine hairs of the skin are almost invisible.

Electrolytic Epilation.—Trichiasis affecting individual lashes is treated by the electric needle. The lid is thoroughly cocained by injection into the skin near the margin of the lid, so that the region to be treated becomes completely white or anemic after the injection (infiltration-anesthesia). The epilating needle, corresponding to the negative pole of the battery (the other pole, attached to a moistened, flat electrode, is placed over the forehead), is then inserted close to the cilia and pushed into the sheath of the hair-bulb. If the right spot is chosen, this can be done without difficulty. A current from one-half to one milliampere, passed for 30 seconds, causes fine vesicles to rise

from the hair-bulb, and permits the hair to be extracted with ease by by the cilia-forceps (Fig. 40). A magnifying lens materially aids in the detection of the exact point of exit of the hair. The epilating



FIG. 40.—Cilia-forceps.

process must be performed in several sittings, as occasionally cilia, which have not been destroyed, grow again and cause fresh irritation.

SPASMODIC ENTROPION.

In mild cases, such as are occasionally produced by the bandaging after cataract operation, the inverted lid-border may be drawn out by

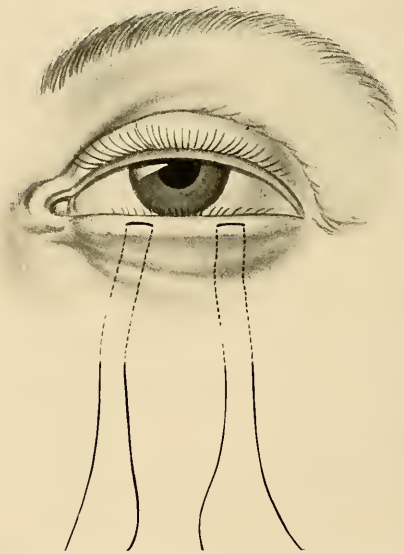

FIG. 41.—Gaillard suture. At the highest point of the inverted lid lies a suture 3 mm. long, the ends of which are passed under the skin to the lower border of the orbit.

painting the skin with flexible collodion; or strips of plaster may be used to hold the lid in its proper position. Adhesive plaster is to be avoided, as it frequently produces an eczema. Zinc oxide plaster is much better, but often does not stick well in this position, as the skin is moistened by overflowing tears. In applying this plaster it is im-

portant to first dry the lid thoroughly; then the strips, 1 cm. wide and 2 cm. long, are slightly warmed and pressed at one end accurately to the edge of the lid, while the other end is drawn downward, pulling the eyelid with it into proper position, and fastened firmly. Disappearance of the entropion may be effected more easily if the patient's eye is left open without a bandage. For protection against mechanical injury, a Fuchs' lattice-frame should be applied with the wire-netting covered with black cloth.

Gaillard Suture.—Spasmodic entropion is readily remedied by the Gaillard suture (Fig. 41), which acts similar to the Snellen suture. A long needle curved on the flat is introduced through the skin at the highest point of the inverted lid and carried downward to emerge at the lower border of the orbit, and the process is repeated with the other end of the suture. Both ends of the suture are then tied over a small gauze compress. It is evident (Fig. 42) that by this suture the highest part of the inverted lid is drawn downward, a fold of the skin obliterated, and the edge of the lid is everted and turned away from the eyeball. Two sutures are introduced, one at the junction of the inner and middle thirds, and the other the middle and outer thirds, of the lid. The sutures remain four or five days, and are removed by cutting the threads close to the skin near the gauze compress, and drawing them through the wound.

FIG. 42.—Gaillard suture. Vertical section through the inverted lower lid with the suture inserted.

SENILE ENTROPION.

If the lower lid is affected, excellent results follow the horizontal excision of an oval piece of skin from the lid. By picking up a fold of the skin with the fingers, an approximation can be made of the amount of excision necessary to bring the lid into proper position. The skin should be about $\frac{3}{4}$ cm. wide at its greatest width, and is readily removed with scalpel or lancet, after the usual ivory plate is placed between the eyeball and the lid. The wound, the upper edge of which should correspond with the border of the lid, is then closed by several vertical sutures. The resulting scar is hardly visible.

Graefe Operation.—This consists in the excision of a triangular piece from the skin of the lower lid (Fig. 43). The first incision, 3 cm.

long, runs parallel to the edge of the lid at a distance of 3 mm., and from both ends (*bc*) of the middle third of this cut, two other incisions (*be* and *ce*) are made downward, which uniting (*e*), form with *bc* an equilateral triangle. The area of skin thus circumscribed is excised, and the edges of the wound at *b* and *c* are slightly undermined. The first suture approximates the two lateral angles (*bc*) of the wound. The skin is, therefore, shortened and stretched horizontally, exactly at the lower border of the tarsus, and the latter pushed toward the eyeball, while the free border of the lid is rotated outward away from the globe. The rest of the wound is closed by two additional horizontal sutures.

Immediately after operation the lid is in a state of marked ectropion,

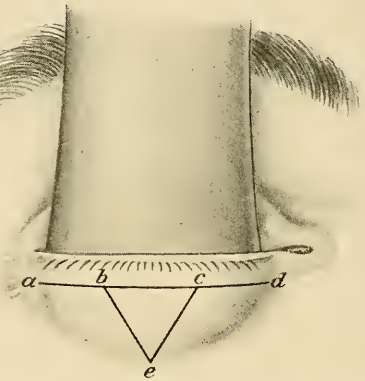

FIG. 43.—Graefe operation. Horizontal incision (a. d.) through the skin 3 cm. long, parallel to and 3 mm. from the edge of the lid. From the middle centimeter (b. c.) two incisions (b. e. and c. e.), converging below. The circumscribed section of the skin is excised. Suture of the two lateral sides (b. e., c. e.) of the triangle.

indeed, its middle portion forms a protuberance, but this disappears within a few days as the skin relaxes and the lid slips back into its normal position. If the first suture is too near the edge of the lid, the stretched skin presses the free border of the lid backward against the eyeball and increases the entropion, and if inserted too low, below the tarsus, it naturally has little or no influence on the position of the lid. It is, therefore, important that the first incision is parallel to the edge of the lid, and corresponds approximately with the lower border of the tarsus; *i.e.*, 3 mm. from the edge of the lid. Occasionally the lid has a tendency to slip back from the position of ectropion into that of entropion. This may be prevented by a small gauze-compress, applied along the lower border of the tarsus, which will press it backward against the eyeball. In three or four days the sutures may be removed.

CHAPTER V.

CANTHOTOMY—CANTHOPLASTY—TARSORRHAPHY.

The purpose of canthotomy is to temporarily, and of canthoplasty to permanently, lengthen the palpebral fissure.

CANTHOTOMY.

Indications.—Widening of the palpebral fissure is indicated if there is a marked secretion of the conjunctiva (blennorrhea, trachoma, etc.), and the narrowness of the fissure makes it difficult to carry out the treatment and promote removal of the secretion. It is also performed in children with blepharospasm and edema of the lids, and is

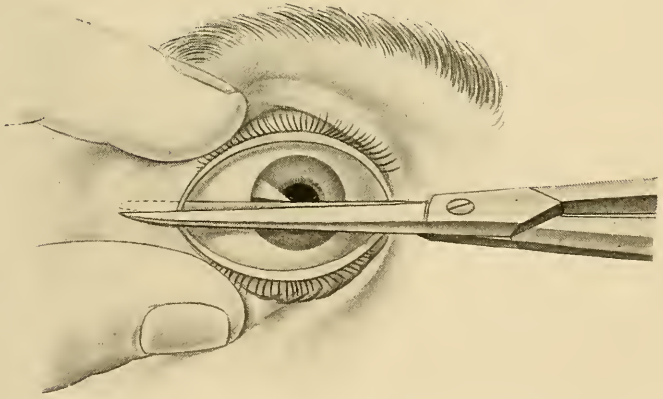

FIG. 44.—Canthotomy. By means of two fingers the external canthus is separated and at the same time pushed slightly toward the nose. A pair of straight scissors is introduced horizontally with the blunt blade posterior.

an effectual operation for spasmodic entropion, as the cut of the scissors includes the point of insertion of the orbicularis muscle; namely, the external canthal ligament.

Canthotomy is occasionally necessary to permit a larger field in operations on the eye or in entering the orbit. It is sometimes indicated in iridectomy, especially in pathologically enlarged eyes (buphthalmos); and in the operation of cataract upon patients whose eyelid-

twitch considerably. It is done to assist in performance of exenteratio orbitæ; also in ankyloblepharon and blepharophimosis.

Anesthesia.—A 3 per cent. cocain-solution is dropped into the conjunctival sac, and during the second part of the operation a subcutaneous injection of a 1 per cent. solution is made in the neighborhood of the external canthus.

The Incision.—The operation is performed by thrusting the blunt end of a straight pair of moderate-sized scissors horizontally outward into the conjunctival sac beneath the canthus, which is then cut in a horizontal direction with one stroke of the scissors (Fig. 44). Prior to making the cut the skin in the region of the canthus is stretched

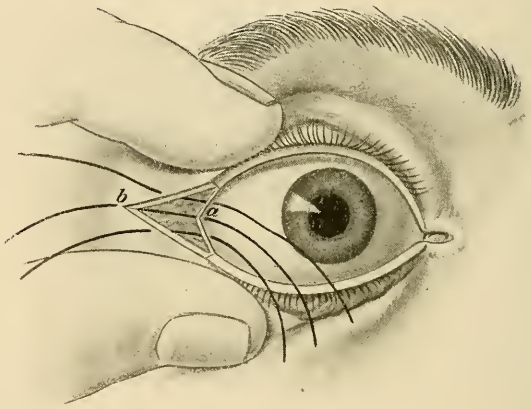

FIG. 45.—Canthoplasty. Position of the sutures for closure of the wound. The first suture unites the angle of the conjunctiva (a.) with the angle of the cutaneous wound (b.).

by the thumb and forefinger of the other hand, which are placed upon the outward halves of the upper and lower lids, separating and drawing them toward the nose. If the cut of the scissors is to be made on the left eye with the right hand, the hand must be strongly flexed dorsally to bring the scissors into the proper position, or the operator must stand behind the patient. Bleeding is stopped by compression. The wound closes in a short time without leaving a permanent increase in the width of the palpebral fissure. Only the faint external scar remains as a visible sign of the operation.

CANTHOPLASTY.

In order to secure a permanent widening of the palpebral fissure, sutures are introduced in the opening made at the external canthus,

uniting the conjunctiva and skin. In addition to the ordinary incision as described under canthotomy, an additional cut should be made with a small pair of scissors into the connective-tissue strands which attach both lids to the edge of the orbit, so that the lids are freely movable and may readily be separated from each other.

The appearance of the rhomboidal wound at the canthus is seen by drawing the lids apart (Fig. 45). If the conjunctiva is slightly undermined, it can readily be drawn outward, so that the angle of the conjunctival wound (*a*) may be connected with the angle of the cutaneous wound (*b*). All that is then necessary to unite the lateral sides of the conjunctival and cutaneous wounds is to introduce one suture above and one below.

Kuhnt Operation.—In trachoma, with markedly contracted conjunctiva, it may be difficult or even impossible to unite the conjunctiva

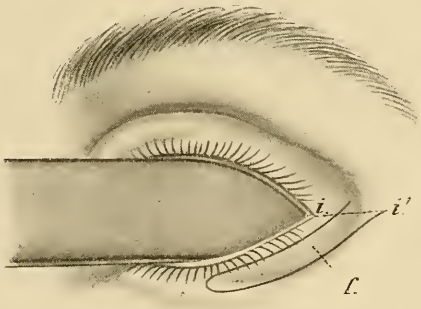

FIG. 46.—Kuhnt operation. The lidplate is inserted outward under the canthus. The direction of the incision, to be made later through the canthus, is marked on the patient with ink dots (i. i'.). A flap of skin (f.) is cut out of the lower lid, the base corresponding to the outer half of the marked line.

with the skin. The sutures tear out so that the wound closes and the palpebral fissure returns to its former small size. These are usually urgent cases, eyes in which trachoma has caused pronounced infiltration of the cornea that has resisted all treatment. This class of cases is best managed by Kuhnt's modification of canthoplasty, which is performed as follows:

A few India-ink dots are drawn to indicate the line of incision for the canthoplasty, the line being a straight prolongation of the palpebral fissure from the external canthus to the outer border of the orbit. An ivory plate is then inserted under the outer commissure, and, while stretching the skin a little upward and toward the temple, the operator

cuts a flap of skin 2 mm. wide from the lower lid (Fig. 46). The base of the flap is so situated that it remains adherent to the upper edge of the wound after the incision for canthotomy is made (Fig. 47). The

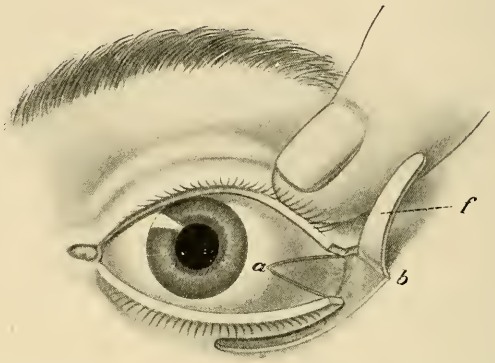

FIG. 47.—Kuhnt operation. The flap (f.) is separated, and has shortened somewhat by contraction of the tissue. The incision through the canthus is accomplished so that the same wound-angles in the skin (b.) and conjunctiva (a.) are produced as in Fig. 45. But here the angle (a.) has receded toward the cornea, as a result of retraction of the contracted conjunctiva.

length of the flap corresponds approximately to one-third the length of the lid, but is cut a little longer, as the skin always retracts after it is detached. The orbicularis fibers, which appear in the lid after removal

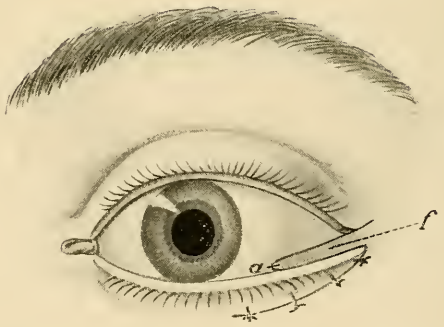

FIG. 48.—Kuhnt operation. The wound on the lower lid is sutured, the flap of skin (f.) being fitted into the angle of the conjunctival wound (a.).

of the flap, are excised. The horizontal external incision is then made as in ordinary canthotomy, so that the skin-flap hangs free from the upper edge and several millimeters from the outer angle of the wound.

All adhesions of the lids to the edge of the orbit are thoroughly cut, so that the lids can be moved freely, and the bulbar conjunctiva is undermined to the boundary of the cornea. After arrest of hemorrhage the wounds are closed by sutures. Three sutures are sufficient for the wound on the lower lid, and a fourth fastens the temporal border of the lower lid obliquely outward near the outer angle of the wound. The cutaneous flap itself is laid in the wound, so that its apex is inserted either under the angle of the conjunctival wound or is fixed to the latter with a suture (Fig. 48).

As there is usually a coexistent entropion of the lower lid the removal of a cutaneous flap exerts a favorable influence on this anomaly. If the upper lid should need correction, the flap could be taken from it instead of the lower lid.

In severe cases of trachoma we have repeatedly observed a favorable influence of the operation upon the condition and the further treatment of the conjunctival disease. Certainly, from a cosmetic standpoint, the operation cannot be recommended, but in these severe types of disease the personal appearance need no longer be considered. The healing of the cutaneous flap occurs promptly, and the palpebral fissure remains permanently and considerably widened. The sutures may be removed in a few days.

TARSORRHAPHY.

The object of tarsorrhaphy is to shorten the palpebral fissure.

Indications.—The operation is indicated in cases of facial paralysis that will presumably exist a long time or will never recover, and in marked exophthalmos resulting from Basedow's disease or from tumors. It is also indicated when the lagophthalmus is caused by congenital shortening of the eyelids; it serves to overcome paralytic ectropion, as it raises the drooped eyelid; and is recommended as a preventive of cicatrical ectropion in persistent carious fistula on the border of the orbit. Even though the operation in itself is disfiguring, it may still be indicated for cosmetic reasons in rare cases, such as widening of the palpebral fissure after strabismus operations, or unilateral enlargement of the eyeball (unilateral, high grade myopia) and its consequent widening of the palpebral fissure. Tarsorrhaphy is also performed occasionally as a preliminary to plastic operations.

External Tarsorrhaphy.—The method of Fuchs is the operation of choice in the majority of cases. At the outset the required

shortening of the palpebral fissure must be clearly determined. This is best done by holding the two eyelids together, with the fingers placed at the external canthus, and shortening the palpebral fissure by advancing the fingers until the patient is able, completely or almost completely, to close the eye. At most, a few millimeters will be sufficient, and even in severe cases should not exceed 8 mm., on account of the marked and unsightly asymmetry of the palpebral fissure that would be produced. This would necessitate the same operation at the internal canthus, of which mention will be made later.

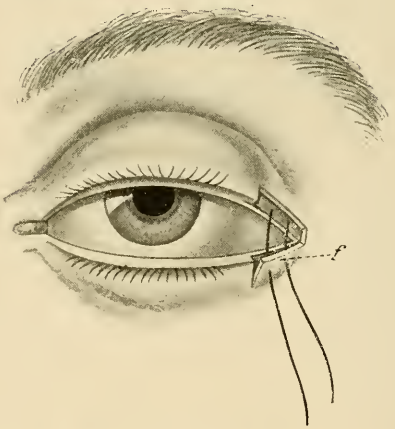

FIG, 49.—Fuchs operation. From the external part of the lower lid a flap of skin (f.) is formed, and the cilia removed. From the skin of the upper lid a corresponding long strip is excised. The suture is already introduced; above near the edge of the lid, below near the base of the flap.

The Incisions.—After cocain injection into the upper and lower lids, particularly toward the intermarginal border, and protection of the eye with the ivory plate, a small vertical incision is made through the skin of the upper and lower lids, not only to indicate how far the operation is to be conducted, but also to secure equal distances for both lids. An intermarginal incision is made on the lower lid, beginning exactly at the external canthus, and extending to the point previously outlined. The incision is best made with a lancet, which is held parallel to the surface of the lid, so that the point perforates neither the skin nor the tarsus posteriorly. While drawing the skin of the eyelid outward, the assistant presses the obliquely-held ivory plate forward, so that the eyelid is well stretched. By light pressure the operator himself holds the eyelid against the plate and places the point of the lancet upon the intermarginal border. If the lancet is sharp, it will readily penetrate

between the two plates of the eyelid. At the same time a little undermining can be done.

The previously made vertical cutaneous incision, 3 mm. long, forms with the intermarginal cut a small cutaneous flap (Fig. 49, *f*), with the eyelashes still in position on the edge corresponding to the border of the lid. The roots of these lashes are then destroyed by scissors applied flat against the raw side of the flap, so that the cilia later fall out.

A similar intermarginal incision is made on the upper lid from the external canthus to the previously made vertical cut, and also a cutaneous incision parallel to the lid-border and at a distance of about 2 mm. from it and of the same length as the intermarginal incision. The lancet undermines the bridge of skin thus formed, and two cuts with the scissors sever its connections externally and internally. In this way a raw surface is produced on the edge of the upper lid. The flap

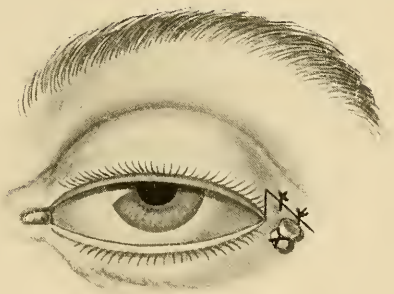

FIG. 50.—Fuchs operation. Appearance of the palpebral fissure after the tying of the sutures. Both ends of the first suture introduced are tied over a small gauze-compress.

formed from the lower lid is now adjusted so that it covers this raw surface and unites with it. The tarsi are not injured in this operation, and the tarsus of the lower lid slips in beneath that of the upper lid.

The Sutures.—The two needles of a double-armed suture are passed through the upper lid near its border, 2 mm. apart, proceeding from the conjunctival surface outward. A short loop of thread, therefore, lies on the conjunctival surface side of the upper lid, but this is of no consequence, as it does not come in contact with the cornea, which lies farther inward. The two threads then pass through the base of the flap on the lower lid from the raw surface outward to the cutaneous side, with about the same distance between the perforations as

before (Fig. 50). The ends of the thread are then tied over a small compress of iodoform gauze, which draws the base of the flap to the wound-edge of the upper lid, and causes the flap itself to cover the raw surface. Several fine cutaneous sutures are introduced to unite accurately the edges of the flap with those of the wound on the upper lid. A light dressing is applied over the eye, the other eye being uncovered. The stitches may be removed on the third day.

Results.—The advantage of the operation is that a surface union of the lids is produced, which prevents a separation of the suture—an occurrence which is often encountered in other methods. The disadvantage lies in the sacrifice of a part of the normal cutaneous border of the lids. If at some future time it should be desirable to re-open the palpebral fissure, it is not difficult to free the upper and lower tarsal borders, as the tarsus has not been injured, and a few sutures will unite the edge of the cutaneous wound with this edge of the tarsus, but the border of the eyelid thus made would naturally have no cilia. Tarsorrhaphy is, therefore, performed only when presumably no recovery is to be expected, *e.g.*, in many cases of facial paralysis. The operation may be accompanied by unpleasant results, caused by an inequality in the length of the intermarginal incisions on the upper and lower lids. If, for example, a longer piece is excised from the upper lid than will be covered by the flap from the lower lid, the latter will, of necessity, be pulled obliquely upward and inward, producing an ugly fold resembling an epicanthus. At the same time the cilia on the neighboring part of the lower lid may assume an oblique direction, and a trichiasis will be produced. Should this occur additional eyelashes must be destroyed by electrolytic depilation.

Internal Tarsorrhaphy.—If Fuchs's tarsorrhaphy is to be performed at the internal angle of the lids, two precautions must be observed: (1) The internal canthus itself should not be touched by the operation and (2) the lachrymal canaliculi must not be wounded. The intermarginal incision is, therefore, made from the previously determined point to the end of the tarsus, *i.e.*, to the punctum lachrymale. If the incision is made accurately in the intermarginal border, and the lancet penetrates between the two surfaces of the lid, there is no danger of wounding the lachrymal canaliculus, as it is embedded in the tarsus itself. The same is true of the upper lid. In other respects the operation is the same as the external angle. The horseshoe-shaped excision is retained and appears as a shallow depression. Should it be desired

to re-open the palpebral fissure in the future, a normally formed internal palpebral angle can be obtained.

In marked cases of exophthalmos it may be absolutely necessary to perform the operation simultaneously at the outer and inner angles of the lids, in order to transform the palpebral fissure into a short central aperture.

Arlt Operation.—Median tarsorrhaphy may also be accomplished by removing, by means of forceps and scissors, a strip of skin from the upper and lower lids near the inner angle, in such a manner that the wounds thus produced meet in a sharp angle at the internal canthus of the eye (Fig. 51). Three sutures introduced vertically unite the wounds and close the palpebral fissure from its inner side.

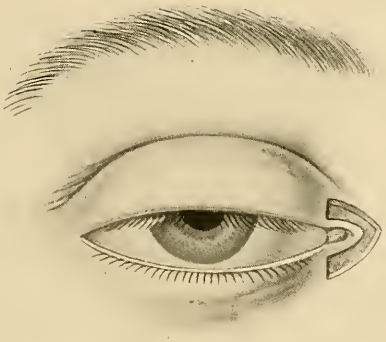

FIG. 51.—Arlt operation. Horseshoe-shaped excision along the inner canthus from the skin of the upper and lower lids.

This operation has the advantage that the cilia are not injured, so that an eventual re-opening finds the edges of the lids intact.

Complete Closure of the Palpebral Fissure.—This procedure is only undertaken in rare cases, as after an extensive corrosion, in which the skin of the upper and lower lid has been partially destroyed, and the production of a cicatricial ectropion seems unavoidable. The latter can be prevented by complete suture of the palpebral fissure. In order not to destroy all the eyelashes, the lancet denudes the edges of the lids behind the cilia, and the lids are then sutured together; or, if possible, a narrow strip may be cut out of the skin of both eyelids near their borders, and the two raw surfaces united by sutures. If the lid has been *completely* destroyed, without serious injury of the eye, the latter is protected by a moist chamber until cicatrization has

ceased, and it is possible to perform a plastic operation, such as described for cicatricial ectropion.

If tarsorrhaphy is performed for pronounced exophthalmos, the rest of the palpebral fissure should be temporarily closed by several sutures without denudation of the lid-margin, in order that the flap may adhere firmly, and the sutures not tear out prematurely, owing to the strong tension.

In paralytic ectropion, a triangular fold of skin may be excised, as in senile ectropion, and tarsorrhaphy also performed, a combined operation resembling the Szymanowski method. In this manner the somewhat enlongated lid is shortened and brought to lie more closely against the eyeball.

CHAPTER VI.

PLASTIC OPERATIONS ON THE EYELIDS WITH PEDICLED FLAPS—SYMBLEPHARON.

Plastic operations with pedicled flaps are particularly adapted to cases in which a lid affected with a neoplasm must be excised. As long as a new-growth in the lids has merely involved the skin, and the tarsus is wholly preserved, the plastic operation with a pedicled flap from the surrounding tissue differs in no respect from the identical operation in other regions of the body.

Fricke Operation.—This method is used in case of an extensive skin-defect in either the upper or lower lid. A flap is taken from the neighboring skin, as is shown in the illustration (Fig. 52), and the base joined to the defect in the tissue (*d*). Because of possible retraction of the skin after it has been dissected free, the flap (*f*) must be cut about one-third larger than the area to be covered, and the base wide enough to insure perfect nutrition. For the same reason, rotation of the flap should be made as easy as possible by an adequate undermining of the underlying tissues. The flap, which now covers the excised area, is held in its new position by sutures. The opening, caused by the removal of the flap, is dissected sufficiently back of the margins, and the skin-edges brought together, at least in part, by sutures, the remainder being left to heal by granulation or covered by transplanting epidermis, according to the method of Thiersch, or by a small non-pedicled flap (Wolfe graft). The bulging at the base of the flap produced by the necessary rotation soon disappears, so that no subsequent disfigurement exists.

If, however, the margin of the lid has already been involved, as new-growths usually spring more particularly from the lid-margin, the restoration of the lid becomes a more difficult matter.

Dieffenbach Operation.—This is especially indicated for the lower lid. As a recurrence of a lid-neoplasm is only prevented by cutting at least a full half-centimeter away from the growth, a large part of the lid must be sacrificed even if the tumor is not extensive, and, if

large, the whole lid must be excised. There is no advantage in retaining the small remnants of the lid at either end of the incision, and the operation is not rendered more difficult by a total extirpation of the lid. The tear-ducts are to be spared only if they lie beyond the field of operation.

The diseased lid is removed by a triangular incision, the base of which corresponds to the lid-border (*bc*) (Fig. 53). In the direction

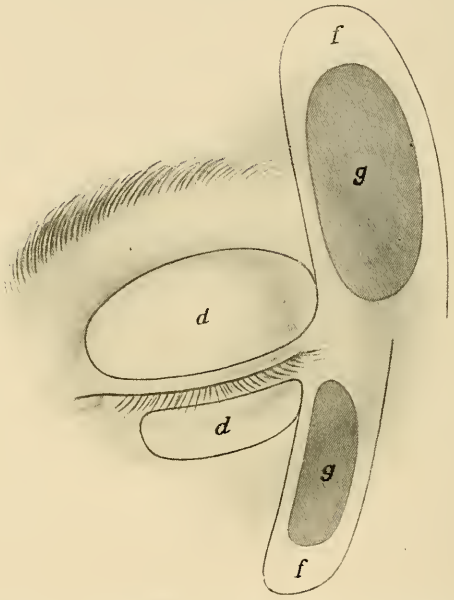

FIG. 52.—Restoration of a skin-defect in the upper and lower lid (after Fricke). d., defect; g., pattern of gutta-percha paper, cut the same size as the defect, and laid on the place selected before the excision of the flap, in order to estimate more readily the size of the latter; f., flap to be cut out.

of the base an incision (*ab*) is made outward toward the temple, somewhat larger than the defect to be repaired, as the flap contracts after it is freed. From the outer end of this incision another cut is carried downward, parallel to the outer side of the triangle. A flap can now be dissected off, the base of which lies below. Sufficient freeing from the underlying tissue affords easy rotation inward upon the defect. The upper edge of the flap is sutured to the remains of the conjunctiva, and corresponds to the lid-margin, while the inner edge is secured to the neighboring skin by strong sutures. The surface from which the flap was taken is closed in as much as possible by sutures after a

thorough undermining of its edges. The remainder of the exposed area is left to heal by granulation, or a skin-graft is inserted and stitched in position.

Results.—Although the diseased area is covered in by healthy skin, the flap, lacking a cartilaginous substratum, yields and sinks downward continuously, and becomes attached to the eyeball by the cicatrix. The conjunctiva is also materially shortened, the motility of the eyeball usually considerably lessened, and hairs grow from the skin of the flap and cause a clouding of the lower half of the cornea.

Dieffenbach-Büdinger Operation.—Büdinger's suggestion to use a flap made of the cartilage of the ear represents a decided improvement in the Dieffenbach operation. After the skin has been freed, as

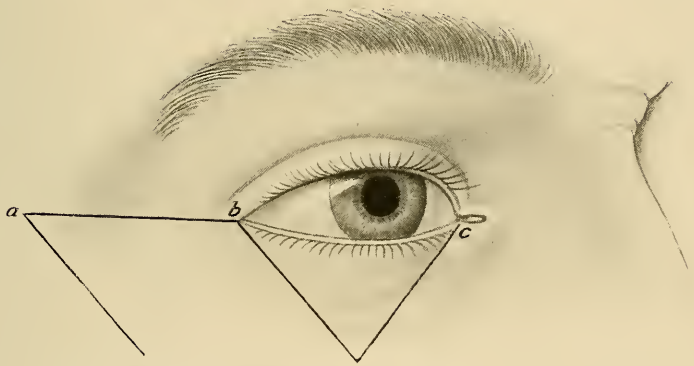

FIG. 53.—Restoration of a lower lid after Dieffenbach. The lower lid is excised in triangular fashion; that is, a pre-existing defect is brought into this form. Formation of a quadrangular skin-flap (a. b.), which is freed from its underlying tissues.

in the foregoing description, a flap, including both skin and cartilage, is excised from the posterior surface of the ear. It should be as long as the lower lid, have a straight edge corresponding to the lid-margin, and a second somewhat convex edge corresponding to the lower border of the tarsus. Because of the narrowness of the normal tarsus of the lower lid, only a small piece of cartilage is removed from the ear, but to cover the wound-surface a much larger piece of skin is required. A vertical incision of adequate length is made on the posterior surface of the ear. This will at once retract somewhat, and at the point of retraction an incision is made through the cartilage, corresponding to the length of the tarsus. This edge of the flap forms the new lid-margin. Next, the dissection is continued 3 mm. further beneath the

cartilage, that is, between cartilage and skin of the anterior surface of the ear, and the cartilage is cut through from in front without wounding the skin. In order to free the skin, it is dissected an additional 5 mm. with a slightly convex incision. The freed flap shows the shape viewed from the raw surface (Fig. 54).

As the ear-cartilage is too thick, it is shaved down by cutting away thin lamellæ with a scalpel applied flatwise, until it approximately equals the thickness of a normal tarsus. This flap is fastened by sutures to the previously dissected skin-flap (Fig. 55), so that the wound-surfaces are apposed to each other; that is, the skin of the ear-flap is directed posteriorly toward the eyeball and the straight edge comes to lie against the free upper margin (*ab*) of the pedicled skin-flap. In order to avoid unsightly indentations of the new lid-margin, the sutures, armed with two needles, are pushed from behind forward through the skin and the cartilage, 2 mm. below the free margin, and tied over a glass bead. At least three sutures are necessary. In like manner one or two sutures are brought through the lower border of the flap of skin and cartilage in an anterior direction and tied, to secure a firm approximation of the flap to its new base.

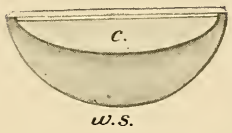

FIG. 54.—Flap from the posterior surface of the ear; (c.,) cartilage; (w. s.,) skin seen from the wound-surface.

The pedicled flap, with its posterior surface thus provided with a sufficiently large cutaneous surface, is sutured, after adequate rotation, to the edges of the defect, as in Dieffenbach's original method. To prevent mechanical injury to the cornea by the flap, which is somewhat stiff at first and readily produces erosions and ulcers, I am accustomed to draw the upper lid far downward by two stitches passing through its margin, and to bring both ends of each suture through the base of the flap, which has been rotated inward; not until then is the flap fastened to its new position. Thus, the new lower lid lies at first against the upper lid. The defect produced externally is covered in exactly the manner described by Dieffenbach. The flap of skin and cartilage heals in promptly. Both eyes are bandaged and the dressing changed for the first time after two days. The fixation-sutures of the upper lid, which were tied over small gauze pads, are allowed to remain until they cut through, which is usually in from five to six days. However, the upper lid continues to hang down for several days more, completely covering the cornea, but by the time it can be

elevated, the flap of skin and cartilage have long since healed, and in its moist environment the skin has become so delicate that an injury to the cornea need no longer be feared.

The flap, which at first appears thick and bulging, later becomes gradually thinner, resembling a lower lid deprived of its eyelashes, especially as it stands up freely owing to its cartilaginous substratum, and is not drawn against the eyeball through the formation of a cicatrix.

This method is particularly valuable, because the motility of the eyeball remains unaffected, and a deep conjunctival sac is created,

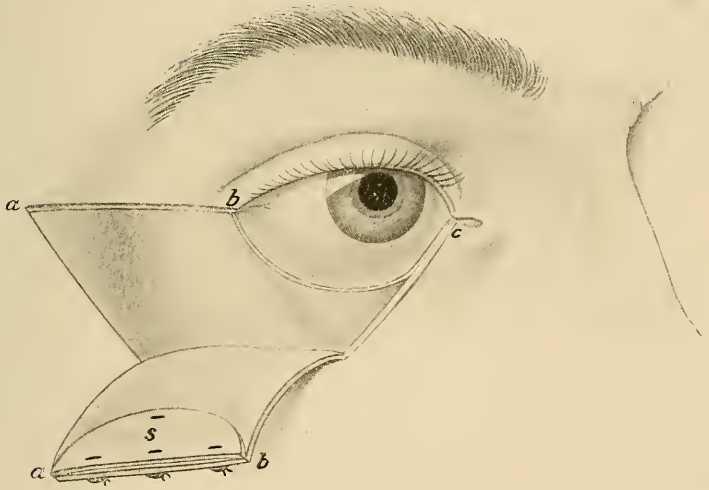

FIG. 55.—Dieffenbach-Büdinger operation. The flap represented in Fig. 54 is here so sutured to the posterior side (that is, the raw surface) of the pedicled skin-flap that the skin (s.) comes to lie posteriorly toward the eye. The flap is now twisted into the defect of the lid and sutured in such a fashion that b. comes to lie in apposition to c. and a. of the flap in apposition to b. of the canthus.

similar to the normal. Furthermore, the transplanted flap, which is free of hairs, does not give rise to corneal irritation. These are sufficient reasons to undertake Dieffenbach's method only with the proposed modification.

If the entire upper lid must be extirpated in the removal of a neoplasm, the eye is usually lost; but an attempt should be made to restore the upper lid by a flap, which is formed according to Fricke's method, its posterior surface being covered in by a delicate layer of epithelium taken from the arm.

SYMBLEPHARON.

The connection between the conjunctiva of the eyelid and the eyeball may be either in the form of isolated bands or cords, which interfere with the movements of the eye and produce diplopia, or include large areas extending down to the fornix, partly or completely obliterating the culdesac.

Partial Symblepharon.—Small cicatricial bands should be separated, the neighboring conjunctiva loosened, and sutures applied to prevent the two raw surfaces from growing together. If the symblepharon is broad, and the wound too large to be covered by a sliding flap of conjunctiva, it will be necessary to dissect either a pedicled flap from the neighboring conjunctiva, or a flap without pedicle, usually from the upper conjunctival fold or from the conjunctiva of the sound eye. A defect in the lower inner portion of the eye may be covered in by a pedicled flap from the adjacent conjunctiva, rotated over the bulbar wound and fastened with sutures. The area produced by the excision of the flap may be allowed to cicatrize, as, lying to the outer side of the original defect, it does not cause new adhesions, or it may be possible to loosen the neighboring conjunctiva sufficiently to close the wound. Pedicled flaps are usually prepared with difficulty, and it is therefore preferable to use a flap taken from the upper conjunctival fold, providing this portion of the conjunctiva shows no cicatricial changes. The normal fold offers ample conjunctiva for broad flaps, but if the membrane in this situation should be contracted, the use of a flap from the patient's other eye offers the best chance of a satisfactory result. The use of mucous membrane from the rabbit has been shown by personal experience to be worthless. Even if the graft adheres successfully, subsequent contraction is so great that the good effect secured is entirely lost.

All methods of covering the defect with conjunctiva must be limited to the eyeball, as flaps large enough for the wound in the eyelid cannot be obtained. Though the covering of the one defect is sufficient in most cases, it is always better to have both wounds provided with epithelium, not only to prevent the formation of a new symblepharon in case the single flap does not heal in properly, but because the scar arising from the uncovered wound may contract later on and gradually draw the lid inward and cause trichiasis; or result in limitation of motion of the eyeball. Many plastic methods have been devised,

therefore, to cover the wound in the lid with a pedicled flap from the neighboring skin or a free flap of epidermis.

Complete Symblepharon of the Lower Lid.—As the defect on the eyeball is too large to be entirely covered with conjunctiva, excellent results may be obtained by a combination of conjunctival and skin-flaps. After thorough separation of the lid from the globe, the wound on the eyeball is covered with a pedicled flap from the upper conjunctival fold and that on the lid with a skin-flap from the lower lid, by Rogman's method (Fig. 56).

Rogman's Operation.—An incision is made in the skin of the lower lid, and the flap (*abcd*) formed, the base (*ad*) of which is situated

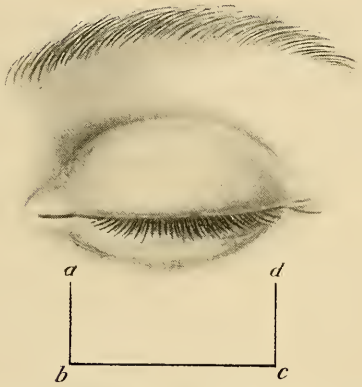

FIG. 56.—Operation for symblepharon after Rogman. After separation of the symblepharon between the eyeball and the lower lid, there is formed from the skin of the lower lid the flap (a., b., c., d.); it has its base at a. d. This flap is rotated backward through a slit in such a fashion that the edge (b. c.) can be sutured to the palpebral margin and the skin—serving the function of a palpebral conjunctiva—is turned toward the eyeball. There is rotation of 180°.

directly at the upper level of the conjunctival fold in need of reconstruction. This flap is as long and as high as the lid. After the flap has been dissected up, the deeper tissue-layer on the level of the conjunctival fold is completely severed, leaving only the skin intact. It is then easy to rotate the flap in through the slit so made, so that its raw surface is turned toward the wound in the lid, after which the edge (*bc*) of the flap is fastened with sutures to the lid-margin. The flap is certain to become attached, as its base remains connected to the surrounding tissues. The wound on the outside of the lid is, as far as possible, tied by sutures. At first, however, there is a slit left through which the new conjunctival sac can be reached from the outer

side. After about eight days, the connection is severed, and the slit rapidly closes by cicatrization.

Rogman, in his original method, repeated this procedure at a later date by rotating through the slit another flap formed from the still remaining skin on the lower lid. I much prefer the foregoing combination to Rogman's original method, as there is too little skin available for the second plastic operation on the lid.

Total Symblepharon.—The most satisfactory operation for relieving a total symblepharon is performed as follows: After dividing the scar binding the lid to the eyeball, a canthotomy is made, and from the end of the skin incision a cut 3 cm. long is made outward and downward and continued inward along the lid furrow. The skin is dissected loose toward the lid, until finally there is a large raw surface which stretches in one plane from the limbus to the lid-border. A large skin-graft of a suitable shape is dissected from the delicate skin of the upper arm, and fitted accurately to the raw surface up to the palpebral fissure. The graft may be sewed with several fine sutures to the lid-margin on the one side, and to the limbus on the other. As the lid is now turned back again into its orginal position, the new skin folds up properly of itself, the place doubled down representing the new fornix. The fold is fixed in position with two sutures, which form a loop and are carried through from this spot out to the cutaneous surface, and their ends tied outside over gauze. The operation is completed by the suturing of the incisions made at the beginning. Both eyes are bandaged and the dressing changed for the first time at the end of three days.

The fornix is at first abnormally deep, but, later, diminishes in size through contraction, without, however, shrinking so much as to prevent free movement of the eye or the comfortable wearing of a prothesis. A prothesis is inserted early, and eventually a properly fitting prothesis is made from Stent's composition, a substance used by dentists for taking impressions. Such protheses extend deeply into the fornix.

Unless an incision is made detaching the entire thickness of the lid, as above described, the insertion of an unpedicled graft is not recommended. It is impossible in the limited space to secure perfect adaptation of the graft to the wound. Shrinkage of the new skin follows and the culdesac is obliterated, and even the employment of the prothesis to hold the graft in position is equally futile.

American surgeons report excellent results with plates of sheet lead, porcelain, hard rubber, or paraffin-covered metal in securing permanent union of the skin-graft to the wound-surfaces. The plan followed is to make the usual separation of the lid and the globe by cutting through all cicatricial tissue, prepare a graft taken from the inner side of the arm of sufficient size not only to cover the raw surface of the globe and the lid but to dip deeply down into the sulcus, in which position it is held by the perforated plate which is cut to fit in the folded graft and keep it in position. The lids are closed with adhesive and the usual dressings applied for four or five days.

CHAPTER VII.

PTOSIS.

Most of the cases of ptosis requiring operation are congenital. The muscular apparatus of the eye in other respects is normal or, in a few instances, is associated with pronounced weakness or absence of the superior rectus muscle from defective development. In paralysis of the levator muscle operation is only indicated after other forms of treatment have failed. In acquired ptosis not caused by a lesion of the levator muscle, other muscles supplied by the oculo-motor nerve are frequently also affected, and binocular vision is impossible because of outward deviation of the affected eye. Complete paralysis of the third nerve of one side is therefore usually a contraindication to the ptosis operation, since the correction of the ptosis makes manifest the latent diplopia, which may constitute a more unpleasant symptom than the lid deformity. It is only in bilateral ptosis of the oculo-motor nerve that operation on the lid of the better and more movable eye is advisable.

Of the operations devised for the relief of ptosis, only those are of value which have as their object the substitution of a new muscular power for that which has been lost. If the levator is not completely paralyzed, a shortening of the muscle may restore its original function (Eversbusch and allied methods). If, on account of total disability, the power of the levator cannot be restored, a substitute is sought in the occipito-frontalis muscle, which, by its contraction, is able to raise the skin of the lid (method of Pagenstecher, Hess and others). Many ptosis patients instinctively contract this muscle, draw up the eyebrow above its normal position at the upper orbital margin, and thereby raise the lid. As the contraction of the frontalis is usually bilateral, there is an abnormal dilatation of the palpebral fissure of the healthy eye, unless the patient prefers to relinquish the raising of the drooping lid. This widening of the fissure is equally evident after ptosis operations in which the occipito-frontalis muscle is employed to raise the lid, and often detracts from the cosmetic results of the operation.

Since the superior rectus and the levator palpebræ muscles are

associated in elevation of the eyelid, the substitution of the action of the former for the paralyzed levator is theoretically a commendable procedure (Motais operation). Ptosis partially corrected by the assistance of the frontalis muscle becomes more pronounced in upward rotation of the eyeball, but this is obviated if the superior rectus muscle has been employed to raise the lid. In this operation, however, a mechanical connection between the upper lid and the eyeball is created which does not physiologically exist, so that the motions of the lid are dependent under all circumstances upon the innervation of the rectus muscle. The attachment of a muscular tongue of the rectus muscle to the tarsus must in itself cause a retraction of the upper lid from mechanical reasons, as the sagittal distance from the insertion of the superior rectus to the tarsus is considerable. Undesirable secondary symptoms of the position of the lid may therefore be produced from the occasional contrary innervation of the two muscles. In winking, for instance, the upper lid falls while the eye remains practically fixed. In sleep, the eyeball turns upward, the same as in voluntary tight closure of the palpebral fissure. If the movement of the upper lid is therefore entirely dependent upon the superior rectus, abnormal phenomena in movements of the lid and eye may result. The superior rectus is therefore not perfectly adapted to act as a substitute for the paralyzed levator.

EVERSBUSCH OPERATION.

Indication.—The advancement of the levator palpebræ is an operation intended to overcome paralytic ptosis. The object of the operation is to strengthen the weakened muscle by shortening and suturing its attachment further forward.

Anatomy.—In order that the operation may be readily understood, it is well to briefly recall the topographical relations in this region. If a sagittal section is made through the orbit near its middle, the appearances seen are approximately as follows (Fig. 57): The border of the orbit, *b*; attached to this is the fascia tarso-orbitalis (*f. o.*), which hangs down like a curtain and becomes thickened below at the tarsus (*ta*); in front of it, the fibers of the orbicularis (*m.o.*) and the skin with the lashes of the free border of the lid; behind it, and passing forward on the roof of the orbit, the levator palpebræ (*m.l.*), which spreads out at the orbital opening like a fan; its aponeurosis joins the fascia tarso-orbitalis, so that immediately above the upper border

of the tarsus no more than a membrane is visible—the tarso-orbital fasica, united with the aponeurosis of the levator palpebræ.

Anesthesia is produced at the beginning by cocainizing the conjunctiva, and later by injecting 1 c.c. of a 1 per cent. cocain-solution under the skin and into the deeper parts of the lid.

The Dissection.—A longitudinal incision is made through the skin of the lid and the orbicularis muscle, midway between the arch of

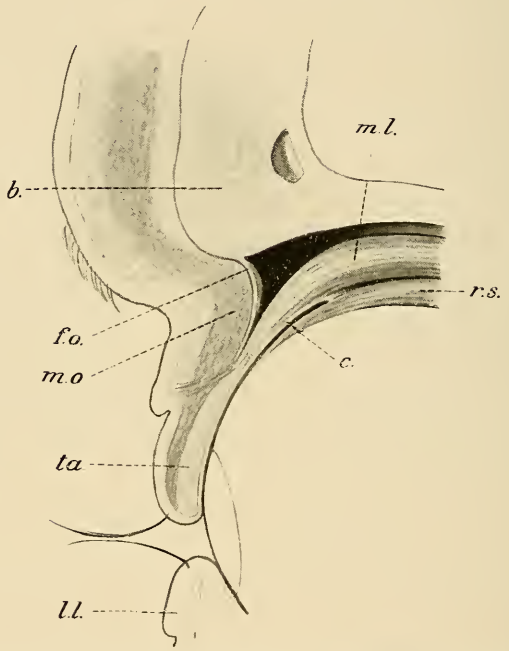

FIG. 57.—Sagittal section through the lids and the anterior portion of the orbit. b., upper border of the orbit; f. o., the tarso-orbital fascia, which is attached to the bone, hangs down and blends with the tarsus (ta.). The levator muscle (m. l.) passes forward above the superior rectus (r. s.), changes here into a fan-like tendon, which, joined by the tarso-orbital fascia, is inserted into the upper part of the tarsus. Behind the tarsus is seen the conjunctiva (c.), in front of it the orbicularis muscle (m. o.). l. l., represents the transverse section through the lower lid.

the eyebrow and the border of the lid. The eye is protected by a horn-plate placed between it and the lid. By undermining to some extent both borders of the lid-wound, it is easy to expose below, the upper border of the tarsus, and above, the thin tarso-orbital fascia.

The fascia is incised at from 5 to 6 mm. above the tarsus, at which point the muscle bundles of the levator palpebræ will be exposed (Fig. 58). The muscle may readily be traced upward into a compact body.

If the cut through the fascia is made too low down, near the upper border of the tarsus, it would come directly upon the conjunctival fornix (*c*) and would not touch the muscle. If made too high up the fatty tissue of the orbit protrudes, covers the field of operation, and renders it difficult to find the muscle. If the fascia is raised with forceps, somewhat above the upper tarsal margin, the correct point for making the opening will be indicated. Close above the spot where it can be first de-

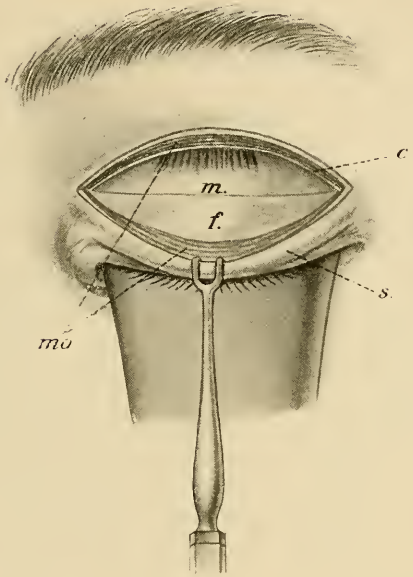

FIG. 58.—Eversbusch operation. The incision made midway between eyebrow and border of the lid through the skin (s.) and orbicularis muscle (mo.) is held open by tenacula. The tarso-orbital fascia is also cut near the upper margin of the wound (the border of the wound (c.) is visible as a white line) and turned down in such a way that the transition of the levator palpebræ muscle into its tendon is plainly visible in the wound; at m. it blends with the tarso-orbital fascia.

tached from the underlying tissue it is split with the scalpel, and in the opening appears the radiating red bundles of the muscle.

The Sutures.—Three catgut sutures are now passed through the muscle in the same manner in which they are inserted in the advancement of the recti muscle—first through the middle. With the horn-plate remaining in place, a fairly strong, curved needle transfixes the middle of the muscle in its entire thickness, at as high a point as possible, and the needle brought out, forming a loop by which the middle fibers of the muscle are constricted. A second loop is placed to the

inner side of the muscle (Fig. 59), and a third loop to its outer, all three at the same height. The muscle is then cut through, 2 mm. below the threads, along the entire length of the lid, and a piece excised 3 to 5 mm. downward to the upper border of the tarsus or even including a small piece of the tarsus itself. The conjunctiva, as far as it comes within the area of the piece to be excised, need not be saved, but may be removed with the muscle. With slight care, how-

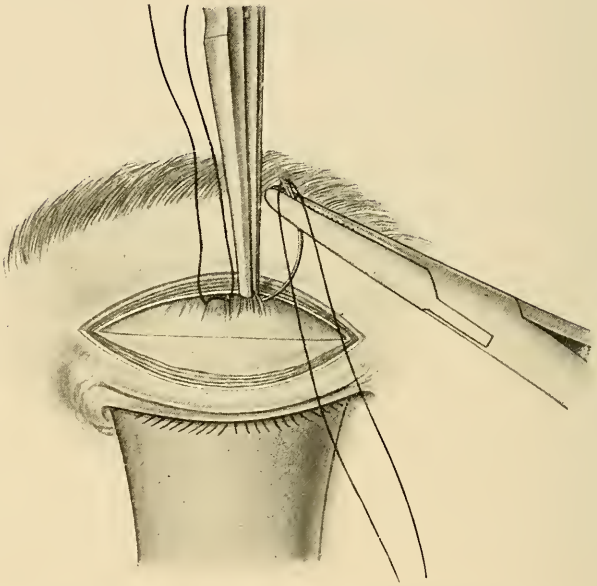

FIG. 59.—Eversbusch operation. The middle thread has already been inserted. The second stitch is just being inserted; to do this the operator lifts the lateral part of the muscle with forceps in the form of a fold and pushes the needle through the entire thickness of the tissue.

ever, it is not difficult to excise the piece of muscle without injuring the conjunctiva; but when a strip of the tarsus is included the conjunctival covering cannot be preserved, as it is too intimately adherent.

The gaping wound is closed either by bringing all six ends of the threads between the tarsus and the orbicularis muscle through the intermarginal space, and tying them over small rubber tubing; or, by sewing the ends of the catgut threads to the anterior surface of the tarsus so that the upper cut-edge of the muscle is drawn over the cut-edge of the tarsus to its anterior surface, to which it heals (Fig. 60).

If the sutures are carried through the intermarginal border, the peripheral lid portion should be pushed upward along the threads until it approaches the central muscle portion containing the thread loops. The threads are then lightly knotted to preserve the lid in the correct position. If drawn too tight, there is caused even with the rubber tubing a circumscribed necrotic spot of the lid border, with loss of the eyelashes.

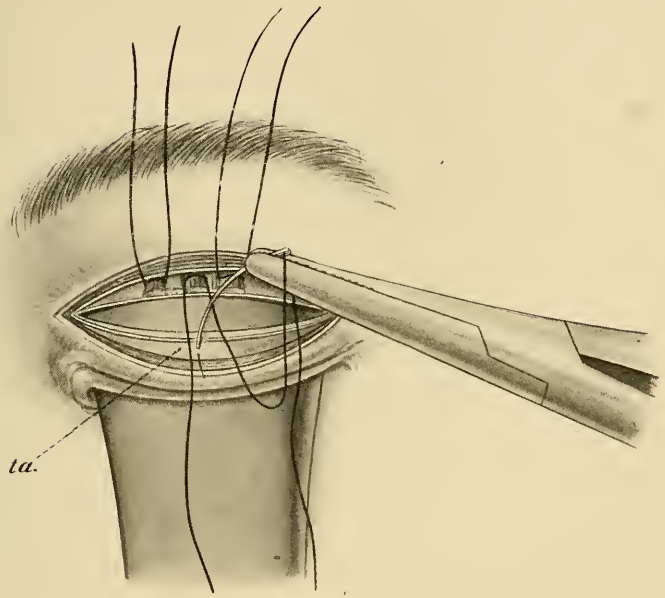

FIG. 60.—Eversbusch operation. After excising a strip of muscle (and conjunctiva) 5 mm. broad, the middle pair of threads is first fastened to the anterior surface of the tarsus (ta.); during the tying the end of the cut muscle is pulled upon the anterior surface of the tarsus and heals there.

The skin-wound is closed over these sutures with several stitches (Fig. 61). This method of operation has the advantage that the margin of the lid is in no way disfigured.

Results.—The operation is successful in most cases, although it is not possible to determine exactly just how much muscle should be excised to attain the desired elevation. Caution must be exercised to limit the excision of the lid sufficiently to prevent resultant lagophthalmos. On this account the piece to be excised should never be broader than 5 mm.

Contraindications.—This operation is only suitable when the levator is not completely paralyzed. To ascertain the extent of the paralysis the patient is asked to close both eyes as in sleep, so that the superciliary ridge may be brought in its normal position on the upper border of the orbit. The skin of the superciliary region must then be fixed in its position on both sides by firm pressure with the thumbs. If now, the patient at command can open the eye, even though only to a limited extent, there is proof of some action of the levator, and the muscle is not completely paralyzed. We may then expect success from the operation of Eversbusch.

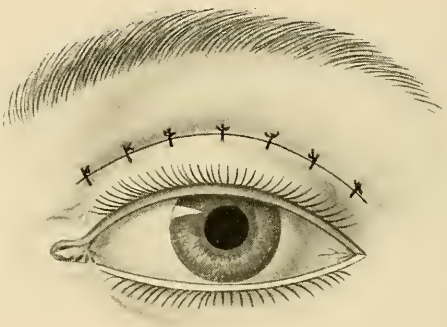

FIG. 61.—Eversbusch operation. Appearance of the lid after the operation. The skin-wound is exactly approximated by several sutures. The edge of the lid remains perfectly intact.

HESS OPERATION.

Indications.—The operation is of value only in cases of ptosis in which the patient absolutely shows distinct contraction of the frontalis muscle. In those who make no attempt to improve their ptosis by contraction of this muscle, the operation promises little.

Anesthesia.—The operation may be most satisfactorily performed under cocain-anesthesia. One syringeful of a 1 per cent. solution (1 c.c.) suffices as an injection into the skin of the eyebrow and lid. Before the threads are brought out at the upper point, a second syringeful must be injected into the tissues about the periosteum.

The Skin Incision.—After previous shaving of the eyebrow, a horizontal incision is made through the skin of the eyebrow parallel and of equal length to the palpebral fissure. The incision should be so placed that the short scar is completely covered by the eyebrow.

The section includes only the skin, as a deeper incision injures large vessels and causes bleeding which would disturb the further course of the operation. After the incision has been made, the skin is undermined downward with the knife along the convex border of the tarsus to a point near the edge of the lid. The beginning of the dissection is made slightly more difficult by the numerous muscle-fibers which are inserted into the skin near the brow, but further down the subcutaneous tissue is loose and easily separated. As the blood, even if

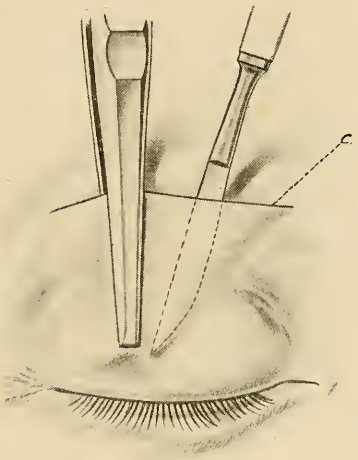

FIG. 62.—Hess operation. Method of undermining the flap. The forceps grasp the skin at as low a point as the progress of the undermining permits. The knife held vertically presses downward behind the skin and is observed by the operator from the front through the skin. (c.), section through the skin.

moderate, interferes by collecting in the pocket constituting the field of operation, it is recommended to control the position and progress of the knife from without through the skin. This may be done by pushing the knife downward in a perpendicular position, parallel with the skin, and fixing the skin at as low a point as possible (Fig. 62). The skin is thus undermined in the whole length of the incision with a few strokes, and a four-cornered pocket produced. This avoids button-holing of the skin, which would follow an attempt to operate along the posterior surface of the skin with an insufficient view into the pocket, a difficult procedure with a small incision.

The Sutures.—After the undermining is completed, the sutures are inserted. The strong silk threads are doubly armed with long, flat

needles. In all, three sutures are employed, the first in the center of the lid, the two others to the sides. Both needles of the first thread are pushed through the lower part of the skin, at a distance of approximately 4 to 8 mm. from the edge of the lid. The skin is fixed with the forceps, one blade of which remains in the pocket, and the other lies on the skin at the point of intended transfixion, in order to prevent retraction of the lax skin when the sutures are inserted (Fig. 63). The needles with the thread are now brought out through the

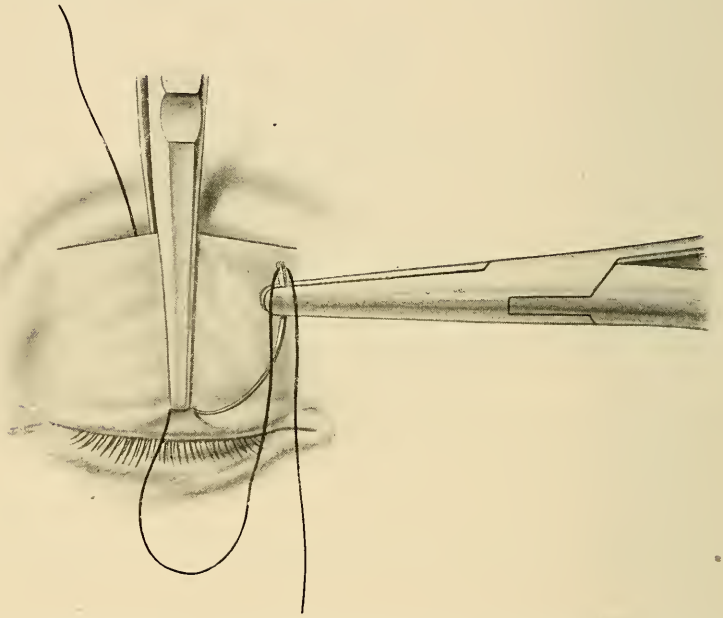

FIG. 63.—Hess operation. Application of the sutures. The forceps, one blade of which should be in front of, the other in the wound, grasp the skin just where the needle is to be inserted. One end of the thread has already been drawn through, the needle mounted on the other end has only just been inserted.

opening in the skin and directed upward. In like manner, the outer and the inner sutures are inserted, each about 1 cm. from the middle stitch. The needles of the middle thread are then pushed upward behind the upper edge of the wound near the periosteum, behind the muscle, therefore, and are brought out through the skin close to one another at about a distance of $1\frac{1}{2}$ to 2 cm. from the incision. The outer threads are treated in the same way. The needles of the inner thread are not inserted directly perpendicularly, but are inclined a little inward toward the median line.

The three threads are next tied over iodoform pads. This raises the lid and at the same time forms a fold in the skin, corresponding to the point of entrance of the threads, similar to the normal fold of the lid. The insertion of the threads through the skin of the lid, which as stated vary from 4 to 8 mm., must be adjusted according to the position of the fold of the lid of the other eye. A fold lying too high is just as disfiguring as one too near the edge of the lid.

Slight traction on the threads raises the lid so that the palpebral fissure readily attains its normal width, but in tying the threads they must be drawn up sufficiently to lift the lid higher than normally, and cause an over-correction. The threads should not be drawn too tightly, or they will cut through quickly, without materially elevating the lid more than with threads drawn moderately tight. The skin-wound is closed with several silk sutures.

The Dressing.—Immediately after the sutures are tied, total lagophthalmos is naturally produced, and the eye is to be covered with a celluloid shield, so as to produce a comparatively air-tight covering (Fig. 64). The shield is fastened along its border with adhesive strips, and, if extensive spaces exist between shield and underlying parts, they should be filled in with absorbent cotton. Within a few minutes the shield becomes moist, and under this dressing the eye may remain for weeks without the slightest sign of irritation. As the celluloid shield is sufficiently transparent to permit a view of the eye, the dressing is changed only when secretion is present and the eye must be cleansed.

After-treatment.—The sutures closing the skin-wound may be removed in three days, but the sutures retaining the lid in its elevated position should remain undisturbed as long as possible—at the least, fourteen days, and even longer if they have not become loosened. At the end of three weeks they are usually so loose as to have lost their hold and may be easily withdrawn after being cut. The object of retaining the stitches is the formation of cords of scar-tissue along the threads, which not only unite the lid with the frontalis muscle, through which the threads have been brought, but also serve as tendons by means of which this muscle elevates the lid.

If the threads produce an over-correction, it is not necessary to form a loop and tighten this frequently in order to maintain the lid in its elevated position. The chances and results of the operation are always improved if the threads are moderately tight at the outset. As the lid is not shortened by excision, but only by the pushed-up anterior (skin)

flap of the split lid, which unites at a higher point with the posterior flap and raises the lid, lagophthalmos need not be feared. Of the many cases of the Hess ptosis operation that the author has performed personally or has seen, lagophthalmos has not occurred, a strong point in favor of this method. It is, however, to the disadvantage of the

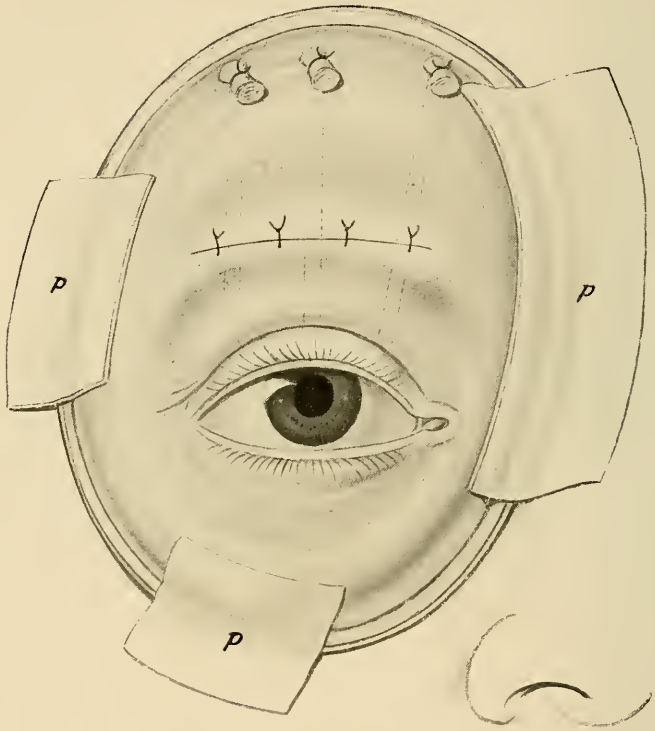

Fig. 64.—Hess operation. The skin-wound has been closed by several sutures. The three fixation threads, of which the inner inclines a little toward the median line, are tied over pads. The lid, strongly elevated, stands off a little from the bulb, the new fold of the lid corresponding to the puncture points of the threads. For the protection of the eye, which cannot now be covered by the upper lid, a celluloid shield is employed; it is fastened at its circumference by strips of zinc oxide plaster, only a few pieces of which show.

operation that we are not certain at the beginning of the terminal results, but this is true of any one of the many operations for ptosis which have been recommended. There is no method that will with certainty make the palpebral fissure of the affected side exactly the same width as that of its normal fellow.

Results.—The results of the Hess operation are in the great majority of cases good; occasionally they are excellent, and but rarely unsatis-

factory. Permanent over-correction need never be feared. In bilateral ptosis especially, it should be the operation of choice. The scar at the point of incision is later covered by the eyebrow, and, if the sutures are properly inserted, a good position of the fold of the lid is obtained.

Occasionally, after the Hess operation, the patient, having the same degree of ptosis as before, lifts the operated lid, even to the normal breadth of the lid-fissure, only at the moment when the sound eye is closed. The explanation for this may be found in the fact that, so long as the patient can use his healthy eye, he is not inclined to put the frontalis muscle in action. Likewise, after operation on one side, the patient can open this eye to its normal width, but only with great elevation of the lid of the other eye through excessive simultaneous contraction of the frontalis. The bilateral innervation of the frontalis muscle brings about in such individuals an excessive widening of the palpebral fissure on the sound side, while effecting only the normal opening on the affected side.

Contraindications.—The operation is contraindicated in insufficient contraction of the frontalis and in cases of paralysis of the superior rectus muscle or total ophthalmoplegia. If the eye, during sleep, is not drawn upward under the upper lid, there is danger of resultant disease of the cornea. Complications may also be brought about by swelling of the skin of the upper lid after operation, projecting it downward over the border of the lid. The direct contact of this tissue with the cornea may produce erosions and ulcerations, as has been my personal experience in two cases.

In this, as in every other correction of ptosis, the possible occurrence of diplopia must be considered because of pre-existing paralysis of the ocular muscles. This is just as important a contraindication to the operation for ptosis, as an abnormal position of the affected eye, for example, by secondary contractures after paralysis.

PAGENSTECHER'S SUTURES.

The stitches in the Hess operation are essentially the same as those recommended by Pagenstecher. The great efficacy of the former is due to the change in position of the anterior layer of the lid brought about by the sutures. Pagenstecher's sutures should be used only in the slightest forms of ptosis. As the sutures are allowed to remain in place for a long time, it is best to employ wire, the upper end of which

is twisted, thus shortening the wire and elevating the lid. In order to avoid cicatrices in the skin, the sutures are introduced subcutaneously (Fig. 65). From the point of entrance at the one end, the suture is carried up and brought out above the eyebrow at *c*. The other end of the suture is carried outward subcutaneously for 2 mm. from *a*, and then withdrawn at *b*. The needle is re-inserted at the same point *b* and brought out above, at *d*. It is then twisted over a gauze pad. The one suture is inserted at the inner third, and the second suture at the outer third of the lid.

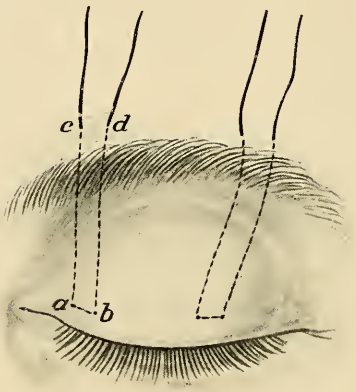

FIG. 65.—Pagenstecher's sutures.

Other Forms of Operation.—A number of other operations have been devised, which similarly depend for their success upon the union of the skin of the lid with the frontalis muscle. Panas' operation is the best known, but the deformity of the lid which follows this procedure has led to its general abandonment.

MOTAIS OPERATION.

This method consists in attaching a narrow tongue formed from the center of the superior rectus muscle to the upper border of the tarsus through an incision in the conjunctival surface of the everted lid. The operation was suggested by the synergic action of the levator and superior rectus in elevating the ball.

After thorough cocainizing of the conjunctival sac, the upper lid is everted and the convex tarsal margin is drawn upward by a hook, while the eyeball is rotated downward by a thread fixed in the conjunctiva near the upper limbus. This fully exposes the conjunctival

culdesac. The deeper tissues are rendered anesthetic by injections of 1 per cent. cocain-solution (one-half contents of Pravaz syringe).

An incision is now made through the conjunctiva over the in-

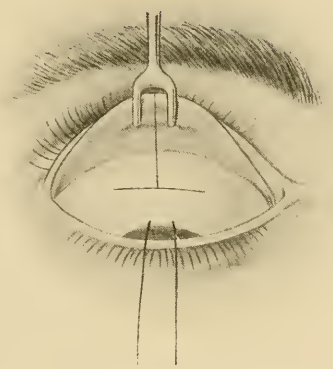

FIG. 66.—Motais operation. The upper lid is turned over and the convex border of the tarsus drawn upward by a double hook, so that the conjunctival fold is exposed. The horizontal and vertical lines designate the place of incision into the conjunctiva. The eye is drawn downward by a thread inserted at the upper limbus.

sertion of the superior rectus, beginning about 6 mm. back of the limbus and parallel to it for a length of 8 mm. From the center of this

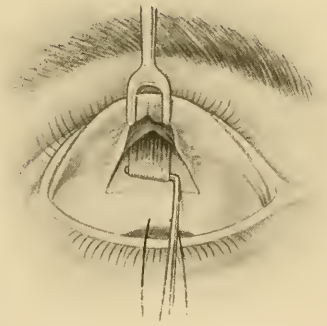

FIG. 67.—Motais operation. A strabismus hook is pushed beneath the insertion of the rectus superior.

opening a long conjunctival cut is made through the culdesac to the convex margin of the tarsus (Fig. 66). The straight strabismus hook is pushed beneath the tendon of the rectus muscle from within out-

ward, the tendon thoroughly exposed, and the eye drawn down by the assistant (Fig. 67).

The middle portion of the tendon is grasped with forceps, freed

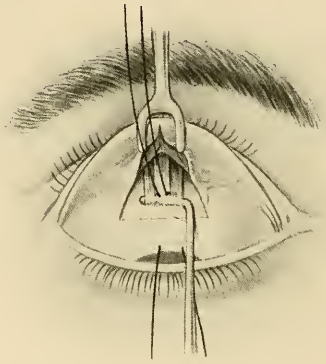

FIG. 68.—Motais operation. A thread-loop is placed through the middle portion of the muscle.

with a pair of closed scissors from bordering muscle fibers, and a curved strabismus hook is introduced beneath this portion. The two small, curved needles of a double-armed fine, strong silk ligature are

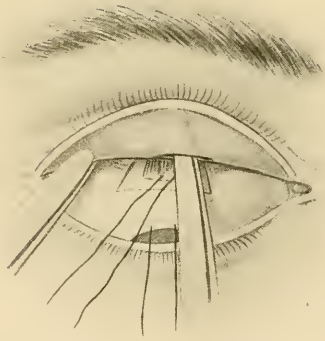

FIG. 69.—Motais operation. The scissors are brought to the anterior surface of the tarsus through a button-hole of the orbital fascia, and advanced to the lid-margin.

passed directly back of the insertion of the tendon from back to front through this muscle portion, and the ligature firmly tied (Fig. 68). The tissue included by the thread is severed with the scissors, and a

narrow tongue composed of the middle third of the tendon is isolated, and held at its free end by the ligature.

From the conjunctival cut at the convex margin of the tarsus (Fig. 66) two small lateral incisions are made, and the blunt-pointed scissors are introduced through this button-hole and passed along the anterior surface of the tarsus, dissecting a passage down to the free palpebral margin (Fig. 69).

Both needles of the thread are introduced through the button-hole above the tarsus, conducted downward between the skin and anterior surface of the tarsus, and passed through the skin about 2 mm. from the palpebral margin, the two needles separated a distance of about 4 mm.

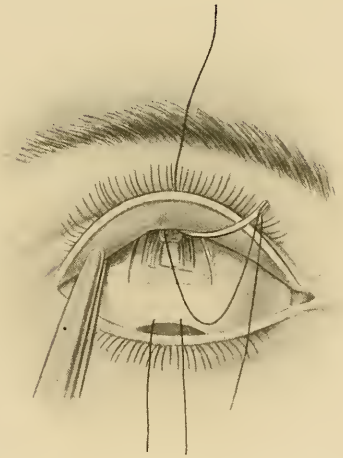

FIG. 70.—Motais operation. One end of the thread has been led through the skin above the cilia, the other is on the point of being pierced. The prepared muscular tongue already appears somewhat drawn upward toward the lid.

By carefully drawing upon the two threads equally, the tendinous tongue is made to pass between the tarsus and skin, with its end near the center of the lid-margin (Fig. 70). The threads are then tied over a bead or small gauze compress (Fig. 71).

The conjunctival wound is carefully closed with several catgut sutures, the suture in the conjunctiva at the culdesac being passed rather deeply to prevent prolapse of the fornix. Both eyes should be bandaged, and the dressing renewed daily. At the end of eight days the sutures are be removed.

The operation has the advantage of leaving no visible scar, and is

the only method that re-establishes the normal adjustment between the eyeball and upper lid in upward rotation. There is no lagging of the lid when the eye is directed upward. The operation, however, sometimes fails.

Complications.—Among the disadvantages claimed for the operation is a protrusion of orbital fat into the conjunctival wound, but this is remedied by care in closing the conjunctival incision.

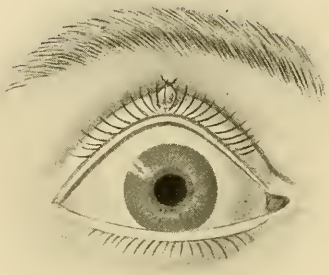

FIG. 71.—Motais operation. The thread is knotted over a bead. The lid is strongly drawn upward.

Corneal ulceration and staphyloma may follow the knotting of the threads on the conjunctival surface of the lid. As a certain amount of over-correction is necessary to the success of the operation, the lagophthalmus which arises, at least for a time immediately after the operation and particularly during sleep, may lead to injury of the cornea from exposure. The protective dressing employed by Hess after ptosis operation is the best preventive.

The weakness of the superior rectus muscle, and the double vision, which follow immediately after operation seem to be transient in most cases.

CHAPTER VIII.

THE EYE-MUSCLES.

In general, operations performed for manifest deviations of the eyes have only a cosmetic value. It is only when the squinting eye has good sight that a restoration of binocular vision is possible. Stereoscopic exercises should be instituted to support the effect of the operation by stimulating the fusion faculty and thus promote binocular fixation.

Preliminary Measures.—In the majority of cases of strabismus, particularly of the convergent variety, a high degree of refractive error exists, and this should be estimated after full relaxation of the accommodation under atropin, and glasses ordered to be worn constantly. The wearing of the glasses should be begun at as early an age as possible, as by their use the squint is often corrected or favorably modified. Operation is never indicated in young children until an accurate correction of the refraction has been made, glasses worn constantly for a considerable time, and the fusion faculty stimulated by stereoscopic exercises. In extremely young children, in whom the wearing of glasses is not feasible, the fixing eye is kept under the influence of atropin to prevent if possible amblyopia of the eye that deviates. In older children, in whom the squint is not fully corrected by glasses, systematic bandaging of the fixing eye is advisable.

Before performing a strabismus operation, two conditions should be investigated—the degree of deviation of the affected eye and the mobility of the eyes.

Anesthesia.—The most satisfactory results in strabismus operations are secured under local anesthesia, and it is therefore advisable to undertake operation only in patients who have reached an age when they can co-operate with the surgeon. As there is often a change in the squint as the child develops, early operation might lead to an over-effect in later years. It is only in isolated instances that ether will be required.

Tenotomy is usually performed under anesthesia of the conjunctival sac alone. In sensitive patients, or if the operator is inexper-

ienced, it will be advisable to make a subconjunctival injection of cocain immediately over the tendon of the muscle, employing $\frac{1}{3}$ c.c. of a 1 per cent. solution.

In the advancement operation, the conjunctival sac is first cocainized, followed by a subconjunctival injection of a 1 per cent. solution of cocain ($\frac{1}{2}$ c.c.). A fold of conjunctiva is lifted up over the tendon of the muscle, and the needle of the syringe introduced against the sclera and directed along the axis of the muscle. As the injection is being made, the needle is pushed farther in, in order to better anesthetize the deeper parts. The resultant swelling may be dispersed by slight massage.

CONVERGENT STRABISMUS.

The character of the operation to be performed will be influenced by the degree of deviation and the visual acuity of the two eyes—whether the eyes have nearly equal vision, so that the patient fixes alternately with one eye or the other (alternating squint), or one eye always fixes and the other squints (monocular squint). The general indications for operation may be summarized as follows:

Indications for Operation for Convergent Squint.—If the squinting eye is amblyopic, and vision less than $\frac{1}{10}$, the operations are preferably performed upon this eye, so far as the consideration for its mobility will allow; however, an operation upon the other eye is usually allowable.

In convergent strabismus of slight degree (maximum 15 degrees) tenotomy of the rectus internus of the squinting eye may be performed if the power of adduction is above normal. An examination of the new position of the eye must be made immediately after the operation to determine whether it is necessary to change the effect that the tenotomy has produced. If the tenotomy is succeeded by a marked diminution in the motive power of the rectus internus, all thought of immediate further interference must be abandoned, even though a convergent squint still remains.

Advancement of the rectus externus of one or both eyes is the operation of choice in (1) cases with diminished abducting power and (2) if the squinting eye has a vision of more than $\frac{1}{10}$. In moderate degrees of squint, advancement is performed only on one eye. In deviations exceeding 15 degrees, the external rectus of both eyes may be advanced at the same sitting. A permanent over-correction is

not to be feared, even though divergence exists immediately after operation. Both eyes must be bandaged for three to five days.

In high degrees of strabismus, with amblyopia of the squinting eye, a combination of advancement and tenotomy may be performed on the squinting eye, although, if the patient will consent to two separate operations, the tenotomy should be performed first, with supporting suture if required. Fully correcting lenses are to be worn, and at the end of several weeks the final result of the operation will be manifest. The advancement may then be performed, the amount of shortening varying with the degree of strabismus still existing.

Tenotomy of the Rectus Internus.—The operator, with a pair of toothed forceps in the left hand, raises a fold of the bulbar conjunctiva at a distance of 3 mm. from the limbus, and with slightly curved scissors makes a vertical incision, from 5 to 7 mm. long. The nasal border of the wound is then lifted up, the subconjunctival tissue severed and undermined by short cuts, and the closed forceps, held parallel to the sclera, introduced until they reach the insertion of the muscle (5 mm. from the limbus). They are then opened, pressed against the sclera, and the tendon is grasped. The forceps are now rotated into a position perpendicular to the sclera, and the tendon divided close to its insertion. In making this division, one blade of the scissors is pushed behind the tendon, as shown in the illustration (Fig. 72).

Not a particle of the tendon should remain adherent to the sclera, and after its separation only a slight ridge should mark the point of insertion. The muscle is immediately released, as pulling with the forceps is painful, the scissors laid aside, and a curved strabismus hook, taken in the left hand, is pushed into the wound, close to the sclera, and moved upward and downward in order to determine whether all of the tendon-fibers have been severed. Any fibers which have not been divided will offer a tense resistence to the hook when the latter is drawn forward. These fibers must also be separated close to the sclera. If the hook becomes caught in the capsule of Tenon, it pulls out a delicate membranous fold, which must not be mistaken for tendon-fibers. Incisions of Tenon's capsule are likely to produce undesirable results. After all the fibers are separated, the wound is closed with one or two catgut-sutures, which are introduced in a direction from above downward. While the needle is being passed through the conjunctiva the membrane should be firmly fixed with toothed forceps, and the needle held close against it, as pulling on the

conjunctiva will cause the patient unnecessary pain. In order to clearly see the position of the scissors the muscle is exposed in the illustration. In the patient, however, the muscle is covered with Tenon's capsule, and hence neither its upper nor lower margin is visible.

The manner of holding the instruments is the same whether the tenotomy is performed on the right or left eye. After the operation a slight dressing is applied, which may be removed the following day, or at most two or three days later.

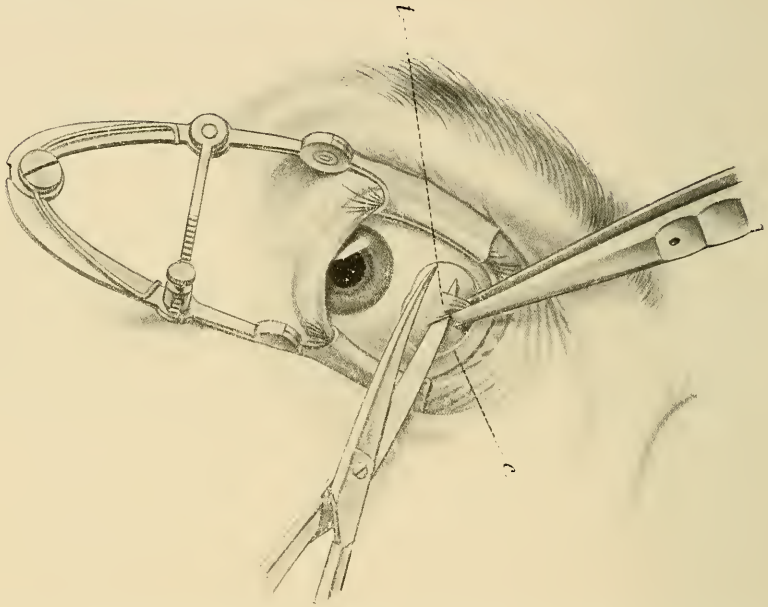

FIG. 72.—Tenotomy of the rectus internus. The eye is placed in the position of abduction. A small incision is made in the conjunctiva (c.). The forceps, after seizing the muscle, are held perpendicular to the curvature of the eyeball. One blade of the open scissors is introduced immediately behind the muscle at its insertion, the other blade lies in front of it. The tendon (t.) is severed at its insertion.

Accidents and Complications.—Among the unpleasant sequelæ that may follow a properly-performed tenotomy are widening of the palpebral fissure, protrusion of the eye, and retraction of the caruncle. Orbital cellulitis or tenonitis are extremely rare complications, and are the result of infection.

Hemorrhage.—A severe hemorrhage may follow tenotomy, and the blood passing backward beneath Tenon's capsule cause protrusion of the ball. A firm bandage should be applied, and in a few days the proptosis will subside.

Retraction of the Caruncle.—This may occasionally be observed immediately after the tenotomy, and is due to the retracted muscle stretching the fibers which pass from it to the caruncle, and causing sinking of the latter. Under these circumstances, the fibers should be divided by undermining the conjunctiva toward the caruncle with small clips of the scissors. This can also be done some time after the tenotomy through a freshly made opening in the conjunctiva.

Results of Tenotomy.—It is commonly believed that tenotomy of the rectus internus of one eye corrects to the extent of 15 degrees, but often there is produced decidedly less correction, sometimes even much less. And, while at times the final result of a tenotomy after the lapse of time shows little change in the degree of squint, in other cases the effect is unexpectedly great, so that the commonly given figures are far exceeded. This applies only to a correctly-performed tenotomy. It would not be suprising to find an enormous change in the position of the eye after extensive incisions of the conjunctiva, the subconjunctival tissue, and Tenon's capsule, or to get no result at all when some of the muscle-fibers were overlooked. But even in performing the operation in the most approved manner, the effect may be decidedly influenced, not only by pre-existing physiologic variations in the distance of the muscular insertion from the limbus, in the strength of the muscle, and in the relations of Tenon's capsule, but also, and sometimes to a considerable degree, by definite even though only slight variations in the degree of separation of the subconjunctival tissue and capsule resulting from the operation. The use of the strabismus hook to pick up the muscle causes considerably more tearing and disturbing of the relations of Tenon's capsule than follows seizing the muscle at its insertion with the forceps. It must also be remembered that the immediate effect of an operation may differ greatly from the more remote, permanent result.

Regulating the Effect Produced by Tenotomy.—It is, therefore, plain that the degree of correction after tenotomy of the rectus internus cannot be foretold with certainty. Even if the effect were definitely known in advance, there would still remain other perplexing problems. It would naturally be uncommon for the degree of a strabismus to correspond exactly with the degree of change in position produced by severance of the tendon. Therefore, the necessity for some means of regulating the effect of the strabismus operation is at once recognized. With such means at hand one does not need to know accurately in

advance how much effect the operation will have. Hence, for altering the effect of a tenotomy there are introduced what are termed supporting and counteracting sutures.

The Supporting Suture.—A short, moderately curved needle is inserted into the conjunctiva *close to the external limbus in the horizontal meridian.* In this situation the conjunctiva is firmly attached to the coats of the eye. If the suture is placed more externally only a fold of conjunctiva will be pulled forward by it, and it will be impossible for it to exert an appreciable influence upon the position of the eye; if introduced above or below the horizontal meridian, the rotating of the eye will occur on other axes, which would produce undesirable results. Firm anchorage of the suture is secured by introducing the needle twice, once immediately above and once just below the horizontal meridian. If the conjunctiva is easily lacerated, the needle should penetrate deeper in order to fasten the suture in the episcleral tissue. Both ends of the silk suture are then passed in the horizontal meridian through the external canthus out to the skin, while the outer angle of the eye is stretched between two fingers. The sutures are tied over a small gauze compress, and the operator is in a position to rotate the eye outward at will.

The application of the suture is naturally limited to those cases in which convergent strabismus still exists after the tenotomy but in which at the same time the loosened muscle is not too much limited in its efficiency. It is important after every tenotomy to determine at once the effect of the operation. This is done by having the patient, while still lying on the operating table, first fix with both eyes a point on the ceiling of the room, and then the operator's finger while it is moved toward him. The convergence-ability of the eye is thus determined, and, by laterally conducted movements, also the adduction-power of the severed muscle.

The suture should not be used if the muscle appears considerably weakened, even through there still remains some strabismus. As the suture rotates the eye outward, the insertion of the muscle will come to lie still further from the limbus than after a simple tenotomy, and through this the muscle will lose still more in power. If there is pronounced weakness of the muscle, a divergent squint will soon develop, owing to the marked preponderance in strength of the intact rectus externus.

In accordance with the rule always to be satisfied with a slight

under-correction in the operation for convergent squint when performing tenotomy, the eye should not be rotated outward to its greatest extent by means of the suture, although it is known that upon its removal the eye rolls inward again. At most, therefore, it is permissible to pull the suture sufficiently tight to produce a slightly divergent position. It is not necessary to allow the suture to remain for more than twenty-four hours. The final effect of the suture cannot be estimated accurately in degrees, as the eye usually rolls inward again to a slight extent. The influence of the supporting suture is closely related to the size of the incision into Tenon's capsule. Lateral incisions in the capsule, which are also recommended to increase the effect of tenotomy, must certainly be made to some extent in the performance of every tenotomy.

A great advantage lies in the possibility of introducing this suture one, two, or even three days after tenotomy. It happens occasionally that the correction produced by a tenotomy is entirely satisfactory immediately after the operation, but in the next few days, to the great astonishment of the operator, the effect diminishes considerably and the degree of strabismus is correspondingly increased. The suture is, therefore, the most certain means of reproducing the original result. After cocainizing and re-opening the conjunctival wound, a strabismus hook is employed to separate the fresh adhesions that have formed since the operation, after which the suture may usually be introduced with gratifying results.

Counteracting Suture.—This is introduced through the conjunctiva close to the internal limbus, in the same manner as described for the supporting suture at the external limbus. Should the conjunctiva tear, the thread is fixed in the superficial layers of the sclera. The assistant then raises the inner margin of the wound, and the surgeon introduces a hook forceps along the inner surface up to the adherent muscle. The latter is drawn forward slightly and pierced by the needle, which is then passed out through the wound margin of the conjunctiva. The other end of the suture is inserted in the same way, and the two ends are firmly tied. The eye is thereby rotated inward, so that the recently divided muscle with its tendon is again brought closer to the limbus, and thus gains in power.

The counteracting suture must invariably be employed if an over-correction has resulted from the tenotomy. If the eye shows a tendency to become divergent immediately after the division of the tendon,

and if the powers of adduction and convergence of the eye have been greatly interfered with by the operation, the omission of this suture would constitute a serious mistake. The highest grades of divergent squint may follow such unfortunate tenotomies. As in the case of the supporting suture, this counteracting suture may also be introduced one to three days after the tenotomy. It is only necessary first to break any existing adhesions by means of the strabismus hook. The suture is tied firmly so that it produces a slight convergence of the eye. The suture should be allowed to remain several days.

Advancement and Resection of the Rectus Externus.—Sufficient space is obtained by a short vertical incision through the conjunctiva, as in tenotomy, in addition to which a long horizontal incision is made, beginning at the middle of the first cut, and running backward. The wound is thoroughly undermined by small cuts with the scissors, after which the muscle is seized with the forceps, the eye rotated inward, and the muscle loosened from its bed by a few strokes with the point of the closed scissors, which is made to glide along its upper and lower margins. A straight strabismus hook is then passed beneath the muscle, either from above or below. If the point of the hook is covered by the conjunctiva or the capsule of Tenon, it must be freed, and the second strabismus hook introduced in the opposite direction. Muscle-fibers will frequently be caught by this hook which escaped the first one. If the muscle is not yet cleanly dissected, the overlying tissue must be separated with the scissors, the cutting always following the direction of the muscle, and not transversely, or the entire muscle or part of it may be severed, thus complicating the operation.

The Sutures.—While the sutures are being inserted, the assistant must stretch the muscle. This is effected by the anterior strabismus hook drawing the eye in a direction opposite to the action of the muscle, while the other strabismus hook is moved in the direction of the muscular contraction. The assistant should stretch the muscle only when desired by the operator, as the tension causes pain. A full curved, thin, flat needle, carrying a moderately thick silk thread, upon the strength of which we can rely with certainty, is passed from within outward through the muscle near its middle close to the posterior strabismus hook. Half of the suture is drawn through, and the needle is again passed in a like manner close to its previous point of entrance. The loop thus formed is made to firmly grasp the muscle-fibers. It

makes no difference whether the needle is first passed through the upper or lower half of the muscle. The other half of the muscle is then included in a loop of a second thread introduced at the same distance from the insertion of the tendon (Fig. 73). The ends of the suture containing the upper half of the muscle are laid upward, and those of the lower half downward, or a white and a black suture may be used in order that the wrong ends of the threads may not be tied.

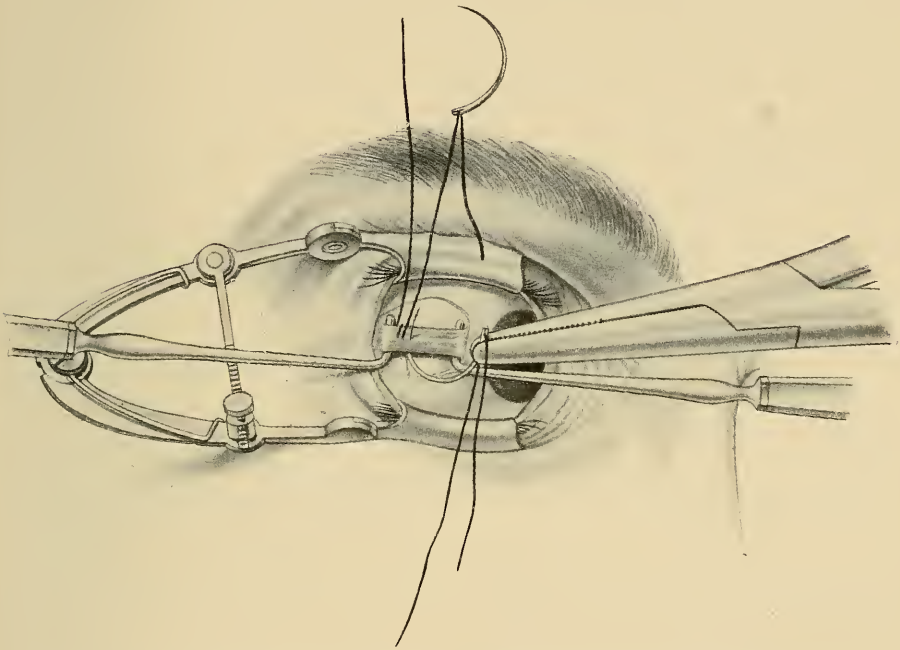

FIG. 73.—Advancement of rectus externus. The eye is placed in the position of adduction. The freed muscle is stretched over two strabismus hooks. The upper suture has already been pulled through; the lower suture is being introduced.

The operator now divides the muscle with one snip of the scissors, about 2 mm. in front of the threads; closer than this, the loops are liable to slip off. The stump of the muscle still adhering to the sclera is now removed close to the scleral surface, leaving only a short piece at one end of the insertion, to allow fixation of the eye with the forceps.

The shortened muscle must now be not only re-attached to the bulb, but fastened so that its influence is more strongly felt, *i.e.*, its insertion must be brought nearer to the limbus, hence the term:

advancement. For this purpose, the needle of either suture is passed near the limbus through the superficial layers of the sclera, the thread of the upper loop corresponding to the upper half of the original insertion, and *vice versa*. The sclera in front of the insertion must first be laid bare by separation of the conjunctiva, as the muscle naturally can only unite with a raw surface.

Scarification of the sclera near the limbus and wounding of the under surface of the muscle immediately back of the sutures will ensure

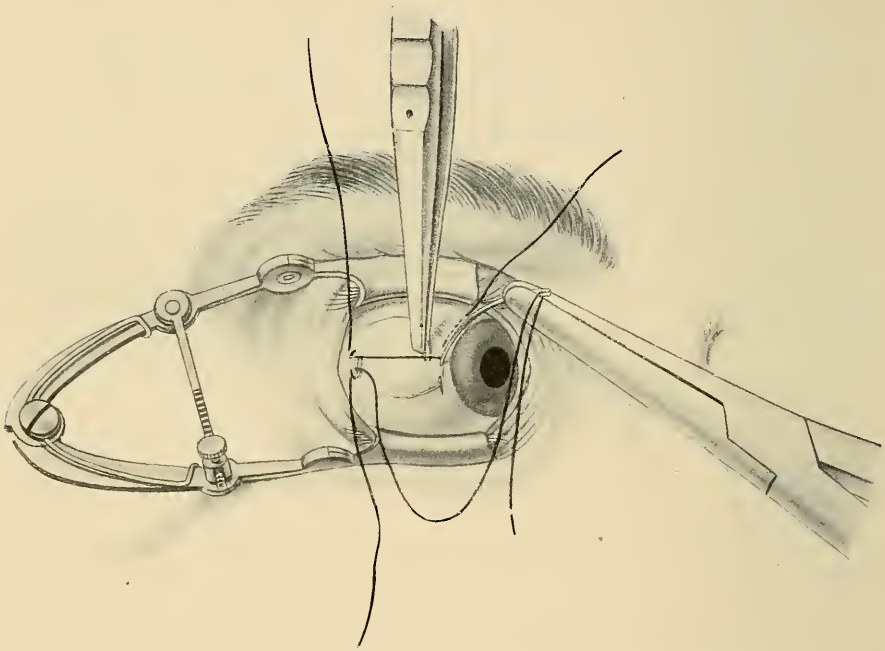

Fig. 74.—Advancement of the rectus externus. The muscle is divided; a piece excised; the eye is held fast by forceps applied to the stump of the tendon, which has been allowed to remain. The upper suture has already been drawn through the sclera near the limbus and also through the conjunctiva. The needle of the loose suture, which has been applied flat against the sclera, has already penetrated slightly the superficial lamellæ.

rapid adhesion of the two surfaces. A thin, flat needle is superior to those of triangular cross section, as the latter must be introduced deeply to prevent cutting through.

With a normally thick sclera there is no danger of perforating the bulb, if the needle is held parallel to the curvature of the sclera, so that only the most superficial layers are taken up. The needle point must not be placed vertically against the sclera in order to penetrate

its fibers. The only unpleasant feature is that the needle may be passed too superficially and cut through. If this happens, a fresh attempt must be made to catch some of the adjacent scleral fibers, a few of which are sufficiently strong to allow the operator to draw the eye, by means of the suture, in the direction of the muscle and to fasten the latter firmly to the globe. The attachment is made as close as possible to the limbus, but care should be taken that the pressure of the knotted thread does not injure the cornea. The needle should therefore pass through the sclera parallel to the limbus, *i.e.*, perpen-

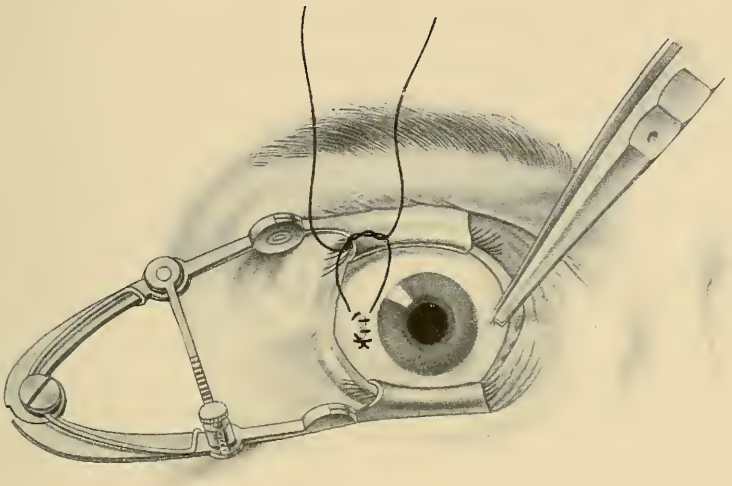

FIG. 75.—The operation is almost completed. The eye is rotated outward by the forceps, which are fastened at the inner side. The lower suture has already been tied; the upper has still to be pulled together. The conjunctiva covers the wound automatically.

dicular to the axis of the muscle, that of the superior suture brought from the horizontal meridian upward, while that of the inferior suture from the same point downward. Such a direction of the sutures has also the advantage of lying perpendicular to the direction of the scleral fibers (Fig. 74).

After the needle has been fixed into the sclera, it is passed a little further upward or downward through the conjunctiva. This affords not only an additional hold for the suture, if the attachment to the sclera is not sufficiently firm, but closes simultaneously the wound in the conjunctiva. Only one end of each suture is passed through the sclera.

The assistant then seizes with the forceps the eyeball at the oppo-

site limbus and rotates the bulb in the direction of the operated muscle, and each suture is drawn as tight as possible, a second knot being made over the first (Fig. 75). The sutures must be drawn firmly in order to be certain that the muscle has actually been brought forward to the limbus and fastened there. If the sutures have not been brought together properly, the muscle will be weakened rather than strengthened by the advancement.

If the conjunctiva is not completely closed by the advancement sutures, a separate thread is inserted horizontally. The threads are cut off short, and care exercised that they do not come in contact with the cornea. A dressing is applied to both eyes to prevent ocular movements that will disturb the recently sutured muscle. The operation is the same for either the rectus internus or externus.

After-treatment.—Both eyes should be kept closed for three to five days, but the dressing is changed on the day following the operation, in order to ascertain whether or not the cornea is uninjured. The sutures may be removed on the fifth or sixth day after the operation, but if a pronounced swelling of the conjunctiva prevents ready access to the knots, there is no objection to allowing the sutures to remain longer, as they can be removed later with much greater facility. The reaction of the conjunctiva to this operation is usually slight. The eye exhibits no irritation or pain, and in a short time there is only a slight thickening of the conjunctiva to mark the point of operative interference.

If the patient's sound eye cannot be bandaged (as in the case of ambulant patients, who must go home alone), it is advisable to keep the muscle at rest by introducing a suture through the conjunctiva close to the external limbus, and carrying the ends through the canthus to the external skin, where they are tied. In this way it becomes impossible to rotate the eye toward the side opposite to that of the advanced muscle.

Conjunctival Fixation of the Muscle.—While it is our custom to suture the muscle directly to the sclera, by passing the needle through its most superficial layers, it is proper to discuss here another method. This consists in passing one end of the upper suture upward beneath the conjunctiva along the limbus, going almost as far as the upper end of the vertical meridian, and, in a similar manner, one end of the inferior suture is passed beneath the conjunctiva as far as the lower end of the vertical meridian. In this way an attempt is made

to obtain sufficient hold for the muscle in the conjunctiva. When the sutures are tied, the muscle is, of course, drawn forward to the limbus, and must naturally split. On the other hand, the conjunctiva also yields to the tension, and is stretched in the direction of the tendon, obliquely across the cornea. Quite apart from the fact that this attachment is not dependable, on account of occasional friability of the conjunctiva, a greater objection is that the conjunctiva is tensely drawn in a fold across the cornea, and it can easily happen that the suture will come to lie upon the cornea, especially if it is not drawn sufficiently tight, a fact which may pass unnoticed by the operator, as the knot is covered by the conjunctiva. A corneal ulcer may be produced, and the operator is forced to remove the sutures at once, sacrificing the entire success of the advancement. Preference should be given therefore to the direct suturing to the sclera. The only contraindication to this would be a pathologically thinned sclera (ectasia).

Results of Advancement of the External Rectus.—The degree of correction secured by advancement of the external rectus must be even less certain than by tenotomy of the internus. So many factors are to be considered that variation in the results should occasion no surprise, as it is impossible to believe that each millimeter of excised muscle will produce exactly the same degree of correction in every case, or that a certain degree of strabismus will be overcome by the excision of so many millimeters of muscle in accordance with an inflexible rule. A change of 30 degrees in the position of the eye is the most that can be expected from an advancement of one externus; usually it is much less, and may be put down at 15 degrees at an average. The results of operation depend not only upon the excision of a piece of muscle, but also the suture of the tendon in front of the original point of attachment. The latter plays a more important part than the excision. If the operation is limited merely to the excision of part of the muscle, and the muscle again sutured to the original point of insertion, the effect of the operation will be slight. Of decided importance is the approaching of the new point of insertion of the muscle toward the limbus.

There is no danger of producing a permanent over-correction by performance of advancement alone, even in a convergent strabismus of no more than 15 degrees. The result immediately after the operation is at its maximum, and the effect usually diminishes considerably

in the near future. Therein lies an important contrast with the effect of a tenotomy. While an over-correction must be strictly avoided in the performance of tenotomy on account of the increasing degree of divergent strabismus that is inevitably produced, any over-correction that may occur during the performance of an advancement need not worry the operator. No increase in the divergence is to be expected; on the contrary, a retrogression is certain to follow.

Advancement of the Rectus Externus with Tenotomy of the Rectus Internus.—Incalculable and undesirable results may follow simultaneous advancement of the rectus externus and tenotomy of the rectus internus of one eye. Even though a considerable degree of convergent squint with good adduction-power of the eye remains after a tenotomy of the internal rectus, an immediate advancement of the rectus externus is an unwarranted procedure. The effect is often enormous, and a high degree of divergent strabismus may be the immediate result. As a result of the preliminary tenotomy, the advancement not only produces changes in the region of the external rectus, but also weakens the action of the internal rectus. Through advancement of the rectus externus the eye is rotated outward, and, owing to the lack of resistance on the part of the divided rectus internus, this rotation is greater than it would be with a normal internal rectus. The result is necessarily the same as that produced by a supporting suture. The rectus internus is drawn further away from its original point of insertion toward the equator of the eye, and loses correspondingly in its influence.

The simultaneous performance of tenotomy and advancement can be recommended only for the highest grades of convergent strabismus. Even in these cases the operation has to be limited to a resection of the muscle, and the suture made through the original point of insertion. If an over-correction is produced, it should by no means be allowed to remain, as the resulting divergent strabismus will rapidly increase in degree. It is necessary to introduce immediately a counteracting suture, which must be well buried in the superficial layers of the sclera at the internal limbus to prevent the thread from tearing out.

Bielschowsky employs a method of preventing over-correction without the counteracting suture, which is claimed to give satisfactory results. The usual advancement of the externus is performed, but the sutures are not at first tied. The conjunctiva above the internus is incised, the tendon and the surrounding fascia grasped with forceps,

and a fine silk suture passed through the tendon and the conjunctiva. The tendon is raised by the thread and severed from its attachment without disturbing its relations with Tenon's capsule. The needle is now carried through the edge of the cut conjunctiva near the inner limbus and a loose loop made of the two threads. The advancement sutures of the externus are now tied. The suture controlling the internus is then made sufficiently tight to ensure the desired effect.

Advancement Preferable to Tenotomy.—From a physiologic standpoint the operation of advancement without tenotomy must be given the preference. Advancement increases the motility of the eye, while the operated muscle is always weakened by tenotomy, as the tendon must reattach itself a greater distance from the limbus. Therefore, two fundamental rules are to be followed in tenotomy: (1) A muscle may be tenotomized only if the motility of the eye in the direction controlled by that muscle is abnormally great. Tenotomy is not to be performed if the muscle is of normal power, and particularly if its function is weakened. The motility of the eye must therefore be determined before any tenotomy is performed. Under normal conditions the internus should be able to adduct the vertical axis of the cornea to a line connecting the two puncta, and the maximum abduction to reach the commissure of the lids. If the adduction of the squinting eye is increased to the same degree as the abduction power is decreased, the squinting eye is presumed to have normal motility. A weakening of the internus from tenotomy is then contraindicated. If an excess of adduction is present in convergent strabismus, tenotomy may be performed provided the operation does not decrease the power of the muscle and bring it below the normal minimum. (2) Over-correction in tenotomy must never occur. This means not only manifest divergence, but particularly weakening the normal power of the muscle. Should the squint not be corrected by the tenotomy, no attempt should be made to increase the effect of the operation if the motility is lessened.

In convergent strabismus, if the defect in abduction is greater than the increase in adduction advancement is indicated.

Although particular emphasis is laid upon the superior value of advancement, this does not mean that an advancement must be performed under all circumstances; in fact, it cannot be denied that in many cases tenotomy is an indispensable operation.

DIVERGENT STRABISMUS.

The rule in operations for divergent strabismus is to produce an over-correction; but this result is not so easily attained. Advancement of the rectus internus is the only procedure which has any material influence on a divergent strabismus, but in itself an advancement of the rectus internus has not as much influence on the position of the eye as an advancement of the rectus externus.

This is due to two causes: (1) It is not possible to prepare and free as large a part of this muscle as in the case of the external rectus, and consequently the suture cannot be introduced as far back. (2) There is less room to advance the muscle, as the insertion of the tendon is normally near the limbus and cannot be brought much closer to it.

Similarly, a division of the external rectus has much less influence on the position of the eye than a tenotomy of the internal rectus. As the tendon insertion of the rectus externus is already further removed from the limbus, its shifting by means of a tenotomy will cause relatively much less loss in the influence of the muscle on the motility of the eye than is the case with the rectus internus. The value of the point of insertion grows in a rapidly increasing ratio as this point approaches the limbus.

Tenotomy of the Rectus Externus.—The incision through the conjunctiva is made slightly further from the limbus than in tenotomy of the internus, on account of the more remote insertion of the tendon of this muscle (7 mm. instead of 5 mm.). Otherwise, the technic of the operation is exactly the same.

Advancement of the Rectus Internus with Tenotomy of Rectus Externus.—In slight grades of divergent squint, both operations are usually performed simultaneously in order to obtain immediately after the operation an over-correction—a slight degree of convergent strabismus—as experience has shown that there is always a tendency toward a return to the divergent position. A tenotomy alone of the rectus externus has hardly any influence. In higher grades of divergent strabismus even the simultaneous performance of both operations is not sufficient.

If combined advancement and tenotomy has not corrected the deviation, a supporting suture may be inserted at the internal canthus similar to that described in tenotomy; or a suture may be passed through the bulbar conjunctiva, not too close to the external limbus,

carrying both ends out through the palpebral fissure toward the median line. By drawing firmly on the two threads, the eye is brought into a pronounced convergent position, one thread being drawn upward to the median line of the forehead, and the other over the bridge of the nose to the other side of that organ, in which positions both threads are fastened with several strips of plaster. A small piece of absorbent cotton is placed beneath the lower thread, so that it does not cut into the bridge of the nose. As the eye cannot be completely closed, it should be covered with a piece of oiled paper. The suture may be removed on the following day. The cornea will not be injured by the suture, especially if it has been introduced a short distance externally to the limbus, so that it raises a small fold of the conjunctiva. If the divergent position is not yet corrected, operation on the muscles of the other eye is indicated.

Divergent Strabismus Caused by Tenotomy of the Rectus Internus.—If the divergent strabismus is the result of a tenotomy of the rectus internus that has been performed for convergent strabismus, an advancement of the rectus internus usually produces an excellent result. The preparation of the muscle, however, is somewhat difficult, as it is often attached far back from the limbus. It is scarcely possible to excise a part of the muscle, as there is only sufficient room to introduce the sutures. Nevertheless, the result is good, as the point of insertion can be brought forward a considerable distance.

After an over-correction of convergent strabismus by tenotomy of the rectus internus, the operator must be warned against undertaking an advancement of this muscle within a few days after the tenotomy. The only course that can be pursued is to introduce the counteracting suture. As the muscle can often be scarcely found in the congested and somewhat swollen tissue, an advancement according to exact rules is extraordinarily difficult, and the procedure in addition is painful to the patient in spite of the cocain-injection. Under these circumstances if the suture has not had the desired effect, it is much better to wait until the eye has recovered, and several weeks later undertake the advancement. An unsuccessful attempt at advancement may render the condition even worse.

Latent Outward Deviation (Exophoria).—Although the principal indication for advancement of the rectus internus is manifest divergent squint, the operation must also be performed in exophoria, in which asthenopic symptoms, such as fatigue and variable diplopia,

arise even during use of the eyes at distance, provided, of course, that these symptoms cannot be remedied by use of prisms. As the extreme correction possible from an advancement of the rectus internus of one eye is about 15 degrees, the operator must be governed in doing this operation by the degree of exophoria. If the heterophoria is slight, the operation should be confined to a simple advancement without excision, or with excision of a short piece of the muscle. It is desirable that the patient should show immediately after the operation a slight convergence when looking into the distance. If binocular vision existed before the operation, the convergence will soon disappear under the influence of the fusion-tendency. When a carefully performed advancement of one internus does not relieve the patient of the exophoria and its accompanying symptoms, a similar advancement of the rectus internus of the other eye may be undertaken after the lapse of a few weeks.

The greater proportion of cases of exophoria are due to convergence weakness, but in some instances the defect is the result of excess of divergence power, in which tenotomy of the externus would be the procedure indicated.

Paralytic Squint.—Operative interference is only indicated if it is decided that the paralysis is permanent and has been present for at least nine to twelve months. An effect upon the mobility of the eye can be promised from the advancement only in cases of partial paralysis of the muscle. In total paralysis no influence can be exerted on the motility, and the operation is performed rather with the idea of returning the paralyzed eye to its normal position.

CHAPTER IX.

ENUCLEATION OF THE EYEBALL AND THE SUBSTITUTE OPERATIONS.

Indications.—Enucleation, or one of the operations which may be substituted for it, is to be performed:

1. When the visual power of the eye is *irretrievably lost*, and the eye is painful.

2. When the sound eye is seriously endangered by a *sympathetic affection.*

3. When the eye contains a malignant growth.

Therefore, every painful blind eye should be enucleated. The presence of an intraocular tumor is indication for enucleation, although the eye may still be functionating. If after an injury iridocyclitis develops, enucleation is not performed until both light-perception and light-projection have become greatly reduced, and sympathetic inflammation is feared.

Extensive ruptures of the cornea and sclera, with prolapse of the iris and vitreous, justify immediate removal of the globe. Prompt action spares the patient weeks and months of suffering. After extensive injuries the gaping wound may be sutured before the enucleation, to prevent involuntary expulsion of the ocular contents.

Ruptures of the sclera require enucleation much less frequently. Even though the visual power is usually either entirely ruined or returns only partly, such eyes can later become absolutely quiescent, and often do not become disfigured. Not until the globe begins to shrink and becomes painful and injected should enucleation be performed, but then, however, without delay. Enucleation is not justified simply because the light-perception of the eye is completely destroyed by an injury that does not rupture the globe. Not infrequently, immediately after a contusion, the light-perception is completely lost, but both perception and projection return gradually and may even reach normal. We have seen such eyes which, from a condition of absolute amaurosis, have regained partial visual acuity.

Enucleation is indicated in high degrees of ectasia (total staphyloma of the cornea and staphyloma of the sclera) which are disfiguring because of their size, and are in danger of rupture, resulting in serious hemorrhage.

Enucleation is indicated when panophthalmitis is developing. For example, if, after an injury which in itself was not considered sufficient indication to perform an enucleation, the eyeball becomes infected, and this infection is rapidly progressive and makes a panophthalmitis probable, we check the process by enucleation of the eyeball.

Enucleation is also demanded if the eye becomes seriously infected after operative interference, as, for instance, a cataract operation. If, however, the panophthalmitis has already developed, as evidenced by exophthalmos, marked edema of the lids, limitations of the movements of the eyeball, and chemosis, enucleation is contraindicated, as experience has shown repeatedly that meningitis may follow removal of the eyeball. The proper procedure is to open the anterior portion of the eyeball to permit the free drainage of the pus and thus furnish the patient relief, or to perform evisceration.

Substitute Operations.—The following operations may be employed as substitutes for enucleation:

1. Abscission of the cornea.
2. Evisceration.
3. Evisceration, with the insertion of a glass or metal sphere in the scleral cavity (Mules' operation).
4. Implantation of a glass or metal sphere in Tenon's capsule after removal of the eyeball (Frost-Lang operation). Recently fat has been employed instead of the glass or metal sphere (Barraquez).
5. Optico-ciliary neurotomy and neurectomy.

Local Anesthesia.—Removal of the eyeball is most frequently performed under general anesthesia, but instillations of cocain in the conjunctival culdesac, supplemented by injections beneath the conjunctiva into Tenon's capsule and into the neighborhood of the optic nerve, have been employed in persons of advanced years or in those to whom ether is objectionable or dangerous. Elschnig's ganglion anesthesia is superior to other methods of local anesthesia, and permits the removal of even sensitive eyeballs with almost complete absence of pain. The following description had been prepared by Löwenstein, the assistant of Elschnig.

Ganglion Anesthesia.—The ciliary ganglion is situated poster-

iorly in the orbit in the angle between the optic nerve and the external rectus muscle. An injection made in the vicinity of the ganglion influences the sensibility of all the nerves of the globe. A 1 per cent. solution of cocain is employed, and is injected with the ordinary Pravez syringe, which is supplied with a sharp needle 5 cm. long and correspondingly thick. The conjunctival culdesac is first rendered anesthetic with several instillations of a 3 per cent. cocain-solution, the commissure stretched outwards, and the needle of the syringe entered close to the external orbital margin, slightly below the center, along the inferior margin of the external rectus, and pushed obliquely

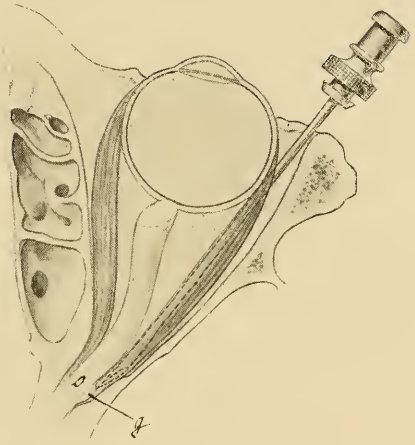

FIG. 76.—Horizontal section through the orbit, showing position of the needle; *o.*, optic nerve; g., ciliary ganglion.

inward toward the median line until not more than $\frac{1}{2}$ cm. remains visible (Fig. 76). The barrel of the syringe is now turned slightly outward, so that the needle point is raised away from the external orbital wall, and one-half of the contents of the syringe injected. If the needle has reached the proper situation, there is some sensitiveness on pressing the globe with the forceps in tender and inflamed eyes, but the pain gradually disappears. At the expiration of a few seconds the remainder of the contents of the syringe is injected at the same place.

Since the external orbital wall runs obliquely inward, care must be exercised in thrusting the needle forward to direct the point toward the median line and thereby escape the bone. The needle must not

be pushed too near the apex, or the optic nerve will be penetrated. By a lateral movement of the syringe it is readily determined if the needle point is free or caught in the optic nerve or a large vessel.

If the eye has been inflamed for a long time, it is advisable to make a subconjunctival injection of another half syringeful of the solution around the globe before beginning operation.

If the sensibility of the eye has not been affected by the injection of the first half of the contents of the syringe, the needle is drawn out for a short distance and pushed forward in a slightly altered position to reach the ganglion.

In timid and excitable patients a preliminary subcutaneous injection of scopolamin and morphin is of value.

Exceptionally the ganglion is not reached by the injection, and general anesthesia will be necessary to permit the operation to be performed without pain.

Rapid protrusion of the eye, with severe pain immediately after injection, probably caused by hemorrhage, is a rare complication. The danger of hemorrhage and of injury to the optic nerve necessitates the limitation of this method of anesthesia to enucleation. It cannot be applied to intraocular operations even in blind eyes.

Enucleation.—The first step of the operation is to separate the conjunctiva from the eyeball. A fold of the bulbar conjunctiva is picked up with a pair of toothed forceps in the horizontal meridian near the limbus, and a small incision is made into it close to its attachment. Not a particle of conjunctiva should remain on the bulb, as every millimeter is of the greatest importance for the wearing of a prothesis.

Separation of the Conjunctiva (Fig. 77).—The blunt blade of the small, slightly curved scissors is inserted into the opening made at the limbus, and pushed forward beneath the neighboring conjunctiva, while the other blade remains in front of the cornea. The blades must be held parallel to the limbus. The scissors are then closed, thus separating the conjunctiva from its attachment at the limbus. This is continued, the conjunctiva being picked up with forceps at the end of the incision, and the scissors being pushed forward until the conjunctiva is loosened completely at the limbus. As a right-handed operator always cuts from right to left, the detachment of the conjunctiva in the case of the right eye should begin on the inner side; in the case of the left eye, on the outer side of the corneal limbus.

The lower periphery is separated first, and then the upper, so as not to be disturbed by the blood. After the conjunctiva has been cut all the way around, it is undermined with closed scissors on all sides, in order to completely detach it from the eyeball.

Dividing the Muscles.—The tendon of the internal rectus is the first to be divided on the right eye; the tendon of the external rectus, on the left eye. The tendon is picked up with the toothed forceps as in tenotomy (p. 103), and, while the assistant slightly lifts the conjunctiva in front of the muscle, the operator, having scissors ready in his right hand, pushes the shut forceps held in

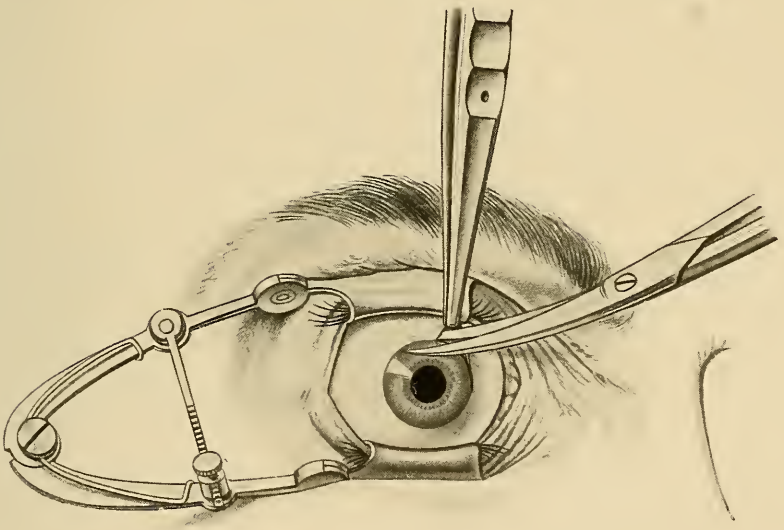

FIG. 77.—Enucleation of the right eye. Division of the conjunctiva has advanced to the vertical meridian. Note the position of the scissors: one of the blades is pushed forward beneath the conjunctiva, the forceps at the same time lifting the margin of the conjunctival wound somewhat; the other blade of the opened scissors is placed in front of the cornea in such a manner that by shutting the instrument the conjunctiva is separated close to the limbus.

his left hand, back along the sclera close to the attachment of the muscle, where he opens them and grasps the muscle by pressing the forceps against the sclera. The final detachment of the tendon from the sclera is not completed as in tenotomy, but the muscle is cut through at the side of the forceps, away from the eyeball, by pushing the blunt blade of the scissors under the muscle-tendon from beneath and cutting through it obliquely, so that a short piece remains

attached to the eye, by which the globe is held during the subsequent stages of the operation (Fig. 78). The tenotomy opens Tenon's capsule and exposes the sclera. The small, slightly curved scissors, employed for the division of the conjunctiva and the tendon, are now replaced by a somewhat larger and stronger pair, which may be either straight or slightly curved, the enucleation-scissors.

The eyeball, which is held throughout by the stump of the muscle-tendon, is rotated in a horizontal direction toward the side opposite the

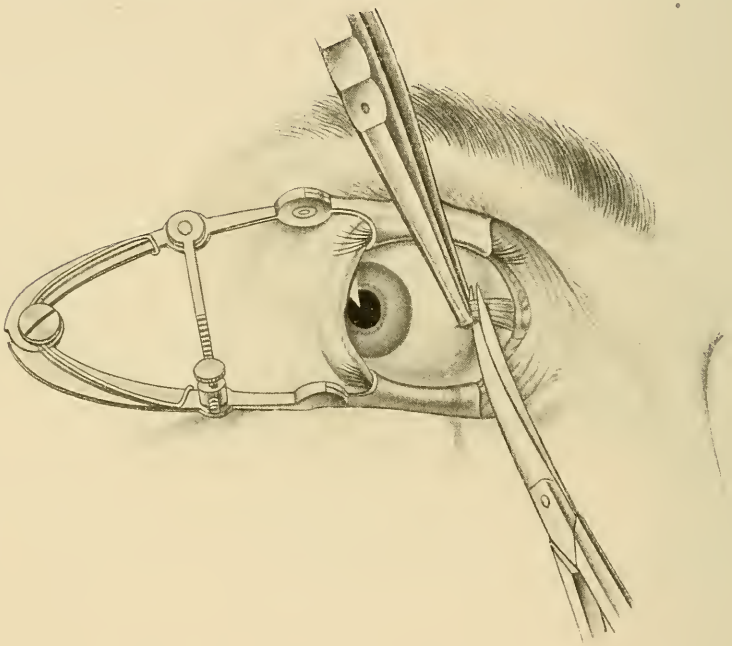

Fig. 78.—The forceps have grasped the internal rectus at its attachment, and have turned the eye outward; one blade of the scissors is pushed under the muscle to the inner side of the forceps to cut through it vertically to the direction of its fibers.

cut muscle (*i.e.*, the right eye outward, and the left eye inward), and the scissors inserted into the opening in Tenon's capsule, which is found by pressing the blunt blade of the opened scissors against the bared sclera and pushing it from here upward under the capsule. In this way the blade glides under the tendon of the superior rectus (Fig. 79). The muscle is recognized by the marked resistance which it offers the scissors. The eyeball is next pressed forward with the aid of the scissors, so that the tendon of the muscle is exposed, when it is cut off close to its

insertion with one snip of the scissors. The tendon of the inferior rectus is next severed by similar fixation and position of the eyeball, excepting that the operating hand must be held perpendicularly. In the same manner, the blunt blade of the scissors glides beneath the capsule of Tenon, lifts up the tendon of the inferior rectus, so it can be seen on the scissors, and cuts it.

Cutting the Optic Nerve.—The tendon of the fourth straight eye-muscle is not divided until after the severance of the optic nerve. While the eyeball is held rotated to the right, the closed enucleation-scissors are pushed along the sclera slowly to the posterior pole of the eye (Fig. 80). Inasmuch as the optic nerve of the right eye is approached from the inner side, it is more easily reached than the left eye, where the ad-

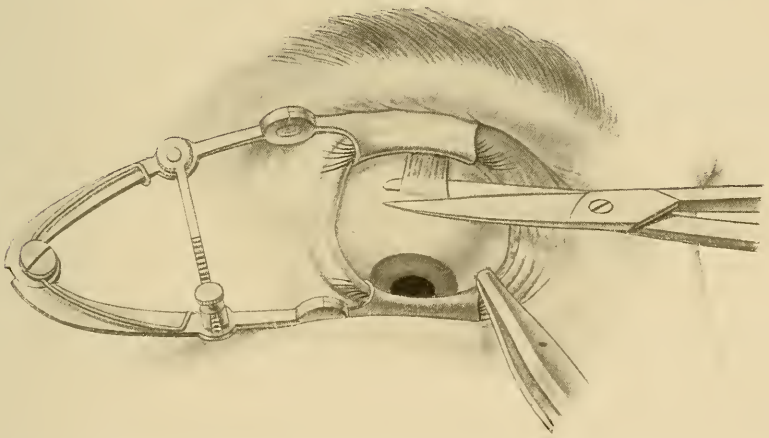

FIG. 79.—The forceps pull the eye downward with the tendinous stump of the rectus internus, while the blunt blade of the enucleation-scissors is pushed from the inner side under Tenon's capsule, until it reaches the superior rectus, which it now cut off close to its insertion.

vance is made from the outer side, and consequently the posterior pole must be passed before the nasal side of the bulb is reached. The beginner often has difficulty in locating the optic nerve. This is the result of a wrong position of the scissors, which must not be directed backward toward the depth of the orbit, but introduced close to the sclera in an approximately frontal direction, about vertically to the course of the optic nerve. If the eyeball is rotated about its vertical axis to the right, and the closed scissors held to the horizontal meridian against the sclera, and moved from above downward, the optic nerve can be made out as a tightly stretched cord. The finding of the optic nerve may be facilitated

by drawing the eye slightly out of the orbit in order to stretch the nerve. Ordinarily the nerve should be severed close to the bulb. After having ascertained its position, the scissors are opened, the operator feels around once more to make sure that the nerve is between the two blades, and then divides it with one cut. The loosened bulb is immediately pressed forward with the closed scissors, and turned out from the orbit, so that the assistant may check the bleeding with a tampon of dry gauze firmly packed in the bottom of the opening, and prevent any suffusion into the orbit.

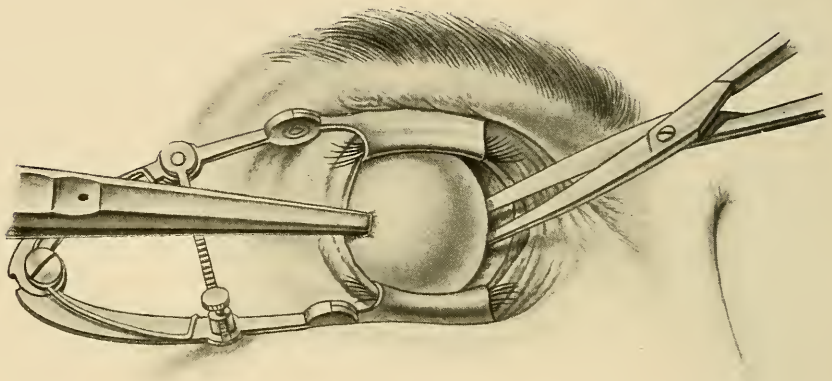

FIG. 80.—The eye, which is still held fast at the same point, is strongly turned outward exactly around its vertical meridian. The opened enucleation-scissors have the optic nerve between their blades ready to cut through it.

Removing the Eyeball.—Nothing remains now except to free the bulb from its remaining attachments, which consist of the tendons of both oblique muscles and of the fourth rectus, and these are cut through with the scissors close to the bulb. If the enucleation has been properly performed, no large tissue-remnants should remain on the eyeball with the exception of the stump, by which the bulb is held.

Closing the Conjunctival Wound.—The wound in the conjunctiva may be closed either with a purse-string suture or with several vertical sutures. If the latter are employed, it is important to draw both threads through near the border of the wound, so that no shortening of the conjunctival sac may be produced by the central margin of the conjunctiva projecting inward in the form of a roll.

Many operators believe that a more movable stump for the prothesis is secured by suturing the four straight muscles to the conjunctiva

and by bringing the edges of the wound in the conjunctiva and Tenon's capsule together with interrupted silk sutures. We have not followed the plan of suturing the muscles, and believe that is is not necessary to close the conjunctiva with sutures, as the membrane will, of itself, assume the best and most suitable position, and the wound will heal in a few days. Moderate compression should be employed in the dressing in order to prevent secondary hemorrhage. On the day after the operation the bandage is changed and a light pad worn for several days. The conjunctival sac is cleansed with a weak bichlorid solution.

Complications.—The enucleation does not always proceed as smoothly as described, and for the beginner it is no easy operation. Difficulties may be encountered during the separation of the conjunctiva. If the eye has been inflamed for a long time, adhesions frequently exist between the conjunctiva and the sclera, particularly if subconjunctival injections of solutions of mercuric chlorid or sodium chlorid have been repeatedly made, or, after injuries, destructive processess have led to cicatricial fusion between conjunctiva and sclera. The loosening of the conjunctiva may become impossible after the action of corrosives, when, in place of the conjunctiva, only a small layer of scar-tissue remains, thin and easily perforated. The conjunctiva must be preserved as much as possible, and not torn by unnecessary handling of the toothed forceps. The severing of the muscles is made easier for the beginner if he searches for them with the strabismus-hook. The operator, however, who pushes the scissors beneath Tenon's capsule, after the manner described, finds that this method has the advantage of greater rapidity, but he must be careful while cutting the tendons of the superior and inferior recti not to injure the lid by a snip of the scissors. During the entire operation the lids must be held apart by a lid-speculum.

Tearing Off of the Muscle Stump.—Should the muscle stump, by means of which the eyeball is handled, break or tear off from repeated seizures with forceps, the tendon of another muscle must be grasped, or, if the eye is soft, a fold of the sclera may be picked up. If all the tendons have been cut close off, the index and middle fingers of the left hand must be used to hold the bulb in the desired position in order to cut through the nerve, or the ball held by a suture through the sclera. The closer to the eyeball the tendon is grasped, and the less frequently the forceps are applied, the more firmly will the tendon hold.

Orbital Hemorrhage.—The most difficult part of the operation for the beginner is the division of the optic nerve. The nerve may be easily found by slow groping about with the closed scissors, but should the eye be inclined in an oblique direction, and the operator hastily make a cut anywhere backward in the orbit, he will not succeed in dividing the nerve. This blind cutting leads to a profuse hemorrhage into the orbit, which cannot be stopped by inserting a tampon so long as the bulb remains in place. The infiltration may become so extensive that the tissue of the orbit is bulged forward like a tumor, and weeks may elapse before the blood will become absorbed. An attempt should be made to cut the optic nerve with the first stroke. It is rare, however, for the hemorrhage to be profuse. If energetic compression does not suffice to check the bleeding, ligation of the blood-vessels must be resorted to, or even the Paquelin cautery used. Secondary hemorrhage is rare, and is treated by removing the bandage and packing the orbit.

Perforation of the Sclera.—After division of the optic nerve the eyeball must at once be displaced forward, so that the tampon may be inserted. It is unpleasant if the operator, instead of severing the nerve, cuts into the posterior part of the bulb itself. This may happen after severe injuries which have induced a complete collapse of the bulb, or if the globe has ruptured when the muscles were severed. It becomes necessary then to search for the nerve, while still holding the stump of the bulb, and resect it. As the surrounding orbital tissue becomes much swollen from effusion of blood, it is difficult to dissect and free the optic nerve so as to divide it further back. The bearings to its position are lost, and the profuse bleeding prevents a clear view.

Injury to the levator palpebræ can only occur if the position in which the eyeball is held or the direction of the cutting is extremely faulty. Cases of total ptosis have been reported after enucleation.

Resection of the optic nerve must be done if, during enucleation because of a malignant growth, the stump of the nerve is found involved by the tumor. The nerve should be cut as far back of the bulb as possible; but if it is assuredly affected, exenteration of the orbit (p. 131) is a safer procedure than resection of the nerve. In iridocyclitis following injuries, in which sympathetic inflammation threatens, as much of the nerve as possible should be resected.

Abscission (Complete Keratectomy).—Excision of the entire

cornea, and closure of the edges of the scleral opening with sutures, is performed in non-inflamed staphylomatous eyes, especially in children. The operation, however, is not free from the dangers of sympathetic inflammation. (See page 245.)

Evisceration.—Evacuation of the contents of the eyeball, without removing the sclera and its attachments, is indicated in panophthalmitis. The operation consists of excision of the entire cornea, the evacuation of the contents of the scleral cavity, and swabbing the interior with antiseptic solution or, as some advise, carbolic acid.

Evisceration, with Insertion of a Globe in the Sclera (Mules' Operation).—Although Mules' operation has many advocates who regard it as of especial value from a cosmetic standpoint in (1) recently injured eyeballs, (2) in eyes painful and blind from glaucoma, and (3) when only the cornea is diseased, this operation is not performed in our clinic. Cases of sympathetic inflammation have repeatedly been observed. The expulsion of the sewed-in balls occurs frequently, sometimes even after years have passed. This may be accompanied by symptoms of inflammation, which may require operative interference, such as the shelling out of the ball; in fact, subsequent enucleation of the stump may be necessary.

Enucleation, with Implantation of a Globe in Tenon's Capsule (Frost-Lang Operation).—It is claimed for this operation that it gives a more movable stump for the prothesis, lessens the tendency to sinking of the upper eyelid, and is free from the risks of sympathetic disease. The artificial sphere, either glass or gold, is inserted into Tenon's capsule after the eyeball has been removed and hemorrhage stopped. The edges of the capsule are brought together horizontally over the ball by a number of fine silk sutures, and the conjunctival wound is then sutured, also in the horizontal direction, and the usual bandage applied. The reaction after operation is usually no greater than follows enucleation. Although this operation has not been performed in our clinic, excellent results are reported by other surgeons, and the procedure is therefore briefly mentioned as one of the substitutes for enucleation.

Enucleation, with Implantation of Fat in Tenon's Capsule (Barraquez Operation).—The operation differs from ordinary enucleation in the passing of a double-armed catgut suture through the divided ends of the four recti muscles. A piece of fat sufficiently large to fill the cavity of Tenon's capsule is removed from the

abdominal wall, inserted into the capsular cavity, and the recti united crosswise over it. The edges of the capsule are then sutured with catgut and the conjunctiva with silk. Protruding pieces of fat must be carefully cut away before the conjunctival wound is closed.

Lauber recommends that the skin incision of the abdomen be rectangular, with one side in the linea alba. In from eight to ten days the conjunctival sutures are removed, and the prothesis worn at the end of about three weeks. It is claimed that the implanted fat forms an excellent support for the artificial eye, although in time it gradually decreases in volume.

Optico-Ciliary Neurotomy.—An eye blinded by glaucoma which has become painful furnishes a suitable indication for optico-ciliary neurotomy. As the eye is not disfiguring, it is more desirable that the owner retain it than replace it with an artificial eye, the use of which is associated with many inconveniences. The operation is rarely indicated if the eye has become blind through a spontaneous iridocyclitis—one not induced by injury—and causes the patient pain. The eyes are generally shrunken and disfiguring, so that enucleation must be recommended. If an injury has preceded, enucleation must of necessity be performed, as an optico-ciliary neurotomy would not prevent a sympathetic inflammation. When an intraocular tumor is suspected, enucleation is peremptory.

The operation is done under general anesthesia. The rectus internus is freed as in an operation for advancement, and a suture is passed through the muscle at a distance of about $\frac{3}{4}$ cm. from its attachment, then tied, and given to the assistant to hold, after which the muscle is divided between its insertion and the knot. The assistant pulls the muscle away from the eye by means of the suture, the operator using the stump, which remains attached to the eye, to fix the bulb. As in enucleation, the scissors are passed slowly backward along the sclera, and the optic nerve divided. The scissors are withdrawn and strong pressure maintained on the bulb through the closed lids for five minutes to prevent a hemorrhage into the orbit. Without this compression the bleeding may push the loose eye through the palpebral fissure at once, or it may be found out of the orbit on the next day. As a reposition is impossible, nothing remains but enucleation. Extensive hemorrhage may occur in the aged from arteriosclerosis, in spite of firm compression.

As the ciliary nerves were not divided at the severing of the optic

nerve, the eye is turned on its vertical axis so that the posterior surface of the eyeball lies free in the palpebral fissure, and the ciliary nerves cut that pass through the sclera in the neighborhood of the optic nerve, the greater number of which have already been torn during the turning of the eyeball. If a long piece of the optic nerve remains attached on the eyeball, a part of it may be resected (neurectomy). The eyeball is then replaced in its normal position, the muscle carefully sutured to the stump to insure its normal motility, the conjunctival opening closed with sutures, and a firm pressure-bandage applied over the closed lids. Usually, healing progresses without incident. The slight amount of exophthalmos after the operation, because of the hemorrhage, disappears within a short time.

If the operation has been successful, the cornea is perfectly anesthetic and the eyeball free from pain. The sensitiveness of the cornea returns very slowly. A neuroparalytic keratitis is not to be feared. Over the fundus the blood-vessels are seen to be absolutely empty, appearing as white lines, and the papilla is a pure white. The tension of the bulb remains normal, sometimes even greater than normal. Atrophy of the eyeball does not develop.

Exenteration of the Orbital Cavity.—The removal of all the contents of the orbit for the extirpation of malignant neoplasms, whether of the orbit itself or of the eyeball after they have broken through the sclera, is performed as follows:

If the lids are to be preserved, the palpebral fissure must first be widened by canthotomy; this exposes the outer border of the orbit. Next, the conjunctiva of the lower fornix is cut through with a sharp scalpel to the bony lower border of the orbit, which is thus completely bared. The assistant draws the lid away with a dull tenaculum. The upper conjunctival fornix is then cut through in the same manner, along the upper orbital margin. To the inner side both incisions meet at the front part of the lachrymal bone. Both lids can now be easily drawn away from each other with tenacula, so that the entire orbital border is exposed. The periosteum is incised along the bony margin of the orbit, and, by means of a periosteal elevator or closed, somewhat curved, scissors, pushed between bone and periosteum, the entire contents of the orbit are shelled out with great rapidity on all sides as far as the posterior end of the orbit. Only at the inferior orbital fissure and at the posterior crest need we make use of the scissors to divide the fascial strands. With proper care we can easily avoid injuring

the thin bones of the orbit. Finally the entire mass is divided as far back as possible by several snips of the scissors. Energetic tamponing prevents serious hemorrhage, and we are rarely forced to use the cautery. The orbital cavity is now tightly packed, gauze is pushed beneath the lids so that they will not fall into the orbit, and a pressure-dressing applied. A long time ensues before the wound of the orbit begins to be covered with granulations, and several weeks pass before the entire cavity has become filled. During this time it must be kept loosely packed.

In the end, however, the lid is always drawn far back by scar-tissue, and the use of an artificial eye is not possible. The palpebral conjunctiva may even become a burden to the patient on account of its secretion and, therefore, nothing is lost if in the exenteration of the orbit the lids are also removed. Such an operation is easier, and the large wound in the skin can be so diminished by a few vertical sutures that only the normal width of the palpebral fissure remains.

CHAPTER X.

CATARACT.

Operation for cataract may be conveniently considered under the following heads: (1) Extraction of senile cataract, (*a*) with iridectomy (combined extraction), (*b*) without iridectomy (simple extraction), and (*c*) extraction in capsule; (2) removal of soft cataract, (*a*) by discission, and (*b*) by linear extraction; (3) discission of secondary cataract. [1]

General Considerations.—If a patient is enjoying usual health, extreme old age and the senile changes associated with advanced years are not contraindications to the removal of a cataractous lens. As a routine practice a general systemic examination is made to enable the operator to correct any ailment that may exist and which might influence the success of the operation, and to prepare him to meet any complication that might arise during the after-treatment. If the patient has not been under observation during the incipiency of the cataract, so that the condition of the interior of the eye is known, a test is made with a lighted candle to determine that the recognition of light is preserved in all portions of the field.

Before arranging for operation examination of the conjunctival cul-desac is to be carefully made for hyperemia, thickening of the membrane, or the presence of secretion, however trifling. Especial attention is to

[1] The accompanying illustrations have all been made from photographic views, and are intended, primarily, to reproduce faithfully the position of the hands of the operator as well as those of his assistant during the different operative procedures. This can be accomplished better by a photograph than by the most extensive description. In so far as possible, the operative procedure on the eye itself is also delineated sufficiently well in the same illustration. However, when it seemed necessary, the operation on the eye has been represented by itself in accompanying diagrams. The photographs were taken from the operator's side (that is, from the right side of the patient as he lies upon the table.) In order to render recognition easier, the hands of the operator are indicated by the letter *o;* those of the assistant, by the letter *a*. In all instances the operator sits to the right of the patient, while the assistant stands to the left. The relative positions assumed by the hands and the fingers of the operator and assistant should be observed. The figures show clearly how the hands are supported, how the instruments are held, etc.

be directed to the lachrymal sac, and should the slightest amount of fluid be pressed out of the puncta, extirpation of the sac must be performed before operation upon the cataract. In cases which show only slight symptoms of an affection of the lachrymal sac, such as epiphora or unilateral conjunctival congestion, the lower punctum is to be dilated with the conical probe, and a sterile fluid injected through the canaliculus. If the duct is normal the fluid will pass quickly into the nose, but should stenosis exist the injection will come through drop by drop. Passage of a probe will indicate whenever the mucous membrane of the sac is thickened. Any affection of the sac is an indication for its total extirpation and cauterization of the puncta to destroy all connection with the conjunctiva. Systematic bacteriologic examination at intervals of eight days is to be made until the conjunctiva is free from the presence of streptococci or pneumococci. The presence of xerosis bacilli or a few staphylococci are no contraindication to the cataract operation. During the time that the patient is under observation a solution of sulphate of zinc ($\frac{1}{2}$ to 1 per cent.) is dropped into the conjunctival sac three times daily, and, if the secretion is excessive, this is supplemented by applications to the conjunctiva of a 2 per cent. solution of silver nitrate.

The conjunctival culdesac cannot be made absolutely sterile, but an antiseptically conducted operation with a clinically normal conjunctiva almost always takes a course without infection. It is not possible in a large clinic to establish in every case the absence of pathogenic germs by bacteriologic examination and by cultures, but these tests should be made in all instances of inflamed conjunctiva.

Condition of the Lens.—If a cataract develops in both eyes, the eye with the more advanced lenticular opacity is operated upon as soon as disturbance of vision has progressed to a point where the patient can no longer pursue his occupation, irrespective of whether the cataract is completely mature or not. The extraction of an immature cataract is in no way more difficult than the removal of a fully opaque lens, although the retention of unclouded lens remnants in the eye somewhat complicates the operation. The clinical diagnosis of maturity can refer only to the anterior cortex of the lens, and yet the posterior cortical portion may be transparent and fail to pass out of the chamber, even with massage. If the posterior cortex is farther advanced in opacity than the anterior, the lens substance separates from the capsule and is readily expressed by massage, while the use of the capsule forceps to

tear a large central piece of the capsule secures the same results for the anterior lens fibers. Should particles of lens remain, they are not adherent to the capsule and are soon absorbed. Any procedure for artificial ripening of the immature lens should be avoided, and the performance of the so-called preliminary iridectomy is of no special advantage, and is only indicated in central opacity of the lens in which dilatation of the pupil consequent on the iridectomy sufficiently improves vision. (See optical iridectomy, page 227).

Monocular Senile Cataract.—If opacities develop in the lens of one eye, while the other eye has good vision, no operation is indicated until the cataract has become completely mature. When this point is reached, even though the other eye continues to have normal sight, extraction of the cataract is advisable. There is no valid reason why monocular cataract should not be removed. While the unequal vision of the two eyes may cause some temporary discomfort, it is more than balanced by the increase in the field of vision and in the consciousness of a reserve eye in the event of injury or failure of the other. If operation is postponed until vision fails in the good eye, the cataract reaches a condition of over-maturity, which not only complicates extraction but makes the prognosis less favorable.

Preparation of the Patient.—On the day before operation the patient is trained to look up and down, as directed, without movement of the head, and instructed as to his behavior during and after operation. Bromids may be administered in nervous patients, and codein in those that are inclined to cough. The bowels are to be emptied previously, and no constipation is to be allowed during the after-treatment. A simple, easily digested diet is ordered.

Preparation of the Eye.—One or two drops of a 3 per cent. solution of cocain are dropped into the conjunctival sac frequently for ten minutes. The skin of the closed lids and the surrounding parts is wiped with benzin to remove all fatty material, and then carefully cleaned with a liquid neutral eye soap. The skin is then washed with a 1–2000 bichlorid solution, but this is omitted in persons inclined to eczema. The conjunctival sac is now thoroughly douched with physiologic salt-solution, particularly the upper and lower culdesacs and the recesses in the region of the inner canthus, and the conjunctival surface of the everted lids gently rubbed with pledgets of cotton dipped in the solution. The entire region of the eye is then covered with a sterile, moist gauze dressing. During operation the other eye is kept

closed by a gauze pad, unless the patient cannot turn the eye to be operated on in the desired direction without having the seeing eye uncovered.

Cocain usually suffices to give perfect anesthesia. In nervous and unruly patients an injection of morphin-scopolamin may be required to ensure perfect quietness. No mydriatic is employed before the operation, and none after unless special indications point to its use.

Sterilization of the Hands and Instruments.—Both surgeon and assistant thoroughly scrub the hands with soap and water and bichlorid solution and dry them with sterile towels, cover the head with a sterile cap, and wear a sterilized mouth mask to guard against possible infection of the wound while giving necessary directions. Sterile dressings are placed around the patient's head and neck, with light gauze over the nose and mouth.

All instruments are boiled for three minutes in a 1 per cent. solution of carbonate of soda. It is exceptional for the blade of the knife, if of the proper hardness, to suffer any damage, and we have repeatedly performed a number of extractions with the same knife which showed no dulness from the frequent boiling. The instruments are



Fig. 81.—Fixation forceps.

lifted from the boiling water to a large flat tray filled with sterile physiologic salt-solution of body temperature. The sterilizer is close beside the operator, and no instrument touches the eye a second time until it has been re-sterilized by boiling. Duplicates of instruments frequently required, such as Daviel's spoon and spatula, should be ready.

During the operation, any secretion or blood is removed by small pledgets of absorbent cotton, which are kept soaked in a sterile physiologic salt-solution.

EXTRACTION WITH IRIDECTOMY.

The technic of the various steps of the operation will first be considered, and then the complications which may occur in each.

Fixation of the Eye (Figs. 82 and 83).—It is the custom in our clinic to sit at the right of the patient who is lying upon the operating table. The incision is made from the outer side, on the right eye with

the left hand, and on the left eye with the right hand, the other hand fixing the eyeball. An ordinary pair of toothed fixation forceps (Fig. 81), with three dentations, held between the thumb and forefinger, is applied perpendicularly to the sclera near the lower part of the limbus, and grasps tightly a fold of the conjunctiva exactly in the vertical meridian. If the conjunctiva is seized at even a slight distance from the limbus, fixation will not be firm.

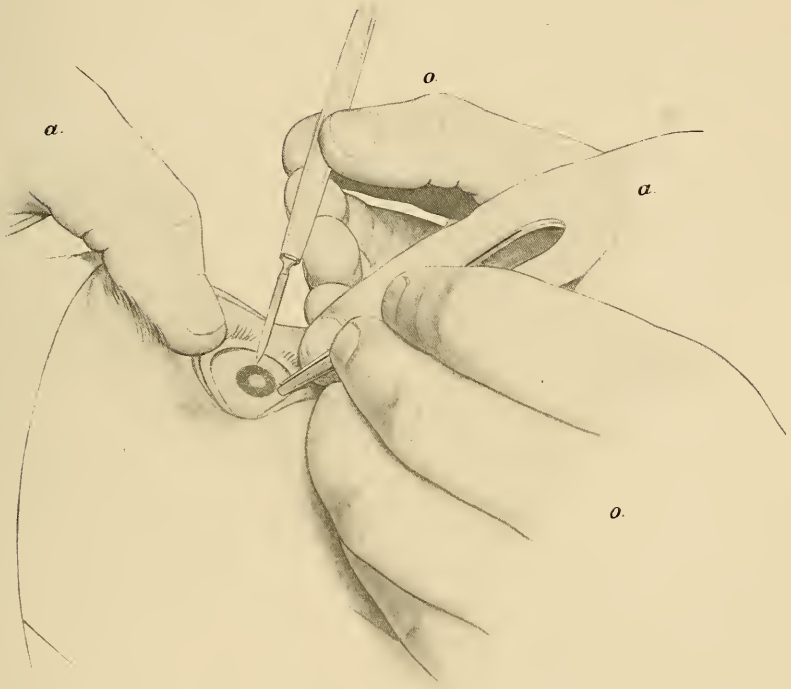

FIG. 82.—Beginning of the cataract-incision in the left eye. While the assistant holds the eye open according to the rules given on page 267, the forceps held in the left hand grasp the eye below, close to the limbus and exactly in the vertical meridian. The patient during this procedure looks well downward. The knife held in the right hand with its edge directed upward is applied exactly at the limbus and is held horizontal and parallel to the plane of the iris.

The operator at the right of the patient finds no difficulty in fixation of the right eye, as the forceps held in the right hand are placed directly opposite to the right eye, but it is not so easy, especially for the beginner, to fix the left eye from the position mentioned. To this end the left upper arm, with the elbow in a strongly flexed position,

is pressed firmly against the chest, while the hand, itself bent dorsally, guides the forceps, held between thumb and first and second fingers, vertically to the lower portion of the limbus, where the fold is raised. Through this unaccustomed position of the arm, the beginner very easily falls into the error of pressing upon the eye instead of pulling forward, a mistake that is frequently the cause of unpleasant complications.

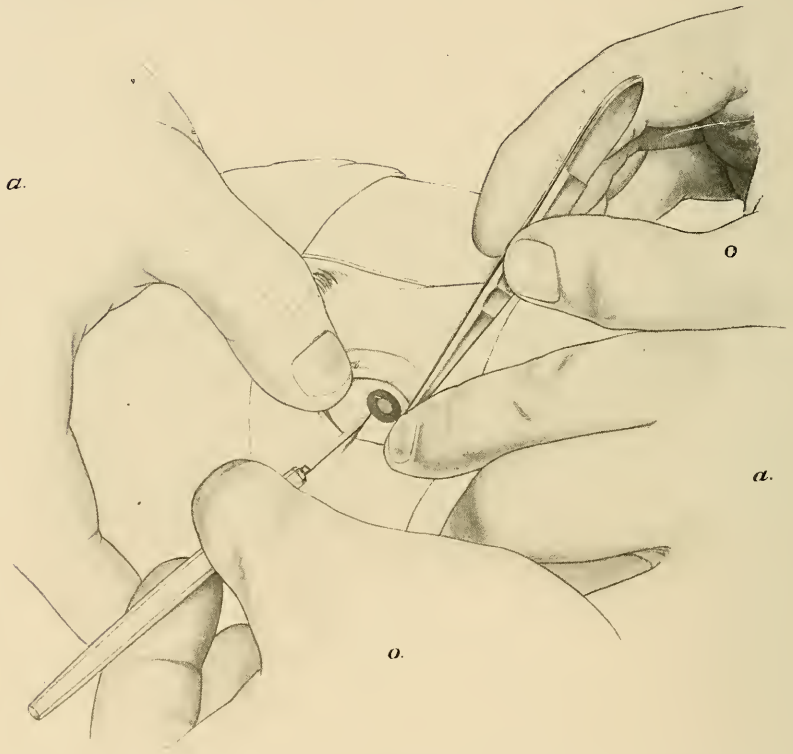

FIG. 83.—Beginning of the cataract-incision in the right eye, the operator and the assistant occupying the same positions. The eye is fixed with the right hand, the knife is held in the left.

The fold of the conjunctiva must be raised exactly in the vertical meridian. If the operation is performed with an iridectomy, it is essential that the incision be made accurately above, so that the coloboma, which corresponds to the central portion of the cut, will also be directed upward, and be completely covered by the upper lid. If, however, the eyeball is grasped sideways, for example, at the end of

the horizontal meridian, rotation of the globe is unavoidable, as the eye must be drawn continually downward during the incision, in order to expose the upper corneal margin. This rotation places the incision in an oblique and undesirable position, and with it also the coloboma. In inserting the knife, the eye may rotate slightly out of its position, but this cannot further displace the incision. By means of the elevated fold the eye is drawn not merely downward, but also slightly forward. During the incision the patient is directed to look well downward.

The incision (Figs. 82 to 87) is probably the most difficult part of the operation. It is made upward with the narrow Graefe cataract-knife and includes about one-third of the corneal periphery, and in its entire length is in the limbus or close behind it.

The knife, with the edge upward and the blade parallel with the iris, is held horizontally between the thumb and first and second fingers, and the hand is supported by the little finger placed on the patient's head (Figs. 82 and 83). The point of the knife pierces the eye at the limbus, 1 mm. above the end of the horizontal meridian, and is pushed without a pause through the anterior chamber in order that the counter-opening internally is made in a symmetrical position. The chief factor in the success of the incision is the avoidance of any pause or retrograde movement.

The beginner finds it difficult to make the counter-puncture in the proper position, and to his astonishment the knife emerges in the sclera behind the limbus. The reason for this error is clearly understood from a study of the anatomical relations of the anterior chamber (Fig. 126). The limbus extends much further (2 mm.) anteriorly than the angle of the anterior chamber. If the knife is brought as far as this angle, the inevitable consequence is that the counterpuncture is performed in a faulty place far beyond the limbus. In order that it be made either directly at the limbus or close to it, the knife must be directed to a point in the cornea about 1 mm. from the limbus (Fig. 84), where, as viewed from in front, transparent cornea is still present. The impression thus given is that the knife will appear at the surface in transparent cornea, but to the operator's surprise the point emerges in the limbus (Fig. 85). The beginner is, therefore, usually told to direct the point of the knife toward a spot in the cornea, situated about 1 mm. distant from the limbus.

As soon as the counter-puncture is made, the knife, as it is pushed across the anterior chamber, is steadily carried upward without pause,

at all sides parallel to the limbus, so that a large part of the incision is effected by this one movement (Fig. 86). This brings the blade above the pupillary border and prevents premature escape of the aqueous and also injury to the iris. After the greater part of the blade has been passed across the anterior chamber, the incision is continued

FIG. 84.—Diagram showing the point of the knife directed toward a point in the cornea about 1 mm. within the limbus, so as to begin the counter-puncture.

and frequently completed as the knife is drawn back, or it is at least finished with the next forward movement. With a keen-edged knife the incision can be completed in two or three drawing movements. The shorter the sawing cuts the more irregular the wound. The inexperienced operator fails to carry the blade forward sufficiently after

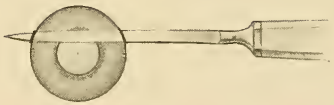

FIG. 85.—Diagram showing the point of the knife thrust just through at the limbus.

making the counter-puncture, and frequently does not begin the upward cut until the knife is drawn back. As the thinnest part of the blade near the point is insufficient to properly close the wound opening, the aqueous begins to escape, and the surgeon, no longer controlling the long part of the blade, is forced to complete the section by short

FIG. 86.—The knife is pushed forward in the same direction in which puncture and counter-puncture are made, so that a good part of the incision is made. In this manner a considerable part of the blade has been employed for this part of the incision.

sawing movements. It may even happen that in drawing back the knife the point is brought again into the anterior chamber.

The reason that the beginner frequently does not advance the knife, in spite of many short sawing movements, lies usually in the fact that,

instead of pushing the edge upward, he presses the blade backward toward the sclera.

During the incision *the knife must remain exactly parallel to the iris*, as any turning of the edge forward or backward would naturally

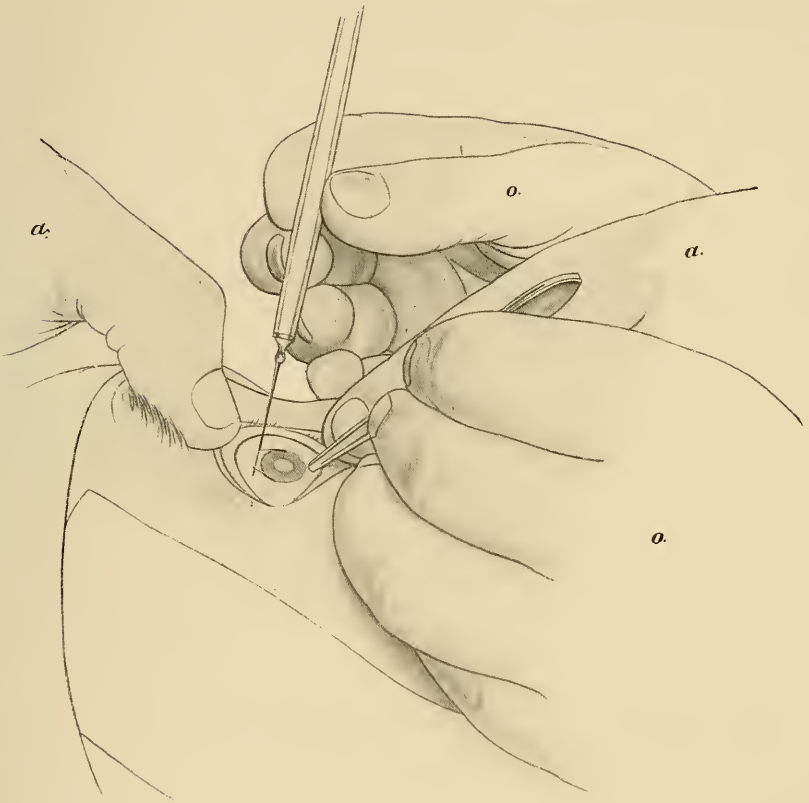

Fig. 87.—Incision on left eye. The cornea-sclera is already cut through and the knife is beneath the conjunctiva. In order to cut the flap off short, the knife is turned in such a manner that the edge looks forward. The knife is now turned up. Note the change in the position of the hands of the operator as compared with Fig. 82. The line of the incision in the cornea-sclera, as far as it lies behind the base of the conjunctival flap, is designated by dots.

result in a deviation of the cut, either into the cornea or into the sclera. Only after cutting through the sclera, and the knife is seen under the conjunctiva, is it recommended to turn the blade through an arc of 90 degrees (Fig. 87), so that the edge looks anteriorly. This secures a

conjunctival flap that is much shorter than if the knife in the previous position had been permitted to cut through. A long conjunctival flap is an unpleasant impediment to a proper performance of the operation. The incision having been completed, the forceps are released and the rest of the operation finished without fixation.

Iridectomy (Figs. 90–93).—The patient looks well downward, and the closed iris-forceps (Fig. 88), held in the left hand between thumb

Fig. 88.—Iris-forceps.

and forefinger, with the concavity of the blade forward, are introduced vertically through the wound in front of the iris to the pupillary margin, opened slightly, and a narrow fold of the iris seized, drawn forward and quickly cut off with the iris-scissors (de Wecker's pince-ciseaux, Fig. 89) held in the right hand (Figs. 90 to 93). The hand guiding the forceps must take a position of marked flexion, in order to introduce the instrument exactly from above. Should the conjunctival flap interfere with the introduction of the forceps, it may be turned down over the cornea by aid of the closed scissors, while the forceps press the scleral edge of the wound slightly backward.

The arms of the pince-ciseaux should be directed upward during



Fig. 89.—Iris-scissors (pince-ciseaux, de Wecker).

the excision (Fig. 90), to secure a narrow coloboma in the form of a pointed arch. It is, however, no mistake to make the cut with the arms of the scissors held parallel to the limbus.

Opening the Anterior Lens Capsule (Figs. 96 to 98).—This may be done with the capsule-forceps or the cystotome, but our preference is the capsule-forceps (Figs. 94 and 95). The patient looks well downward, and the operator holds the forceps in the right hand between the thumb and forefinger, raises the upper lid with his left hand, while the assistant draws the lower lid slightly away from the eye. The closed instru-

ment is introduced vertically from above (hence a position of the hand analogous to that in iridectomy), and pushed forward into the anterior chamber until the dentated parts of the arms lie in the pupil, while their posterior portion is situated in the coloboma.

The forceps must be in such a position that both arms, when opened, glide along the surface of the anterior capsule (Fig. 97). A common

Fig 90.—The iridectomy. The eye is no longer fixed. With the thumb of the right hand, the assistant holds the upper lid up from the side in such a manner that the operator is not hindered in inserting the closed iris-forceps directly from above through the wound to a point near to the pupillary margin. The right hand holds the iris-scissors already opened close by, ready to quickly cut off the iris as soon as it is drawn forward. For the sake of clearness the conjunctival flap is not represented on this and the following figures.

mistake is to hold the forceps obliquely so that only one arm lies against the capsule, while the other rests a greater or lesser distance away in the chamber. After the forceps have been placed properly on the capsule, with the teeth directed inward, the instrument is opened as widely as the size of the pupil permits. A slight degree of pressure is then exerted in the direction of the lens, the forceps again closed, and a fold

of the capsule seized between the teeth (Fig. 98), and torn loose from its surroundings by a slow pulling movement. A still greater opening

Fig. 91.

Fig. 92.

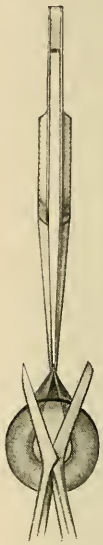

Fig. 93.

Figs. 91 to 93 show in natural size the maneuvers in seizing and extracting the iris.

Fig. 91.—The blades of the iris-forceps held close to the pupillary margin have just been opened.

Fig. 92.—The blades have been closed and have seized a fold of the iris.

Fig. 93.—The portion of the iris, which has been drawn forward, is cut off by the scissors brought from below.

may be obtained by permitting the arms to push the pupillary margin of the iris gently backward. The separated piece of capsule must be

Fig. 94.—Capsule-forceps open (side view).



Fig. 95.—Capsule-forceps closed, showing the toothed portions only in contact.

drawn slowly from the eyeball in order that it be not detached from the forceps and left folded up in the wound.

After withdrawing the forceps it is desirable to ascertain that the

piece of capsule is in its grasp and does not by any mischance remain behind in the wound. Ordinarily, there is obtained a round piece of the anterior capsule, which is usually the size of the pupil or much larger. The degree of pressure needed to raise up a fold of capsule is very slight, but if greater than it should be there is no danger of

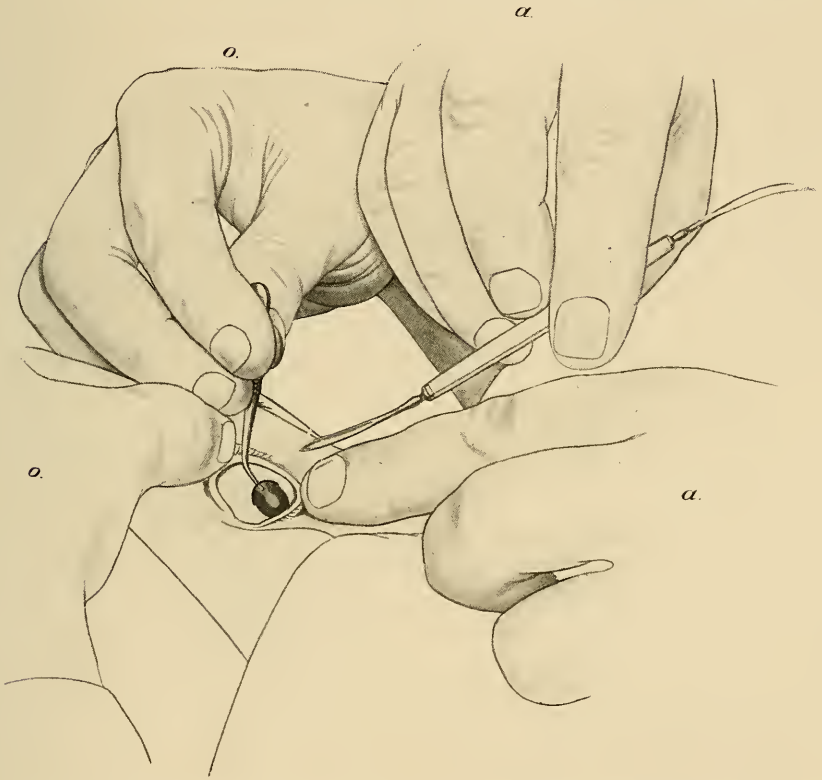

FIG. 96.—Opening of the capsule. The eye is not fixed. The operator himself is holding the upper lid elevated with his left hand, while with the right he is just beginning to introduce parallel to the plane of the capsule the closed capsule-forceps. The assistant holds the lower lid slightly away from the eye, not only to freely expose the cornea, but also to prevent any pressure on the eye by the lid should it be forcibly contracted by the patient. The other hand of the assistant holds the spoon directed toward the upper lid in such a manner that he can bring it at any time and at once beneath the lid, if the patient should begin to wince and there would be danger of his pressing the upper lid into the wound.

dislocating the lens, as the soft cortical material back of the capsule gives way to the pressure and slips aside. To avoid seizing the iris, the forceps are so constructed that, when closed, the posterior portions of the arms remain apart from each other, and besides, in raising up

the fold of the capsule, the forceps are so held that only the toothed edges impinge, while the posterior parts of the arms are free in the chamber (Fig. 95). In extraction with iridectomy this factor plays no rôle, as the posterior portions of the arms lie within the confines of the coloboma, but in extraction without iridectomy, it is important, by these precautionary measures, to prevent pinching the iris.

Opening of the anterior capsule by means of the pointed tenaculum of the cystotome is relatively easier. The tenaculum should be made to slide down close to the posterior surface of the cornea and parallel to it, so as not to become entangled. When it reaches the pupillary area, it turns through an arc of 90 degrees until the point is directed backward. It is then brought into contact with the anterior lens capsule, and several superficial cuts are made in various directions. During this procedure, no degree of force is either necessary or per-

Fig. 97.

Fig. 98.

FIG. 97.—Diagram showing both blades of the capsule-forceps widely opened gliding over the anterior capsule.

FIG. 98.—The blades have been closed and have grasped between them a fold of the capsule which is now being pulled out.

missible. The instrument is withdrawn from the eye in the same manner as it was introduced, that is, parallel to the corneal surface and inverted.

The great advantage of the capsule-forceps, which outweighs the disadvantage of its somewhat more difficult manipulation, lies in the fact that a large opening is made in the anterior capsule directly in the pupillary area. The result of this loss of tissue is that the capsule cannot produce optical disturbances later on. Again, the remnants of the cataract left behind in the capsule-sac are exposed to the action of the aqueous humor, with the result that, even in the operation for

unripe cataract or when a large number of cataract remnants are present, they usually undergo spontaneous absorption immediately after the operation. We therefore do not employ irrigation of the anterior chamber to remove particles of lens, and believe the procedure is

FIG. 99.—Expression of the lens. The manner in which the operator holds his hands should be observed. With the thumb of his left hand, he raises the upper lid and at the same time pulls it slightly away from the eyeball. The forefinger of the right hand exerts pressure on the lower half of the cornea through the lower lid; this causes gaping of the wound and the edge of the lens presents in the wound. The assistant holds the spoon ready, on the one hand, to care for the upper lid and, on the other, to roll the lens completely out of the eye after it has protruded half way.

calculated to do more injury than good, subjecting the eye to the danger of infection, to iritic irritation, and to injury of the corneal endothelium, with subsequent cloudiness of the cornea.

Expression of the Cataract (Figs. 99 and 100).—The patient looks downward; the eye is not fixed. While the upper lid is raised by the thumb of the left hand, the forefinger of the right hand begins to exert pressure through the lower lid in an anterior-posterior direction against the region of the lower corneal margin. The immediate result is that the lens rotates upon its horizontal frontal axis and its upper edge turns anteriorly and presents in the wound, which now begins to gape.

From the moment the edge of the lens presents in the wound, the direction of the pressure is to be made from below upward, as a further continuance of the backward pressure would cause the vitreous to appear. The lens is now pushed up and out of the wound by a stroking movement exerted on the eye through the lower lid. It is not permissible, however, to stroke upward above the middle of the cornea, as this would compress the wound and cause the lens to retreat into the eye.

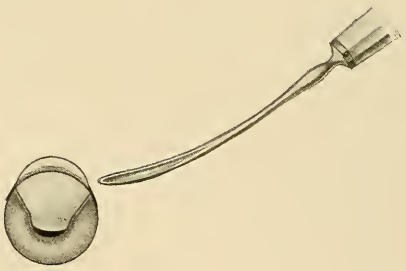

FIG. 100.—Diagram showing the spoon just about to be applied to the lateral margin of the half-delivered lens so as to roll it completely out.

As soon as the upper half of the lens has passed the wound, the assistant applies the spatula to its margin and removes the cataract from the eye (Fig. 100). At the same time the operator ceases pressure. The presentation of the lens-border in the wound can be facilitated by a slight depression of the scleral edge of the wound through the aid of Daviel's spoon. In the average case, however, this is not necessary, and depression is employed only when the delivery of the lens is difficult.

After the exit of the lens, the upper lid is guided carefully down over the eye, so as to prevent the wound from gaping. Through similar stroking and kneading motions, any retained cortical remnants are brought out through the wound. The more thoroughly this is done, the less likelihood there will be of secondary cataract. Sometimes lens remnants are brought up from behind the iris by this massage, and the

pupil, which at the outset appeared black, turns gray again until the lens particles have passed into the wound. Occasionally their removal is facilitated by inserting Daviel's spoon into the anterior chamber, but long-continued manipulation is not advisable in the endeavor to get the pupil clear.

As soon as it is seen that the wound shows an inclination to gape, and the vitreous is bulging forward and is in danger of prolapse, it

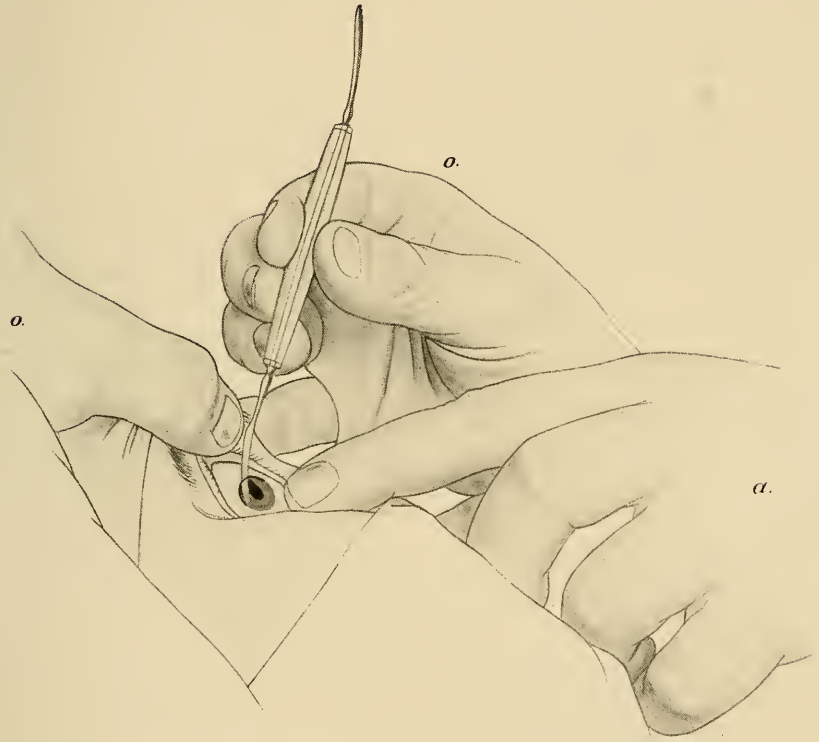

FIG. 101.—Reposition of the inner margin of the coloboma. The eye is not fixed. The operator himself holds the upper lid in the same manner as above. His right hand introduces the spatula obliquely into the inner angle of the wound, in order to smooth the iris down from this point. The lower lid is drawn slightly away by the assistant.

is better to desist from attempts at removal of the remnants, and to end the operation. It may happen that, although the pupil is thought to be free of cortical substance, on the day after the extraction it is found to be full of swollen masses of lens material. At the time of the operation this material was transparent, and, of course, could not be detected.

Toilet of the Eye (Figs. 101 to 104).—This represents the final stage of the operation, and its most important part is the reposition of the iris. This is accomplished by the spatula, which is held parallel to the plane of the iris and pushed carefully through the lips of the wound into its angle (Fig. 103). When the anterior chamber is reached, gentle pressure is exerted on the iris, one edge of the spatula being turned slightly posteriorly at the same time (Fig. 104). By moving the spatula toward the center of the pupil, the iris is stroked into its proper position.

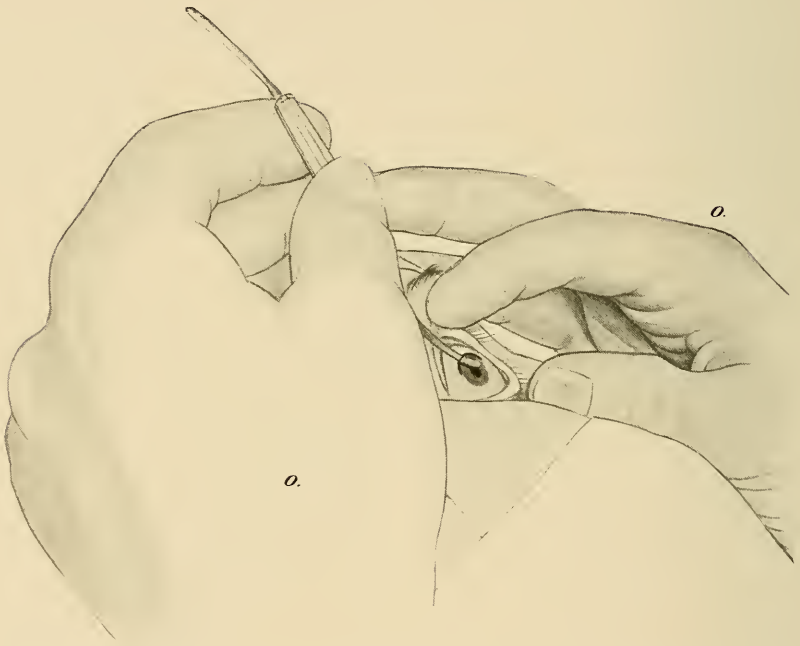

FIG. 102.—Reposition of the outer margin of the coloboma.—The operator holds the upper and lower lids by means of the thumb and forefinger of the right hand, while the spatula is introduced with the left hand from the inner side obliquely into the outer angle of the wound and the iris smoothed back.

Care must be taken not to turn the end of the spatula backward, as injury of the hyaloid will occur, with prolapse of the vitreous. It is of no importance which hand is used in this manipulation. We employ alternately, as a rule, the right and left hand for the right and left angles of the wound, respectively. In many cases one can smooth the iris out directly from above downward, by holding the spatula vertically. Of only really great importance is the position of the sphincter, which

can be recognized by its color, which is different from that of the rest of the iris.

The conjunctival flap is now carefully stroked into its intended

Fig. 103.

Fig. 104.

Fig. 103.—Diagram representing the eye and spatula during the reposition in natural size. For the purpose of reposition the spatula is introduced into the angle of the wound between cornea and iris.

Fig. 104.—In order to accomplish the backward stroking more easily, the spatula is rotated a few degrees (set on edge) and then by a suitable movement the angular extremity of the sphincter is smoothed down.

position by aid of the spatula. Occasionally the conjunctival flap is caught in the wound, and naturally causes a material delay in its closure.

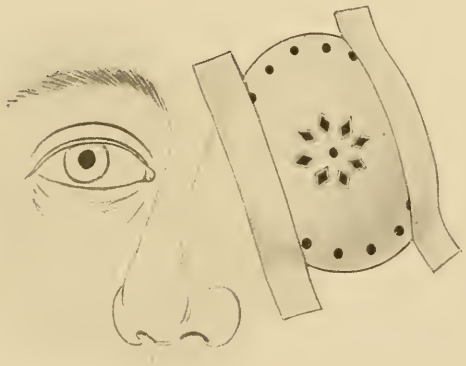

Fig. 105.—The Snellen cup.

After the conjunctival sac has been freed of blood and lens remnants, the eye is closed and a binocular bandage applied.

Dressing and After-Treatment.—After completion of the cataract operation, the conjunctival sac is washed out with sterile salt-solution, a pad of gauze and cotton placed over each eye, and a binocular bandage applied. The Snellen cup of perforated aluminum (Fig. 105) covers the operated eye to guard against mechanical injury, and is held in place with strips of adhesive. As the plaster does not adhere well to the bearded skin of men, the Fuchs' lattice is used in the manner shown

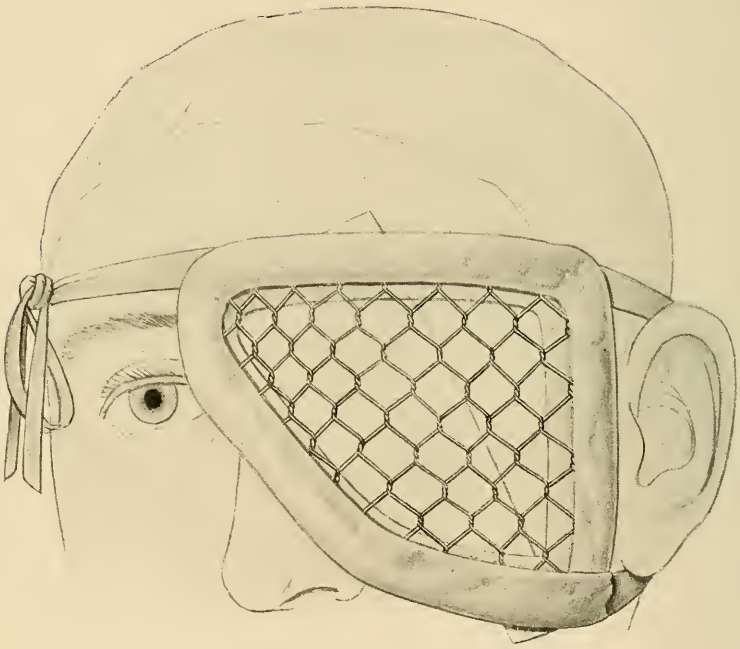

Fig 106.—Fuchs' lattice.

in the accompanying illustration (Fig. 106). The patient is then put to bed. Very old persons, especially if they suffer from bronchitis, remain seated in a comfortable armchair after the extraction. In this way hypostatic pneumonia is best prevented.

Drinking men are conceded a moderate amount of alcohol, and users of tobacco are permitted to smoke the following day. The diet is restricted to liquids, milk, coffee, and nourishing soups with eggs. Diabetics are given 30 grains of sodium bicarbonate daily besides the appropriate diet.

Change of Dressings.—On the day following operation the dress-

ings are removed from both eyes, the patient keeping the lids closed as in sleep, and the lids are gently cleaned with physiologic salt-solution. If the margins of the lids are adherent a simple ointment should be used before the dressings are re-applied. The patient is directed to open the lids slightly, and the surgeon examines to see if there is excessive congestion, if the anterior chamber has reformed, and the pupil is round or distorted. The upper lid is not to be raised nor the patient directed to look downward unless some complication requires that the surgeon inspect the wound.

No harm can follow the change of the dressings on the day after operation if expertly done, and we deem it inadvisable to wait until the third or fourth day before removing the bandage.

If the eye shows no irritation and the pupil and coloboma are black, no atropin will be required, but if there is considerable injection and remnants of the cataract are seen in the pupillary area a mydriatic is used to prevent attachments of the iris and the lens capsule.

At the first change of dressings the sound eye is not re-bandaged, unless the wound remains open and it is necessary to keep both eyes quiet. If healing has progressed favorably, the patient is dressed by the nurse, and allowed to remain out of bed in an armchair. All use of the unoperated eye for close work is forbidden for the entire period of the after-treatment.

The dressings are changed regularly every day, and, at the expiration of a week, they are omitted in the day time, and a pair of dark smoked glasses worn for protection from the light, but at night the aluminum cup or lattice is re-applied without any dressings beneath.

At the end of two weeks after operation the patient may leave the hospital, as the wound is so securely cicatrized that no further special protection is necessary. It is advisable for patients whose occupation demands severe physical labor to rest for several weeks longer or perform lighter work.

EXTRACTION WITHOUT IRIDECTOMY

Extraction without iridectomy gives the best operative results, but the method possesses several disadvantages which materially limits its employment. Prominent among these are the necessity of a second operation in case of subsequent prolapse of the iris, and the increase in pressure caused by the occasional distortion and fixation of the iris to the scar.

Indications.—This operation may be performed if it is certain that the patient will lie quietly in bed afterward, but is never undertaken in very old people or if the patient has a cough. If there is good vision in the other eye, extraction without iridectomy may sometimes be permissible. If, however, the other eye is incapacitated or its vision diminished in consequence of some disease apart from incipient cataract, the extraction must always be performed with iridectomy so as to avoid any complications. To be successful, extraction without iridectomy further depends upon certain conditions of the eye. With a narrow pupil and a large lens-nucleus, the operation must be done with an iridectomy, and the same is true in all cases of complicated cataract. Therefore, it is only when the iris tends to retain its position in the eye and shows no inclination to fall forward, and the course of the operation promises to pass off uncomplicated, that the operator concludes to perform extraction without iridectomy. It often happens that it is not decided to do the iridectomy until after delivering the lens-nucleus through the round pupil. If it is seen that, in spite of persistent attempts to replace the iris, the pupil draws upward after each reposition, or even if it is suspected that the iris will prolapse later, iridectomy is indicated. Because of these precautions the reported percentage of prolapse of the iris on the day following the operation is comparatively small. It occurred in 8 per cent. of the author's patients, of which about one-third were operated without iridectomy, and among this 8 per cent. are included all cases in which the pupil was not absolutely round, but only slightly oval-shaped, without a real prolapse in the wound.

The opening of the capsule may be difficult with a narrow pupil, and it is advisable to use the cystotome instead of the forceps. A narrow pupil is a marked impediment in the delivery of the lens, especially if the nucleus is large. The operator must decide whether or not the lens can be delivered through the pupil without too strong pressure, and if not, perform an iridectomy rather than risk a prolapse of the vitreous by exerting excessive force.

Should the iris stretch over the advancing lens, the assistant may facilitate its delivery by elevating the pupillary margin with the spatula. The resistance of the sphincter of the iris of old persons is often considerable, and it may be torn as the lens pushes through. It is then better to perform an iridectomy, since the relaxed and lacerated pupil fails to regain its normal position, and becomes irregular through retraction

of the margin of the tear. If a prolapse of the vitreous occurs during the operation, iridectomy is usually impossible, and the lens should be delivered with the loop or the double tenaculum. The iris in the region of the incision is turned backward, and it is only when the vitreous floats it into the wound that the surgeon can excise a portion, which should be as large as possible.

The removal of cortical substance is more difficult in the simple than in the combined extraction. If, during the expression of the nucleus, the pupil has been pulled upward and the iris presents in the wound, it is advisable to massage the soft remaining particles of the cortex out of the eye, as in this way only can success attend subsequent efforts to replace the iris. Once the pupil has regained its round contour, massage carries the lens particles upward behind the iris, without bringing them out of the eye. Individual flakes contained within the pupillary space can be removed with the Daviel spoon.

The incision for simple extraction does not differ from that of the ordinary combined operation, but it should be made exactly at the limbus.

Prolapse of Iris.—After the operation it is customary to instill eserin into the eye, although it is of doubtful value. If the pupil is not perfectly round on the day after operation, the wound is re-opened after thorough cocainization, and the iris resected. This is indicated even if the iris does not lie directly in the wound, but is, of course, essential in true iris-prolapse. Eserin may be discontinued on the second day providing the anterior chamber is re-established and the pupil round. Atropin may be employed as early as the second day to allay irritation.

Excision of the prolapsed iris is usually difficult, as the irritated eye cannot be made sufficiently insensitive by the cocain. The wincing of the patient renders prolapse of the vitreous probable. After the wound is re-opened with a conical probe, the operator should drop cocain directly on the exposed iris. Following excision of a piece of the iris, it is often easy to stroke out lens remnants, which on the previous day could not be removed. Replacement of such prolapsed iris, without excising a portion, should not be considered, as in all probability the prolapse would recur.

The dressings and after-treatment are the same as given for operation with iridectomy.

EXTRACTION WITH PERIPHERAL IRIDECTOMY.

Chandler, of Boston, and Pflüger, of Bern, perform a small peripheral button-hole of the iris as a precautionary measure against iris prolapse in simple extraction, and the method has been recently warmly advocated by Hess.

After the removal of the lens and replacing of the iris, fine toothed, specially made iris-forceps are introduced into the wound and the smallest possible piece of the root of the iris drawn up and excised close to the wound with fine curved scissors. In most cases a tiny opening (Fig. 107) results, which is often so covered by the limbus that it is only perceived when the patient looks upward. Occasionally the excised portion of the iris is greater than desired and a larger hole is formed, but this is of no serious matter. The lens should be removed before the button-hole is made, otherwise the cataract may enter and pass through the space, causing lateral laceration of the iris. With a rigid sphincter the passage of a lens with large nucleus is difficult, so that the usual iridectomy must be made. Atropin is not instilled before the operation, because it is desirable that the sphincter retain its normal power, nor is it employed afterward.

FIG. 107.—Peripheral button-hole in the iris.

The advantage of peripheral excision of the iris is that prolapse of the iris is exceptional, even should there be a reopening of the wound with sudden escape of the aqueous. There is also less tendency for soft lens masses to remain in the eye, as the remnants that ordinarily accumulate behind the iris escape through the peripheral opening by massage. The button-hole lessens the risk of glaucoma in extraction without iridectomy.

The operation is contraindicated in complicated cataract, and in cataract with thickened lens capsule where removal of the lens and capsule is intended. The usual iridectomy is more suitable in extraction of cataract in restless patients and those who are constantly blinking the lids.

If, after simple extraction, the pupil is not perfectly circular, and there is risk of later prolapse, peripheral excision may be performed instead of removal of the whole breadth of the iris. The peripheral excision of the iris usually preserves a round pupil.

EXTRACTION OF THE LENS IN THE CAPSULE.

From the satisfactory results of the method of operation as followed in our clinic, we do not regard extraction of the cataract in its capsule as offering any special advantages. Our experience of the intracapsular method is limited to only a few cases, and we can therefore express no opinion of its value.

ACCIDENTS AND COMPLICATIONS DURING OPERATION.

The foregoing descriptions concern the uncomplicated operation for extraction of senile cataract. Untoward accidents, however, may complicate each step of the operation, and they are described and classified under the particular stage in which they may occur.

Fixation of the Eyeball.—In elderly people the conjunctiva is often friable, and likely to be torn by the forceps in fixation. If, after the beginning of the incision, the conjunctiva tears and the patient will not voluntarily turn his eyes downward, the inferior rectus or preferably the superior rectus will serve as a firm point of fixation. It would be useless to seize the conjunctiva in another place, for it would tear out again. It is not permissible to bring the knife to a standstill while it is in the anterior chamber, as the aqueous humor escapes and the iris falls in the way of the knife. If the forceps tear out before the incision is begun, the disadvantage of fixation of the muscle is that the knife, in making the puncture, causes a marked rolling of the eye, which renders the beginning of the cut somewhat difficult.

The Incision.—The errors possible in regard to the incision concern (1) the position, (2) the length, and (3) the manner in which it is executed.

Position of the Incision.—The incision may be too far forward in the cornea, or too far backward in the sclera. This is due to error in making the counterpuncture. If, after the puncture is made, the knife is pushed on directly into the angle of the chamber, the sclera is pierced in an oblique direction and the knife emerges beneath the conjunctiva far behind the limbus. In order to bring the knife out directly at the limbus, the point should be directed toward a spot in the cornea about 1 mm. distance forward from the limbus. The operator, looking at the eye from in front, thinks that the knife will emerge too far in the cornea, and is surprised to see the point appearing in the limbus or close behind it. Hence, the novice may naturally fall easily into the opposite error, of making the counter-incision much too far into the cornea.

The peripheral incision in the sclera is usually accompanied by severe hemorrhage, and the blood, flowing into the chamber, hides the iris and lens from the operator's view. Besides, the incision is quite painful, as the cocain has not the same effect on the sclera as on the cornea. As the knife passes through nearly in the plane of the iris the latter falls in the way of the knife and a large piece is excised, and often the lens capsule is injured. When it is considered that the patient in consequence of the painfulness of the incision usually winces, we can understand how this single error, which is so frequently seen in extraction by the novice, gives rise to the common distressing experience of wound of the iris and lens capsule—the lens protruding through the gaping wound, and the vitreous pouring out behind it.

Gaping of the wound is in general one of the great disadvantages of peripherally situated incisions, particularly as it predisposes to an extensive prolapse of the vitreous. An incision situated too far forward in the cornea is better than one made too far in the sclera, but it also has objections, the chief of which is its relative shortness. The further into the cornea the incision, the more it becomes shortened from the arch to its chord, and consequently the more difficult the delivery of the lens. Among the unpleasant sequelæ of the corneal incision is a high grade of permanent astigmatism, the formation of anterior synechia with increase in tension from blocking of the angle of the chamber, and the liability to infection, although the latter is of less significance with the present-day antiseptic precautions.

Length of the Incision.—On an average the incision should include about a third of the corneal periphery. No difficulties are presented in finding the right point of the insertion—1 mm. above the end of the horizontal meridian. It is only through an abnormally oblique passage of the knife through the anterior chamber that an improperly situated counterpuncture can result, in consequence of which the cut will be too short. The relative shortness of a corneal incision has already been mentioned. The type of patient must, however, be always taken into consideration in determining the length of the cut. If a comparatively young individual (in the early forties), in all probability a shorter incision will suffice, as at this age the lens nucleus is still small, while one of greater length will be necessary if a large brown cataract, a totally sclerosed lens, is present. Should the patient have an abnormally small cornea, the puncture must be made further below, if necessary at the horizontal meridian, to insure a diameter of sufficient size.

Manner in which Incision is Made—The first rule to be observed is under no circumstances to withdraw the knife after it has once pierced the outer tunic of the eye and entered the anterior chamber. The beginner, becoming frightened at seeing the knife pierce a small bit of iris, draws the knife backward in order to free it. The immediate result is escape of the aqueous humor, and, instead of a small piece, the whole width of the iris must now be cut through. It is never permissible to draw the knife backward, nor even bring it to a standstill. The counterpuncture once completed, no delay is allowable, and the incision is to be continued immediately.

If the anterior chamber has been entered with the edge of the knife *directed downward*, the counter-puncture is first to be made, and then the knife rotated as quickly as possible 180° in its long axis, so that its edge becomes directed upward. The quick rotation prevents the escape of the aqueous humor. Turning of the knife in the wound is without disturbing consequences, if its edge passes the arch in the direction toward the cornea.

If the knife is held with its point directed too far forward, it may happen that, instead of entering the anterior chamber at once, the blade courses between the lamellæ of the cornea for some distance—the so-called *intralamellar incision*. This error results in a wound much too small. An intralamellar incision is, however, rare in the cataract operation. If the position of the knife between the lamellæ of the cornea is noticed early enough, that is, before a puncture into the anterior chamber has resulted in escape of the aqueous, the knife can be withdrawn and entered at once in the correct place. If the aqueous humor has already escaped, the operator must continue with the incision, no matter how it terminates, and widen it later with the scissors.

The surface of the knife blade must always be parallel to the surface of the iris. Only in this way is it possible to continue cutting in the same plane. Should the edge of the knife be turned slightly forward, the incision deviates anteriorly into the cornea; if directed a trifle backward, it is made more and more obliquely into the sclera.

No direct pressure should be made with the knife; on the contrary, the blade is to be drawn through in an upward direction with long sawing movements. Pressure of the knife against the sclera stops its forward progress. Thus a novice may believe that he has a dull knife, while he himself is responsible.

The knife should be carried through the chamber in a horizontal direction. While it is lightly held between the thumb on one side and first and second fingers on the other, the handle of the knife rests upon the first joint of the forefinger. The little finger is supported in the region of the patient's temple to prevent making a false cut, should he move unexpectedly.

After the sclera has been cut through, and the knife is beneath the conjunctiva, it is turned so as to cause the edge to look anteriorly. It is an error to turn the knife while it is still embedded in the sclera, as not merely irregularity in the wound will occur, but the incision will lie too far into the cornea.

Finally, there is to be considered which hand should make the incision? To operators who are not naturally lefthanded, the cut made with the left hand does not present any unusual difficulties. The surgeon who only employs the right hand must operate on the right eye from behind, and on the left eye from in front. There are operators who always operate from behind, and who, for that reason, must use the right and left hand alternately. The great objection to this position is that the surgeon must bend over the patient, which certainly is not favorable for proper asepsis of the wound.

Iridectomy.—In the event of hemorrhage in the anterior chamber, by which the field of operation is obscured, it may be necessary to seize

FIG. 108.—Blunt hook.

the iris without seeing it. With an intractable patient who does not look down, or rolls the eye, a blunt hook (Fig. 108) may be substituted for the forceps with which to withdraw the iris. The eye is almost never fixed during the iridectomy, as the fixation invariably causes the wound to gape.

If, after the iris is in the grasp of the forceps, the patient suddenly moves his eye or head, there may ensue a separation of the iris at its ciliary margin unless the operator is quick enough to open the forceps. As a rule considerable hemorrhage occurs, which greatly adds to the difficulties of continuing the operation. The operator should therefore open the forceps and release the iris as soon as the patient begins to move the eye.

If the iris should be cut during the incision, and the excised portion

remain in the anterior chamber or in the wound, it must be removed. If it should be connected with the rest of the iris, it has to be excised at the point of attachment. Only the periphery of the iris may have been cut by the knife, so that a bridge-shaped coloboma, with a more or less wide portion of the pupillary margin, is formed. The bridge may be permitted to remain, as the cataract will either pass through the coloboma or tear it away.

Method of Wenzel.—If, following a severe iridocyclitis, cataract forms, and the whole posterior surface of the iris is bound to the lens, the extraction of the cataract is performed as follows, according to the method of Wenzel:

The knife is introduced as usual at the limbus, passes back of the iris, and pierces it again just before the counter-puncture is made. During the incision the knife in its upward passage opens the lens capsule and makes a broad cut through the iris. After expression of the lens, two converging incisions meeting in the pupil are made with de Wecker's scissors through the diaphragm formed of membrane, iris and lens capsule, and the circumscribed piece seized with fine iris forceps and drawn out. This forms a large upward coloboma. The pointed blade of the scissors remains in the anterior chamber, while the blunt point is behind the diaphragm.

Opening the Capsule.—We usually prefer the capsule-forceps to the cystotome, although, if the anterior chamber is filled with blood and the boundaries of the pupil cannot be seen, the forceps

Fig. 109.—Sharp tenaculum.

might easily grasp a fold of the iris by mistake and pull it out. In restless patients it is preferable to resort to the cystotome tenaculum (Fig. 109), and also if the pupil is narrow in an extraction without iridectomy, to avoid a possible seizure of the iris by the forceps.

In a greatly distended cataract, and a hypermature, complicated cataract with thickened capsule, the employment of the capsule-forceps will be influenced to a considerable extent by the condition of the capsule. If the lens is so swollen that the capsule is tense, a fold of it cannot be lifted up with the forceps, except by exerting more force than is safe. If the operator feels that he cannot grasp a fold of

capsule between the teeth of the forceps by gentle pressure, he should use the cystotome.

Should the capsule be thickened, it is an advantage to remove the anterior portion from the pupillary area, especially if it occupies the whole extent of the latter. It may happen that the thickened capsule offers more resistance than does a defective zonula, the fibers of the latter tear through, and the whole lens in its envelope is withdrawn from the eye. The operator must be prepared to assist in the exit of the lens by a downward pressure on the scleral wound-margin at the moment he sees the lens yielding. This is done in order to remove the obstacle presented by the sclera, so that the capsule may not finally rupture and leave the half-luxated lens behind in the eye. If the patient is quiet and the vitreous of normal consistency, a prolapse of the latter does not of necessity occur, but sometimes it cannot be avoided. Should extraction with the capsule succeed, the result is excellent, as the pupil is free of all remnants of tissue.

Expression of the Cataract.—If the pressure through the lower lid is made too high up, perchance against the middle of the cornea, the operator will wait in vain for the appearance of the lens in the wound. However, even with pressure made in the proper direction and with the proper degree of force, the cataract may fail to appear in the wound. This may be due to a small incision, to resistance of the sphincter, to failure to open the lens capsule, or to subluxation of the lens.

If the wound is too small, which is shown by the lens pressing against the wound but not making its way through, the incision must be lengthened either at one or both ends with a small pair of curved, blunt scissors, one blade of which is carefully pushed into the angle of the chamber between the cornea and iris, while the other blade remains on the outside of the eyeball. If shortness of the incision is the real cause that prevents the proper delivery of the lens, the latter easily slips out of the eyeball after the cut has been enlarged.

It may be that the incision is sufficiently long, but the lens nucleus is exceptionally large. In cases of black cataract, the incision should be made larger than usual at the beginning of the operation. A cut which is too short, because made too far into the cornea, presents still another factor which may hinder the exit of the lens. The further the incision in the cornea is removed from the limbus, the more must the edge of the lens rotate forward to present in the wound. That is,

the greater the force which the operator must exert on the eye, the more danger there is of prolapse of the vitreous. Therefore, the only remedy is to prolong the incision by making lateral cuts along the limbus, and the same procedure is indicated if it is too short, on account of being made some distance between the corneal lamellæ.

Should the operator not be certain of having sufficiently opened the capsule, he should introduce the forceps a second time or have recourse to the cystotome.

Dislocation of the lens, usually a slight subluxation upward, may be due to traction of the forceps on the capsule, to pulling too strongly on the tunics of the eyeball during the incision, or to the pressure having been exerted in a direction which pushed the lens slightly upward instead of rotating it about its horizontal axis. It is therefore impossible to deliver the cataract, as the pressure made by the finger falls only on the vitreous, and has no longer any influence on the position of the lens. The latter does not rotate its margin into the wound, and any increase of the pressure simply forces the vitreous into the opening, and at the same time completely luxates the lens backward. The removal of the lens can then only be accomplished by returning it to its original position, which may be done by introducing a spatula into the anterior chamber and bringing the instrument into contact with the anterior surface of the lens, pushing it downward into its normal position. After this maneuver the expulsion of the lens may be accomplished.

If the lens becomes luxated in any direction other than upward, for example, internally or externally, it must be extracted either with a loop or a double tenaculum.

When the lens nucleus has become considerably diminished in size, as is frequently seen in complicated cataract and invariably in overripe cataract (Morgagnian cataract), delivery is also difficult. Pressure is useless if the lens is not normal in position and size. If the cortical substance has liquefied and pours out after the anterior lens capsule has been opened, the small nucleus either sinks down to the bottom of the capsule sac or is carried slightly upward behind the iris by the escaping cortical matter. In neither instance is it possible through the regular expression to influence the position of the lens nucleus. If the lens lies far down, it may be gradually worked upward by gentle stroking movements, and finally delivered with Daviel's spoon. If, however, it has been pushed up behind the iris, it must be

first stroked down by means of the spoon into the pupil and from there guided upward out of the wound.

Prolapse of the vitreous usually occurs during the act of expressing the cataract, but it may happen in any stage of the operation. It is of less significance when it ensues after the removal of the lens, and at that time it is best to do nothing further than make sure that the corneal flap remains in its proper position, and is not bent forward through the pressure which the vitreous exerts from behind. To undertake a reposition of the iris is not advisable, as by doing so there would only be caused further protrusion of the vitreous. The best procedure, therefore, is to close the patient's eye as soon as the vitreous appears,

FIG. 110.—Weber's loop.

and guide the upper lid over the flap with the assistance of the spoon held beneath the lid. As the protrusion of the vitreous causes pain, the patient usually winces, which may cause still more vitreous to be lost. Moreover, it is easily possible for the upper lid to fall into the open wound and to turn the flap forward.

After the patient has closed the eye, the upper lid is slightly raised by means of the eyelashes, the lower lid drawn away from the eye, and the position of the flap inspected, and, if necessary, smoothed out by a spatula. After this, the patient should not be allowed to open his eye, and both eyes are closed by a bandage.

FIG. 111.—Reisinger's double tenaculum.

If the vitreous appears prior to the removal of the lens, and the iris has not as yet been excised, an iridectomy can be performed only if the iris has floated into the wound and can be seized readily by the forceps. If, however, the iris has not fallen forward, any attempt to seize it with the forceps must be hopeless, as the instrument picks up only the vitreous. The iris has floated backward under the ciliary body, as shown by the large upward coloboma.

Continued efforts at expression after appearance of the vitreous cause further prolapse. Extraction of the lens in its capsule must be resorted to, and for this purpose, either a loop (Weber's), Fig. 110,

or a double tenaculum (Reisinger's), Fig. 111, is employed. The former is preferable for the inexperienced.

The loop (Fig. 110), directed *obliquely backward* (Figs. 112 and 115), is introduced through the wound until it reaches a position in the middle of the vitreous and about opposite the posterior pole of the

FIG. 112.—Introduction of Weber's loop. The loop is directed backward through the gaping wound behind the lens into the vitreous. The assistant holds the upper lid well-fixed with the thumb of the right hand and has the spoon in the left hand ready, after the extraction has been completed, to guide the upper lid down over the gaping wound. The operator himself fixes the lower lid.

lens. It is then carried forward (Figs. 114 and 116), so that the lens is pressed against the posterior surface of the cornea and forced out between the cornea and the instrument; in other words, it is lifted out of the eye by the loop.

Reisinger's double tenaculum (Fig. 111) is inserted closed in a similar manner, and, in order that the points may not become entangled in the edges of the wound, it is held with the plane of the bent portion parallel to the wound, therefore, in a frontal direction. Not until it is found to be behind the middle of the lens, is it rotated about 90° on its long axis, so that the points are now directed forward. The two arms are then separated and sink into the posterior surface of the lens, which is now pressed against the posterior aspect of the cornea and in this manner withdrawn from the eye. This instrument, therefore, can only be used when a firm lens-nucleus is present. If the nucleus is soft, the loop is recommended, as the tenaculum would cut through the soft mass without bringing it out.

Both the instruments must be carried backward into the vitreous in an oblique manner, for the reason that if held vertically, they would push against the margin of the lens and produce a luxation into the vitreous. During the entire manipulation, the lids must be drawn away from the eye in order to avoid pressure on the globe. The upper lid is



FIG. 113.—Desmarres elevator.

raised by means of a Desmarres elevator (Fig. 113). In every cataract operation the loops and tenaculum should be sterilized and ready for use, as the vitreous occasionally prolapses unexpectedly.

The greater the dexterity of the operator, the rarer will vitreous prolapse in uncomplicated cataract. Severe straining, holding the breath, etc., by the patient may be responsible, while the surgeon may induce it by undue pressure on the eye with the forceps during the incision, in delivery of the lens, or in forcing out the lens remnants. Quite unavoidable often is the prolapse in the presence of complicated cataracts, when the zonula is ruptured, or the vitreous has lost its normal consistency.

Prolapse of the vitreous is a most serious complication, and it is absolutely necessary to recognize at the right time whether a prolapse is imminent, and, if so, to prevent it if possible.

Several phenomena are associated with prolapse of the vitreous:

1. Very characteristic is the forward bulging through the pupil and

coloboma of the vitreous while the hyaloid membrane is still unruptured. If, after the expression of the cataract, the pupil and coloboma are filled with grayish lens remnants which suddenly separate at one point, and the pupil in this locality becomes a deep black, we have the first sign that the vitreous, still contained within its uninjured membrane,

FIG. 114.—Use of Weber's loop. The loop has been placed upright in such a fashion as to press the lens against the posterior aspect of the cornea and can now be drawn along the latter and out of the eye.

has pushed forward and penetrated the tissues in front. No experienced operator will continue to exert pressure to remove the remaining lens particles, for the rupture of the hyaloid membrane will occur the next moment. One should be satisfied with carefully stroking back the iris, and this is possible only when the patient remains quiet, but unfortunately the iris often is prolapsed again by the vitreous.

2. The same bulging forward of the vitreous in the unruptured hyaloid membrane may also occur, with a simultaneous marked deepening of the anterior chamber. A hernia of the vitreous presses at the same time through the pupil into the anterior chamber, filling it out and pushing back the iris.

3. Another characteristic sign is the deepening of the anterior chamber in consequence of the accumulating vitreous, which has already poured in through a rupture in the hyaloid membrane. This is followed by an outflow of the vitreous through the wound. The first

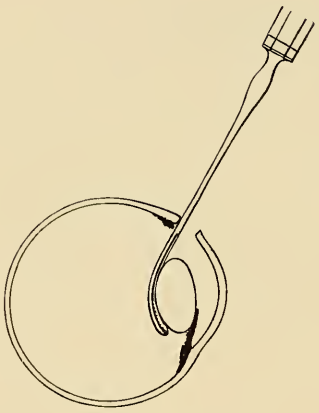

FIG. 115.

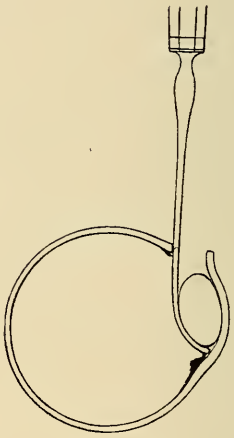

FIG. 116.

FIG. 115.—Diagrammatic representation of the introduction of the loop. The loop is directed backward obliquely.

FIG. 116.—The loop is raised and the lens pressed against the posterior wall of the cornea.

indication of the vitreous in the anterior chamber is manifested by the changes in the color and coagulation of the blood after it has been mixed with vitreous.

Deepening of the anterior chamber may also be produced by the entrance of air, but as the air-bubble is always clearly seen, it cannot be confounded with the appearance just described as due to the vitreous. The air in itself is not harmful, but it may so disturb the apparent relations of the anterior chamber, especially the position of the margins of the iris, that an attempt should be made to remove it from the eye by massage.

4. If the lens is still in the eye, the tendency to vitreous prolapse is

indicated by eversion of the edges of the wound, or gaping of the entire cut.

During peripheral incisions the hyaloid membrane may rupture in the region of the wound, and the vitreous extrude through the widely gaping wound, without any previous sign whatever having been noticed in the anterior chamber.

If the vitreous is perfectly fluid, it will ooze steadily from the eye immediately after the incision, without any gaping of the wound. Great loss of fluid is recognized by collapse of the eyeball. As this precludes regular extraction of the lens, the loop or tenaculum must be resorted to. On the whole, the loss of perfectly fluid vitreous is in general much better tolerated than the loss of the normal vitreous. In a few hours it is replaced by new fluid, by which the eye is restored to its normal tension. The wound heals smoothly, but after the loss of normal vitreous, the cicatrix remains ectatic for a long time.

In instances in which the protruding vitreous repeatedly turns the corneal flap forward, and it cannot be permanently replaced with the spatula, the wound-edges should be united with two or more silk sutures.

The sequelæ of prolapse of the vitreous include attachment of the margins of the iris to the wound, cystic scars, glaucoma, and chronic iridocyclitis. Hemorrhage into the open vitreous chamber leads to opaque membranes, either floating or hanging from the point of attachment. Detachment of the retina occurs only after great loss of vitreous, except in an eye especially predisposed (myopia, etc.).

Several other accidents during the cataract operation remain to be mentioned.

The lens may be displaced back into the vitreous chamber, either spontaneously or through the unskillful manipulation of the operator. Any attempt to recover it is useless and results only in further injury to the eye. The operation has to be stopped and the eye bandaged. Iridocyclitis often follows.

The so-called **collapse of the cornea,** which is occasionally met with in very old patients immediately after completing the incision, is of absolutely no importance.

Expulsive hemorrhage is fortunately an infrequent complication. It rarely occurs during operation, but usually appears suddenly several hours afterward; it is seen not only after extraction complicated by the loss of the vitreous, but also following normal operations. The

hemorrhage is retrochoroidal and is so extensive that the vitreous, choroid and the retina are driven outward through the wound. Immediate enucleation spares the patient a long period of suffering. Unfortunately, we have no means to prevent this accident; indeed, we do not even know of a single symptom which will afford warning of the danger before the operation. As associated factors the following must be taken into consideration: the sudden lowering of the intraocular pressure caused by the operation; the rigidity of the external tunic of the eye; arteriosclerosis and the concomitant tendency of the blood-vessels to rupture; and increase in blood-pressure during the operation on account of the increased activity of the heart due to the excitement of the patient. To at least exclude the last factor, Fuchs gives those patients who have lost one eye through an expulsive hemorrhage, a large dose of bromids (2 grams) before the operation. The danger that hemorrhage may follow extraction of a cataract from the other eye is not sufficiently great to warrant the operator in performing a depression of the cataract into the vitreous humor after the old method instead of the usual extraction.

Kalt Suture.—Before the corneal incision is made Kalt introduces a fine, sharp, perfectly round, curved needle, with fine silk, through the cornea in the upper vertical meridian close below the limbus, and brings it out on the border of the limbus without entering the anterior chamber. The needle is then passed through the conjunctiva and episcleral tissue 1 mm. above the limbus. The loose loop of the thread between the two stitches is laid inward toward the nose, so that it is not injured by the knife as the cataract incision is made between the two needle openings. After extraction of the cataract the thread is knotted. The great advantage of the suture is that it corrects gaping of the wound, particularly after escape of vitreous, and prevents sudden gush of aqueous with prolapse of iris in the wound, although not entirely guarding against this accident in simple extraction. In instances where complications are anticipated the application of the Kalt suture is to be recommended.

Kuhnt Conjunctival Flap.—This procedure is valuable in extraction complicated by gaping of the wound and a tendency to slow healing, which often follow corneal incisions. The conjunctiva, close to the limbus, is incised around the upper half of the cornea with a small pair of curved scissors, and the membrane undermined for a short distance from the limbus. A curved incision is then made through

the conjunctiva a short distance above and parallel with the limbus, forming a conjunctival flap, which is to be drawn down by sutures to cover the extraction incision (Fig. 157). These two sutures are entered through the lower margin of the bridge of conjunctiva near the two attached ends and are fastened further down on the conjunctiva of the globe. The tying of the two threads covers the operative wound entirely with conjunctiva and brings the wound edges in apposition. The conjunctival bridge, which at first covers the entire portion of the cornea, draws back to its normal situation in several days.

The conjunctiva can be drawn down over the wound incision apron-like, as shown in Fig. 158, without the necessity of making the second incision to form the detached bridge.

The Kuhnt flap may be made prior to the cataract incision if a complicated operation and course of healing is anticipated, as in restless patients, and also in exophthalmos and incomplicated cataract.

COMPLICATIONS DURING HEALING.

Delayed Closure of the Wound.—In twenty-four hours usually the wound is found to have closed, and the anterior chamber restored. Occasionally, however, the wound is not healed for days or weeks. Delayed healing is often due to lodgment between the lips of the wound of lens remnants, particles of iris, and particularly shreds of capsule. It is therefore important that in opening the lens capsule with the forceps that the membrane should be detached from all sides before the forceps are withdrawn, otherwise the attached upper portion of the capsule may be drawn into the wound. Protrusion of the vitreous, indicated by gaping of the wound, may be a cause.

A corneal incision contributes to slow wound closure. In the healing of the cornea, the epithelium usually sinks into both borders of the cut, and, as surfaces covered with epithelium do not unite, the two edges are only loosely adherent and readily reopen. The wound presents the appearance of a shining groove.

Restlessness and coughing cause the aqueous to be repeatedly forced out of the wound, and prevent its healing. Prolonged cocainization has also been blamed for delayed restoration of the chamber.

The closed wound may reopen after a few days without apparent cause. An ophthalmoscopic examination will show the brownish elevated areas in the periphery of the fundus characteristic of choroidal detachment.

In many instances no explanation can be given of the failure of the wound to unite. If a shred of capsule is recognized between the wound-edges, an attempt may be made to remove it.

Prolapsed iris is not uncommon after simple extraction. Also, after iridectomy, one or both of the iris pillars may be caught in the corners of the incision or at least are higher than they should be. Occasional protrusion of the vitreous prevents proper reposition and crowds the iris continually toward the wound, or a restless patient may cause periodic gushes of aqueous through the wound, washing between its edges the previously properly-replaced iris. If the iris lies exposed in the wound immediately after operation, it should be excised, but if not caught sufficiently to permit excision, no attempt to remove it is to be made. Eserin is of no value to draw the edges in proper position.

Eversion of the Corneal Flap.—On the day after the operation, the corneal flap may be turned downward, because the patient with a gaping wound opens the eye beneath the bandage, and the upper lid enters the wound. After instilling cocain-solution the flap must be carefully stroked upward and brought into its proper position. Unless infection ensues, which, however, is a likely result, the eye need not be considered as lost. For a long time a straight white line remains as a sign of the corneal injury.

Lens Particles in the Pupil.—Lens cortex in the pupil becomes opaque a few hours after operation. It is of little significance unless operation was complicated by loss of vitreous. Atropin is to be used to keep the pupil dilated, and later dionin to accelerate absorption.

Blood in the Anterior Chamber.—Hemorrhage during operation will be most likely to occur if the incision is some distance back of the limbus in the sclera, although a correctly-placed wound may give rise to troublesome bleeding in persons with diseased blood-vessels. Attempts to remove the blood by massage are sometimes successful, but after recurring hemorrhages a firm, tough coagulum forms in the anterior chamber that cannot be expressed. Most of the blood will have disappeared by the following day, the portion left forming an insignificant hyphemia or a thin layer over the iris and pupil. The use of atropin is all that is required. Occasionally hemorrhage follows the breaking open of the wound under the dressing.

Iridocyclitis and increased tension are also factors in causing hemorrhage. The bleeding repeatedly recurs, and, owing to the slow

absorbing power of the inflamed eye, contributes to the formation of a membrane in the pupil.

Cloudiness of the Cornea (Striped Keratitis).—On the first few days after operation there is often found in the upper half of the cornea a number of vertical lines or stripes. In rare instances the cloudiness is intense, and may spread over the entire cornea in large gray polygonal areas between which transparent stripes run in different directions. The more difficult the expression of the lens, whether because of the size of the nucleus or shortness of the incision, the greater is the cloudiness. It usually disappears during the first two weeks after operation, but in exceptional cases it may be the origin of degeneration of the cornea.

Post-operative Delirium.—This is a rare complication in our clinic, and is prevented by allowing the necessary quantity of alcohol to drinkers and by keeping the non-operated eye unbandaged in nervous and excitable persons. The omission of the bandage from this eye in most cases removes all anxiety, and the patient will spontaneously keep the lids of the eye closed.

Pain.—With the disappearance of the cocain anesthesia there is a slight and transient burning. It is advisable to inform patients of the discomfort that will come with the return of the normal sensibility of the cornea, so that they will not be unnecessarily alarmed. Severe burning and irritation may follow erosion of the cornea due to prolonged application of cocain or failure to keep the lids closed during its instillation. Retention of tears in the conjunctival sac from spasm of the lids is also a cause of unusual pain. The surgeon should not consent to remove the dressings on the day of operation unless the severity of the pain indicates that something is radically wrong. Nervous patients are prone to magnify their ailments, particularly after an operation on the eyes.

Pain on the second or third day after operation indicates sudden breaking open of the wound or beginning iridocyclitis. It usually appears at a time when clinically there are as yet no symptoms of an iridocyclitis. The pain is often localized not only in the eye but also in the forehead on the side of the operated eye. Frequently ciliary injection is the only objective symptom. Under these circumstances, aspirin should be administered internally, and atropin locally, especially if the pupil is not sufficiently dilated.

Rupture of the Wound.—This accident results from muscular

straining, restlessness or traumatism, and is more common in large clinics than when the patient is under the constant watchfulness of an attendant. The parts adjacent to the wound become suffused, blood collects in the anterior chamber, and the iris may be prolapsed, with vitreous in the wound. The prolapsed iris must be excised, atropin instilled, the bandage reapplied, and the patient kept absolutely quiet.

Signs of Inflammation.—The external signs of inflammation vary considerably even in eyes that follow an uncomplicated course in healing. While some remain quite pale, the majority show moderate ciliary injection, and others present decided engorgement of both the conjunctival and ciliary vessels, types of irritation not explainable alone by conjunctival catarrh or iritis. Anemic individuals usually have pale eyes after operation, while plethoric persons with dilated vessels of the face incline to hyperemia. The ordinary inflammatory complications are as follows:

Infection.—Suppuration usually occurs during the first two or three days, but may be delayed for a week—the so-called secondary infection. Acute infection may be due to unclean instruments, imperfectly sterilized solutions, or the entrance of germs from the conjunctiva into the wound.

The picture of beginning infection varies. Usually on the day after operation there is noticed some edema of the eyelids, the gauze dressing shows a streak of yellow discharge, a suppurative exudate lies between the swollen lids and accumulates in the inferior culdesac in the form of yellowish, cloudy flakes, and the wound has a gray or yellow coating. The anterior chamber has usually reformed, and the iris and pupil may be normal. In a few hours the inflammation increases. An abundant muco-purulent discharge accumulates in the culdesac, the entire wound is infiltrated with a grayish material, and fine yellowish lines pass from the cut into the adjacent corneal layers or run in cloudy threads into the anterior chamber. The process slowly or rapidly advances, depending on the virulence of the infection, until all the signs of a suppurate iritis appear, with later possibly panophthalmitis. The cornea adjacent to the wound may become purulently infiltrated, or a ring abscess may form.

If the infection proceeds from the anterior chamber, the conjunctiva and wound may at first remain normal, and the disease begin with symptoms of suppurative iritis—discoloration of the iris, cloudiness of

the aqueous, hypopyon, and a yellowish exudate in the pupil and coloboma.

Acute suppurative infection does not always follow the destructive course which has been outlined. Often the disease is beneficially affected by treatment, and the inflammation gradually subsides, not without, however, leaving a coarse membrane in the pupil and coloboma.

Treatment.—Therapy is almost powerless against a severe infection, but if recognized early prompt measures may be of service in checking the spread of the disease. If limited to the wound, immediate cauterization with carbolic acid or the actual cautery should be made, and the conjunctiva frequently douched with 1–3000 bichlorid of mercury solution. Repeated sub-conjunctival injections of solutions of bichlorid (1–2000) or cyanid of mercury (1–5000) seem to act favorably in some cases of infection arising in the anterior chamber. Nothing can be expected from serum injections. The opening and washing out the anterior chamber with physiologic salt-solution is almost always fruitless. Besides these measures, the energetic use of atropin, dionin in powder form, and hot compresses should be employed.

So long as light-projection is preserved, the case should not be considered hopeless. It is only after the perception of light is lost that all chance is gone of preserving vision. If panophthalmitis appears unavoidable, enucleation is indicated to relieve the patients of weeks of suffering; but should sudden increase in the edema of the conjunctiva and lids point to infection having already begun in the vitreous, the proper course is to excise the cornea and allow free egress of the pus.

Iridocyclitis.—Slowly beginning inflammation of the iris and ciliary body is also due to an infection with microörganisms, and may start a few days or a week or more after the extraction with pain in the eye or in the forehead and with pericorneal injection. Under proper treatment these symptoms subside in most instances, leaving the eye unimpaired, or they may progress to the severe type of iridocyclitis, in which the cornea becomes stippled, the aqueous clouded, the iris discolored, the eye tender on pressure, and the pupil and coloboma veiled with a fine web-like exudate. Even in these severe types of inflammation, the eye may slowly recover, with preservation of useful sight. If the ciliary body is chiefly affected, the induration extends to the choroid, the vitreous is clouded, the retina becomes detached, and the eyeball ultimately shrinks. This form of iridocyclitis is feared, not alone because of the possible complete loss of light-perception, but

of the danger of affecting the other eye. There are no means of recognizing clinically the type of iridocyclitis that may cause sympathetic disease, so that, if light-perception fails and no hope for sight remains, the surgeon should not delay in urging the patient to consent to the removal of an eye which is both useless and dangerous.

Treatment.—From the beginning of the inflammation atropin is to be employed regularly, leeches to the temple, hot compresses and dionin, and internally aspirin and small doses of calomel. A course of pilocarpin sweats with mercury inunctions sometimes exerts a favorable influence. In the progressive types of uveal inflammation therapy is unfortunately powerless to stay the degenerative processes.

In the favorable cases, upon subsidence of the inflammation, the coarse membrane which occludes the pupil reduces vision to the perception of light, and necessitates iridotomy. The operation must not be undertaken until all signs of irritation have subsided, usually four to six months after disappearance of the inflammation. Early operation is followed by a relapse, and the opening made in the mass in the pupil is closed by blood or by granular tissue which develops from the edges of the incised area. So long as the patient complains of occasional pain, or there are periods of inflammation, even though hardly more than injection of the ciliary vessels, operation must be deferred.

Secondary Infection.—If a cystic scar remains after operation, either from healing in the wound of the iris or a shred of capsule, infection may occur months or years afterwards, and follow the course of a slight iritis to a well-developed panophthalmitis.

Increased Tension.—An attack of acute glaucoma may occur during the first few days after operation. The diagnosis is not easy, as the intense pain, chemosis, swelling of lids, and cloudiness of the cornea simulate an incipient infection, and especially as it is difficult to test the tension of the recently-operated eye. The cause of the increased tension after an uncomplicated extraction is problematical, especially in instances in which the pupil is free of any cortical remains.

In extraction complicated with considerable loss of fluid vitreous, even with no incarceration of the wound, there may follow irregular attacks of pain, slight dulness of the cornea, and increased tension, indicating mild glaucoma. Miotics usually restore the tension to normal in a few days. It is only in rare instances that paracentisis of

the cornea is performed, because of the risk of inciting a postoperative increase in tension.

Increase of tension which occurs a considerable time after an extraction complicated with healing of the iris in the wound is readily explained, but it is somewhat difficult to account for the glaucoma symptoms after operation with a correct coloboma or with a round pupil.

A rare form of glaucoma, not benefitted by treatment, follows the growth of epithelium through the wound into the anterior chamber. Clinically, epithelial-cell lining of the anterior chamber is only recognized when the membrane covers a part of the cornea and is reflected cyst-like upon the anterior surface of the iris. Should there be a uniform epithelial lining of the entire chamber, it can only be suspected but not with certainty diagnosed.

CHAPTER XI.

CATARACT (continued).

DISCISSION.

Indications.—Discission is performed: (1) in the treatment of congenital cataract; (2) in the treatment of high myopia; and (3) in the treatment of after-cataract (secondary cataract).

The incision is made either through the cornea or the sclera with discission knife needles, which have convex or concave cutting edges.

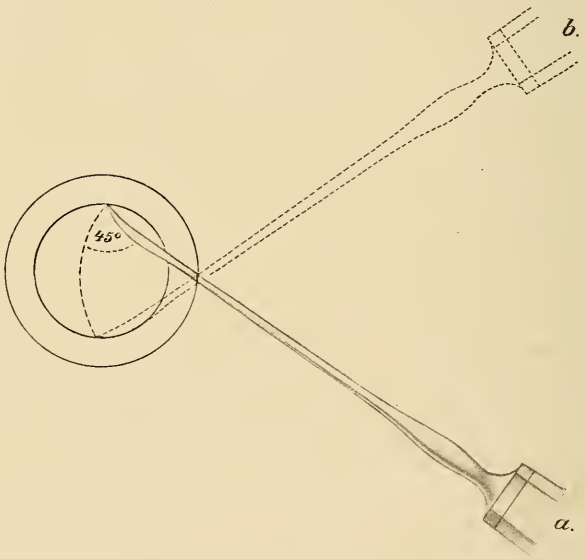

FIG. 117.—Discission through the cornea. Diagram showing how the vertical incision is made in discission through the capsule of the lens. The handle of the needle is lowered, thus bringing its point into such a position (a.) that it lies near the upper margin of the pupil. Next, while the needle inclines to the plane of the lens capsule at an angle of about 45 degrees, the handle is elevated from a. to b., thus making a vertical incision through the capsule.

The shank of the knife should have a diameter that will close the opening made by the blade, and prevent escape of the aqueous.

Discission of Congenital Cataract.—(Figs. 117 and 118).—After the pupil has been dilated with atropin, the eyeball is fixed and the

cornea pierced on the outer side near the limbus (Fig. 117). The operation on the right eye is performed with the left hand, and on the left eye with the right hand, the operator in each instance sitting to the right of the patient. The pupil is dilated to expose a large area of the anterior lens capsule, and particularly to protect the iris from injury.

The knife needle, held between the thumb and the first and second

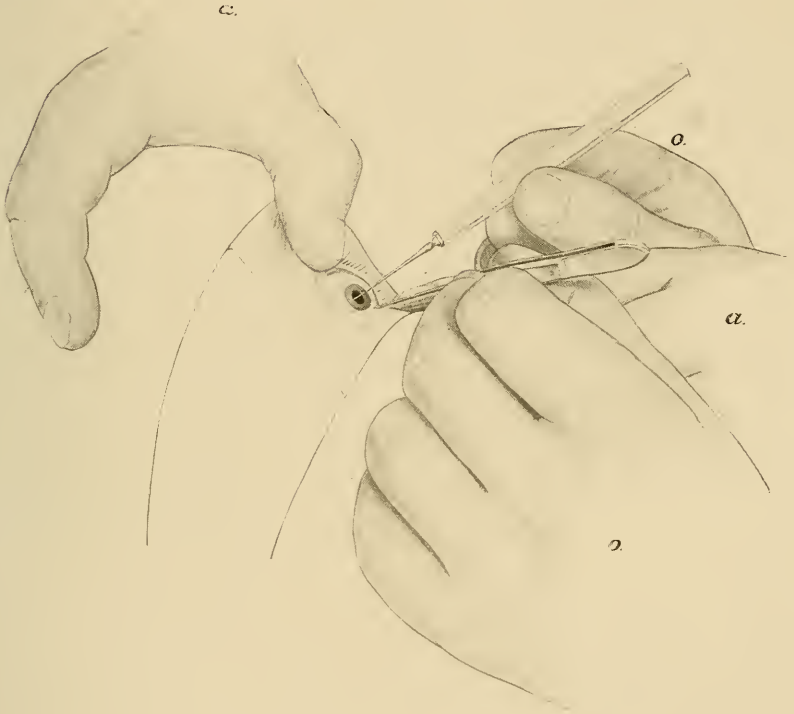

FIG 118.—Discission through the cornea. The eye is fixed below at the limbus by forceps. With the discission needle held in the right hand, when the left eye is operated on, the cornea is perforated at the limbus, and a horizontal incision is then made through the anterior lens capsule.

fingers, with its handle resting upon the base of the phalanx of the forefinger, perforates the cornea to the outer side near the limbus, about the horizontal meridian, and is pushed forward and upward, until it reaches the upper margin of the pupil. Using the corneal perforation as a fulcrum, the handle of the instrument, inclined at an angle of about 45 degrees with the capsule, is moved from below upward, describing an arc of about 90 degrees, and the blade cuts through the

capsule and anterior lens fibers. The handle is now depressed, and the knife point brought to the inner margin of the dilated pupil, and entered through the capsule in the horizontal meridian. The handle is then raised through an arc of about 45 degrees, and, with the corneal perforation still as a fulcrum, the knife blade makes a horizontal incision through the capsule (Fig. 118). In order that the point does not sink too deeply and injure the posterior capsule, the needle is withdrawn slightly while making the cut and finally quickly pulled out of the eye in the same direction in which it was entered.

The knife needle may be entered either in the outer part of the cornea, in the limbus itself, or even beyond it in the sclera. In entering through the sclera the needle is pushed forward slightly under the bulbar conjunctiva before the perforation is made. This produces immediate closure of the perforation-wound, as the opening in the conjunctiva and that in the eyeball occupy different positions. Entering the knife through the cornea is preferable in those cases in which, because of a shallow anterior chamber or a pupil which has remained small in spite of atropin, an injury to the iris is to be feared if a peripheral incision is made.

We prefer a crucial incision of the capsule, because a permanent opening is thereby assured. The four flaps retract, so that a healing of the wound in the capsule is prevented. If only a single incision is made, closure of the wound not infrequently occurs. On the other hand more than two incisions are superfluous.

Discission is the only safe operation in congenital total cataract of children. It is preferable to linear extraction, as no extreme precautionary measures are demanded and there is ample time to wait until spontaneous absorption of the lens has taken place. The latter progresses usually promptly and completely in young patients. Occasionally it may be necessary to perform discission a second or even third time. Not infrequently after discission of even shrunken cataracts in children, an increase in intraocular pressure develops, which usually disappears, however, within a few days by the use of eserin and cold compresses. Only in rare instances will puncture of the cornea be necessary, and the incision should not be longer than 2 mm. at the most, so that danger of prolapse of the iris may be avoided.

Discission for High Myopia.—Discission of a transparent lens is undertaken in high-grade myopia, only for the purpose of completely removing the lens. The immediate consequence of discission is a

traumatic cataract, and the rapidity with which this forms depends chiefly upon the size of the capsular wound. If only a single cut has been made, the opacity not infrequently remains limited to the tissue immediately surrounding it, as the capsular wound may close. Therefore, if after a few days the cataract should make no progress, the discission must be repeated and the capsule incised more freely. If the anterior lens capsule is well opened, total opacity of the lens quickly follows, and the anterior chamber is soon filled with lens substance.

During the period of swelling of the lens the pupil must be kept widely dilated by atropin. The development of the cataract is sufficient in itself to set up a state of intense irritation and ciliary hyperemia, and atropin not only hinders the formation of posterior synechia, but prevents increase of pressure and incarceration of the swelling lens substance in the narrowing pupil.

The swollen lens substance is rather slow in being absorbed, and many weeks may elapse before it entirely disappears, during which time the eye is in a state of constant irritation. Hence, we prefer after about fourteen days, by which time the entire lens has become opaque and soft, to remove the masses from the eye by an incision made with the lancet at the lower corneal margin. Provided the posterior lens capsule has not been injured by the discission, this trifling operation is performed without accident, especially as an incision 5 mm. long usually suffices.

The indications for the operation in high-grade myopia are as follows:

1. The degree of myopia must be more than 16 diopters; if the myopia is less than this amount the patients will require after operation convex glasses for distance vision and still stronger lenses for near vision. The difference in the refraction produced by the removal of the lens in myopia amounts to nearly 20 diopters on an average, as against 10 diopters in normal eyes.

2. The visual acuity of the eye to be operated upon must not have suffered too severely through intraocular changes, and must at least be one-sixth to one-quarter of the normal and not seriously disturbed by a central scotoma.

3. The patient's other eye must still be useful, that is, it must not have suffered detachment of the retina, severe choroiditic processes, or other diseases.

4. The operation is limited to patients under forty years of age.

Narrowing the foregoing indications down to these limits, the results obtained by the operation are on an average good. There is no doubt that eyes operated upon for myopia are especially prone to develop detachment of the retina, and the patient's attention should be called before the operation to all the possibilities of disaster, and especially should it be stated that the operation is no guarantee against the serious intraocular changes that usually occur sooner or later as a consequence of the high-grade myopia.

Complications of Discission.—These include operation upon congenital cataract and also upon the transparent lens for high myopia.

Escape of the Aqueous.—This is usually of small significance, but may be followed by adhesion of the iris to the place of perforation, with the formation of anterior synechia. Where the anterior chamber is of normal depth, the entrance of the knife needle at the limbus or slightly posterior in the sclera prevents escape of the aqueous and obviates all risks of infection, which sometimes follows puncture through the cornea.

Increased Tension.—Extensive incisions in the capsule and lens are not infrequently followed by rapid swelling of the lens. If tension increases and the pupil is not dilated sufficiently, it should be our first task to open the pupil as much as possible by thorough cocainization, followed by the application of dry atropin, and at the same time apply iced compresses to the closed lids. If the pupil is sufficiently dilated, we must not instill miotics with the hope of decreasing pressure. If the glaucomatous symptoms are marked, and do not disappear within 24 hours, the anterior chamber should be opened with the keratome, and the swollen lens removed.

Prolapse of the Vitreous.—The posterior lens capsule must not be injured in discission for either the opaque or the transparent lens. Should it be decided later to incise the cornea to permit the swollen lens particles to escape, prolapse of the vitreous immediately follows. This makes it impossible to massage the soft lenticular masses from the eye, as more vitreous would be squeezed out. The iris is likewise displaced from its proper position by the vitreous and remains permanently distorted. This accident may result from introducing the needle too deeply, and directing it too perpendicularly. On that account the needle should be made to glide obliquely through the substance of the lens during the vertical incision, and be drawn out of the eye during the horizontal incision.

Injury of the vitreous is especially to be avoided in the discission of the clear lens for high myopia. The vitreous is fluid in this refractive error, and no more injury should occur than the slight amount that must follow cutting the secondary cataract which develops through subsequent thickening of the lens capsule.

Discission of Secondary Cataract.—As a secondary cataract forms the only septum between the aqueous and the vitreous chambers, discission cannot be performed without some injury to the vitreous, which should be always as little as possible. Operation is performed with the pupil widely dilated, and with the condensed illumination of a lamp or other artificial light, especially in those cases with a glassy membrane in which the pupil occasionally appears quite black.

The same general directions given for discission of congenital cataract are followed in the operation for secondary cataract. If, after the first incision, a free space is noted at once, the needle must be withdrawn. Only when the first cut is without result is a second or third made in different directions, never penetrating the vitreous body deeply.

Complications.—If the pupil is held by posterior synechia, so that dilatation by atropin is impossible, the operation becomes more difficult, although an injury to the iris can be averted in consequence of the great depth of the anterior chamber.

If the membrane is tough and has become adherent to the margin of the pupil, it may evade the needle and be pushed back, the iris dragged or even separated at its ciliary attachment (iridodialysis); or it gives way to the knife by detaching itself from the iris at one point and becomes pressed backward like a lid, returning quickly to its original position in the pupil when the needle is drawn forward, so that the result of the operation is frustrated.

Discission with Two Needles (Bowman).—If we fail to incise the membrane by the usual method, it is necessary to employ two needles, one introduced from the outer and the other from the inner side of the cornea. The points of the knife needles enter close together through the center of the membrane, and by raising the handles of the instruments the needles are moved in opposite directions, tearing asunder (dilaceration) the membrane. Combined discission with one needle entered through the cornea and the other through the sclera may also be of advantage. The operation with the needle is suited for

cases in which the secondary cataract consists only of the capsule and the remnants of the lens.

If the capsular membrane contains a layer of connective-tissue, following an iridocyclitis, the needle is not sufficiently strong to freely divide it, and must be replaced by the Graefe knife. This operation is then called capsulotomy, or, if some of the iris is cut into at the same time, iridotomy.

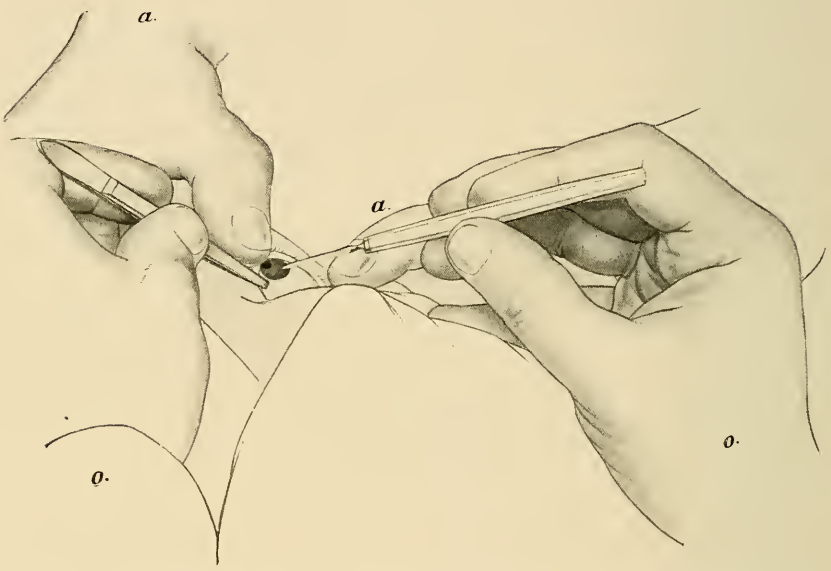

FIG. 119.—Iridotomy. The pupil is displaced upward by the scar resulting from the cataract operation, and is obstructed by a membrane. The patient is looking well upward; the eye is fixed at the side. The Graefe knife, directed obliquely upward, is introduced into the cornea in the vertical meridian rather close to the lower limbus; the edge of the knife is directed backward.

Iridotomy.—The application of iridotomy may be illustrated by a typical case. If, after an extraction with loss of vitreous, the pupil is drawn upward into the region of the dense scar and closed by a membrane consequent upon an iritis, the accompanying picture (Fig. 119) may be seen. Before any operative procedures are undertaken, it is necessary to make sure of good light-perception and light-projection, and also to wait until inflammation of the eye has completely subsided and the irritation of the eyeball, manifested by the appearance of mild ciliary injection, no longer exists. The contemplated operation must accomplish two purposes, namely, to clear

the pupil and to alter its position, so that it will come to lie behind the center of the cornea. It is not sufficient to simply cut the membrane in the pupil, but the incision must extend through the iris and the dense fibrous membrane which lies behind it. For this purpose the cornea is penetrated below by a sharp Graefe knife, the cutting edge of which is backward while the point is directed upward toward the pupil. A vertical incision (Fig. 120) from above downward is made through the pupillary membrane and the iris, producing a vertical fissure which extends to below the center of the cornea. Only a very sharp knife will divide the membrane without pulling on the iris. Immediately after division, the cut borders retract, and a broad, often triangular, opening is formed in the diaphragm. Iridodialysis may occur if the membrane together with the attached iris evades the knife and is pressed backward. It is frequently observed that the dense membrane is readily divided, while the delicate tissue of the iris escapes the knife, resisting all attempts to incise it.

FIG. 120.—Direction of the incision in iridotomy.

After the incision has been completed, the knife is withdrawn and pressure immediately exerted on the eye through the closed lids by means of the finger, and a pressure-dressing applied at once.

Hemorrhage.—This can occur not only from the cut vessels of the iris, if the latter has been incised, but also from division of the newly-formed vessels found in the dense fibrous secondary membrane. Such hemorrhage would make the final result of the operation doubtful, and in most cases render it worthless. From extensive experience we know how difficult of absorption is a hemorrhage in the anterior chamber in eyes affected by a chronic iridocyclitis. If after many weeks the blood gradually disappears, it will usually be found that the clear space obtained by the operation is again closed by a fibrous membrane formed by organization of the clot.

If pressure is exerted upon the eye as soon as the knife is withdrawn, and a firm bandage is applied at once, the risk of hemorrhage is lessened. The bandage may be replaced by the ordinary protective dressing six or eight hours later. By this time closure of the injured vessels has taken place, and a secondary hemorrhage need not be feared. The many published bad results of the iridotomy can usually be traced to neglect of the proper procedures for the prevention of hemorrhage.

The depth of the anterior chamber is not decreased by iridotomy, and a prolapse of the vitreous is impossible. The dressing may be removed as early as the day after operation, and rest in bed is not necessary. Provided that no serious intraocular conditions exist, such as dense vitreous opacities and retino-choroiditic areas, vision may become good. However, these complications are not infrequent, and the unsatisfactory results must not be attributed to the operation.

A vertical incision gives the advantage of cutting approximately parallel to the fibers of the iris without seriously injuring any of its vessels. The disadvantage of making the incision in the direction of the fibers of the iris arises from the fact that the cut shows no tendency to gape and sometimes exists only as a fine line, which soon closes completely through the accurate application of the wound edges. If a horizontal incision, running transversely to the direction of the iris-fibers, is used, we are able to make it at any height desired (therefore, exactly behind the center of the cornea), and in addition produce a broader gap through retraction of the iridal tissue. A horizontal incision, it is true, divides many more of the blood-vessels of the iris, and, therefore, the pressure-dressing must be applied to the eye with special rapidity after the incision has been made. If, however, as is not infrequently the case, the iris has undergone a fairly high degree of atrophy, a large number of the iridal vessels will have been obliterated and injury to them is of but little importance.

Should the result be unsatisfactory, there is no objection to an early repetition of the operation, provided that the eye is not irritated.

The foregoing method of iridotomy is the only operation we employ in cases of complicated secondary cataract. Its superiority over the discission after de Wecker consists in not opening the anterior chamber, thus making a loss of vitreous impossible, in its greater rapidity, in the careful handling accorded to the iris, and in the almost invariable satisfactory result, if such an issue of the operation is at all possible.

Discission through the Sclera (Fig. 121).—This operation is adapted only to secondary cataract. The needle should be stronger than that ordinarily employed for discission through the cornea. By entering through the sclera, there is the advantage of being able to use more force in dividing the membrane than is possible by the operation from the front.

To avoid various unpleasant complications, the perforation with the needle must be made posterior to the ciliary body, that is, at a

distance of at least 6 millimeters from the limbus, and either above or below the horizontal meridian, so as not to injure the posterior long ciliary artery. It is easier to enter at the outer and inferior side, while the patient looks upward and inward, and the eye is held in this position by forceps. The needle is directed forward and pushed through the membrane in the pupil so that the point appears in the anterior chamber (Fig. 121). By elevating the handle of the instrument the membrane is divided. In order not to injure the vitreous more than is necessary, as few cuts as possible are made. If, after the first

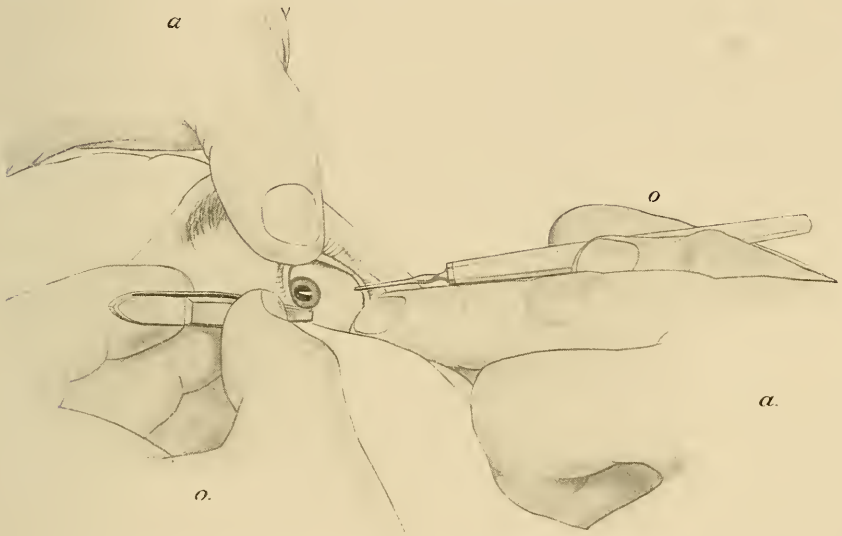

FIG. 121.—Discission through the sclera in the left eye. The discission-needle is introduced from the outer and lower side and pushed forward through the sclera, at a distance of at least 6 mm. from the limbus. The secondary cataract is pierced, so that the point of the needle appears in the anterior chamber. Lastly, the membrane is divided by bringing the needle into an erect position.

cutting movement, a black space is seen to appear in the membrane, the needle is quickly withdrawn from the eye. Only in case the first incision fails to produce a free opening, and simply depresses the membrane so that it springs back again into the pupil, must a second or third attempt be made to incise it. The injury to the vitreous incurred by this method is no greater than when the operation is performed through the cornea. In all cases of secondary cataract injury to the vitreous cannot be avoided.

A great advantage of this operation is that the surgeon is able to

move the needle in a larger area of excursion than when the needle must be pushed perpendicularly through the cornea into the deep anterior chamber. The latter procedure leaves very little freedom of motion. After discission through the sclera, complications such as increase of intraocular pressure and cyclitis are common. The former usually disappears within a few days under the use of eserin and cold compresses. In most cases the cyclitis is also a transient phenomenon.

LINEAR EXTRACTION.

Linear extraction is employed for the removal of soft cataract, the thirty-fifth year being approximately the upper age limit; as a secondary operation after discission of total cataract of young adults; for glaucoma which may occur from rapid swelling of the lens after discission; and for the removal of traumatic cataract.

Extraction of Soft Cataract.—The operator sits to the right of the patient, and uses the right hand for either the right or left eye. The fixation is made at any suitable point, and the keratome is held in the same manner as described for the incision for iridectomy (Fig. 122). After dilatation of the pupil with homatropin, the lancet is applied rather perpendicularly below and exactly at the limbus, and, as soon as the point has entered the chamber, the blade is turned parallel to the iris (Fig. 123), and, without either forward or backward pressure, pushed in until the incision has reached the desired length, 6 to 8 mm. If the iris is well retracted, it is not exposed to any danger of injury. As with all cuts which open the anterior chamber, the instrument must not stop in its progress, otherwise escape of the aqueous humor would render impossible a further lengthening of the incision. The lancet is slowly withdrawn from the eye so that the aqueous humor escapes gradually. At the moment the anterior chamber is emptied, the pupil either becomes narrow, or the iris floats into the wound by the aqueous humor.

Opening the Lens Capsule.—We prefer the use of the capsule forceps, as described under the operation for senile cataract. They must be slightly raised after they have entered the pupil, so that the posterior untoothed part of the closed blades does not seize the iris. With a relatively short incision and a narrow pupil it may be difficult to use the forceps, and the pointed cystotome is to be employed to incise the capsule several times, without, however, making pressure, or the lens will be dislocated.

Removal of the Lens.—If the cataract is soft, it suffices to merely depress the scleral wound-margin slightly by means of the spoon, in order to allow the soft mass to slide out through the gaping wound. If, at the same time, the cataract is gently stroked from above downward with another spoon against the cornea (Figs. 124 and 125), the escape

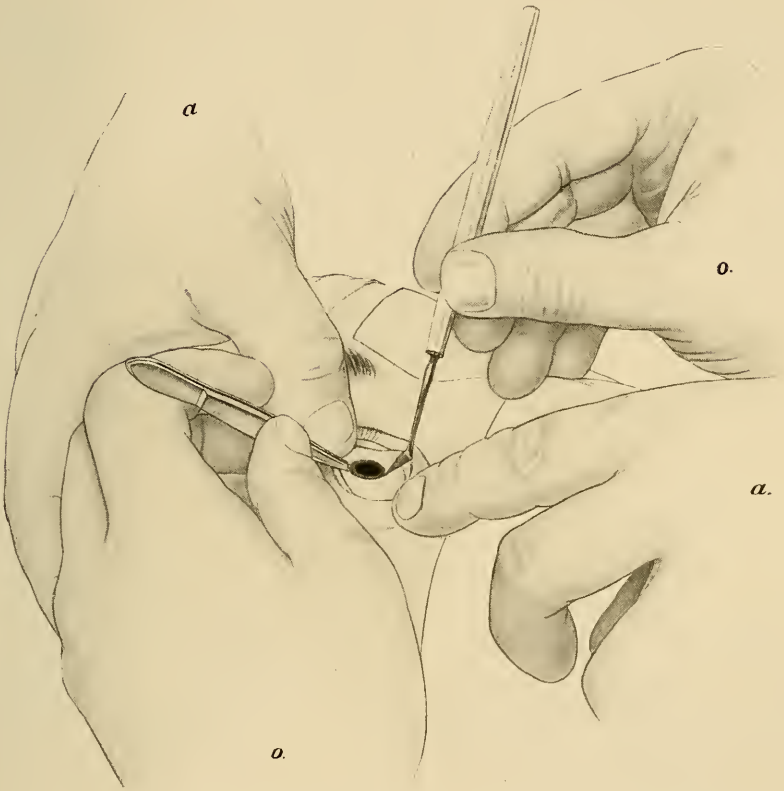

FIG. 122.—Linear extraction in the right eye. The operator's left hand fixes the eye with a pair of forceps, above at the limbus, while with the right hand he applies the lancet almost vertically below, exactly at the limbus. The pupil is dilated by atropin. A diagram showing the position of the incision in this operation may be seen in the sketch on glaucoma (Fig. 126).

of the lens substance will be rendered easier. Occasionally, after the pupil has become black, new opaque particles appear from above and behind the iris as the result of this gentle massaging. These must be removed through the wound by further massage.

The iris is now smoothed in place, a dressing applied to both eyes,

FIG. 123.—Linear extraction. In the second part of the incision, the lancet is turned over and has penetrated far upward. The incision lies exactly at the limbus.

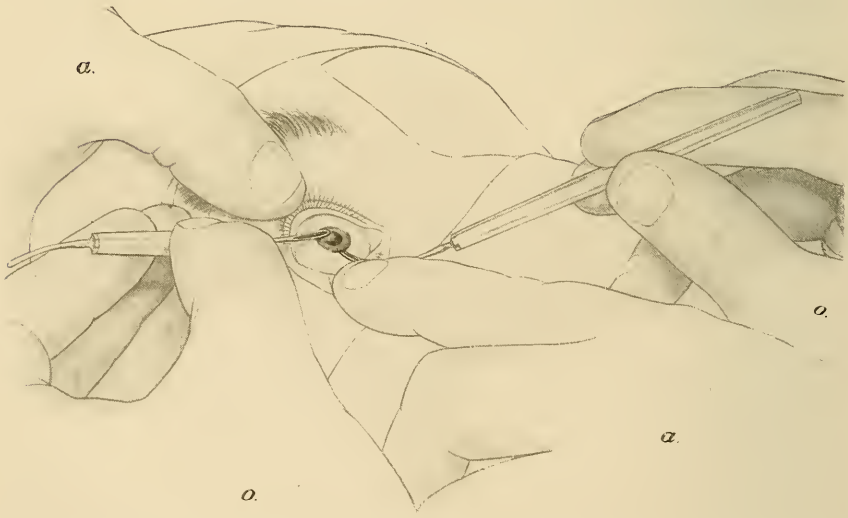

FIG. 124.—Linear extraction.—After opening the capsule the soft cataract remnants are massaged out of the eye. A spoon held in the right hand of the operator depresses the scleral wound-margin somewhat, thus causing the wound to gape, while with another spoon held in his left hand he makes stroking movements over the cornea from above downwards.

and the patient put to bed. If no complications have occurred, the dressing may be discarded after three days.

Complications.—If the lens is found to contain a fairly large nucleus, and this is occasionally seen even in young people, the hardened nucleus presses against the wound and fails to pass out. In these cases the incision is to be lengthened at one or both ends by means of the scissors, allowing the nucleus to escape easily, and thus avoiding the risk of a prolapse of the vitreous by applying too strong pressure.

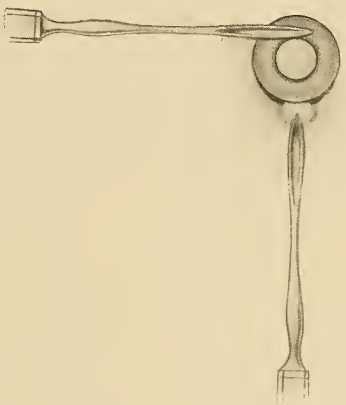

FIG. 125.—Diagram showing the position of the two spoons for the expression of the soft lens-masses in linear extraction.

Prolapse of the iris occasionally follows the expression of the lens, and care should be exercised that the iris is not injured during replacement with the spatula. The membrane may also be injured during the incision, in opening the lens capsule, and in massaging out the cataract with the spoon. A torn iris may give rise to most unpleasant sequels, by shrinking or by adhering to the corneal scar. If the iris has been considerably injured it should be excised. The resultant coloboma lying exposed in the palpebral fissure, however, causes annoying visual disturbances. As the operation usually passes off smoothly, the incision below is preferable, because the patients more readily look upward, and so freely expose the field of operation. If performed near the specified age-limit, it is better to make the corneal incision above, so that in the event of a large nucleus the wound can be lengthened and the iris, should it prolapse, excised.

Prolapse of the vitreous is a rare complication, but may occur in old and complicated cataracts in which the capsule is thickened and the lens together with its capsule is pulled out of the eye with the capsule-forceps. Occasionally, removal of the lens and capsule is performed in blind eyes for cosmetic reasons, but here there is always danger of vitreous prolapse. However, as the vitreous is fluid and the eyeball soft, the wound shows no tendency to gape, and the iris usually retains its normal position. Much more unpleasant is prolapse of vitreous of normal consistency during the course of a linear extraction. In this instance, not only is the further removal of the soft lenticular mass prevented, but no replacement of the iris can be attempted, and the pupil remains permanently distorted. Moreover, the wound frequently gapes, and has its healing process interfered with by the lower lid pressing against it during the ocular movements. Application of a suture to produce coaptation of the edges of the wound may become indispensable.

Total Cataract of Young Adults.—Linear extraction gives the most rapid results in total cataract of young adults, usually those over 12 years of age, who have sufficient intelligence to remain quiet during and after operation. Even in these cases discission followed eventually by puncture of the anterior chamber may be given preference. As the cataract is often a complicated one, it may happen that the fluid vitreous escapes from the wound as soon as the incision has been made with the lancet. In this event a supplementary discission of the capsule of the lens must suffice, as it would be impossible to remove by massage the lens-masses from the eye.

CHAPTER XII.

GLAUCOMA.

IRIDECTOMY—ANTERIOR SCLEROTOMY—SCLERECTOMY—CYCLODIALYSIS.

Glaucoma may be divided for study into *Primary Glaucoma*, which arises without recognizable previous disease of the eye, and *Secondary Glaucoma*, which occurs as an affection subsequent to some ocular inflammation.

IRIDECTOMY.

Indications.—Iridectomy is indicated for primary glaucoma, and also for secondary glaucoma due to increase of pressure caused by anterior synechia, exclusion of the pupil following iritis, luxation of the lens, cysts of the iris, and beginning ectasia of the cornea or sclera.

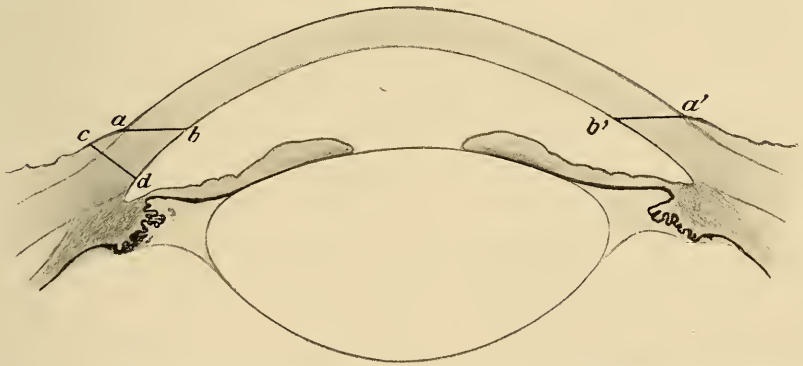

FIG 126.—Anterior portion of the eyeball in cross-section to demonstrate the relations in position of the angle of the chamber and limbus (enlarged). The limbus reaches about 2 mm. further forward than is represented by the situation of the angle of the chamber. a. and a'., limbus; ab. and a'. b'., position of the incision for the extraction of cataract. The Graefe knife, which in cataract incisions is inserted just at the limbus, at a., perforates the posterior wall of the cornea at b. In order that the knife shall come out exactly again at the limbus at a'., the counterpuncture must be begun already at b'., that is, at a point which to the operator seems to lie about 1 mm. from the limbus, in the direction toward the cornea; c. d., direction of incision with keratome in glaucoma.

Anesthesia.—Alypin may be used for anesthetization instead of cocain, because the former produces no dilatation of the pupil. The lack of vaso-constrictor influence can be remedied by the simultaneous administration of adrenalin. Before operation the pupil should be

contracted as much as possible by the frequent use of eserin, which, however, is often without effect when the pressure is considerably increased and advanced atrophy of the iris is present.

The Incision.—The incision for iridectomy in glaucoma is made through the sclera, from 1 to 1½ mm. behind the limbus, either with

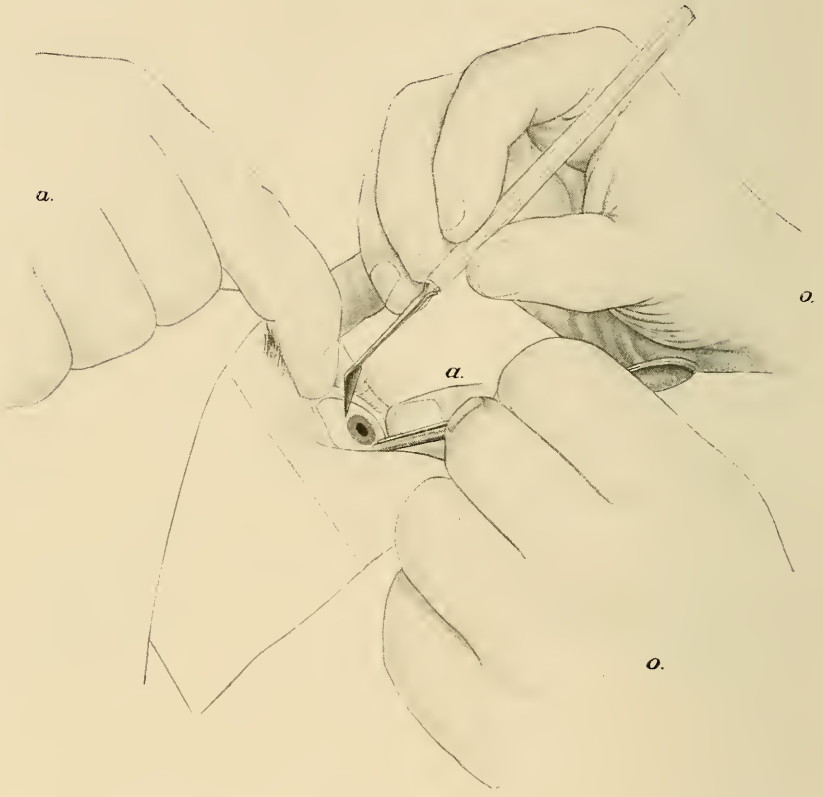

Fig. 127.—Iridectomy for glaucoma in left eye. Beginning of the incision. The assistant fixes the upper lid with one finger of his right hand in such a manner that the operator is not interfered with in the second act of the incision, when the position of the lancet is changed. The lancet is applied slantingly against the sclera at a distance of at least 1 mm. back of the limbus.

a keratome or a Graefe knife. In the illustration, Fig. 126, the line, c d, shows the direction of the point of the keratome applied vertically to the sclera, but, with a shallow anterior chamber or with the root of the iris in contact with the posterior wall of the cornea, injury to the iris would be unavoidable. It is therefore recommended not to apply the knife too vertically against the sclera in making the puncture.

Incision with the Lancet.—The operator is seated at the right side of the patient, and fixes the eyeball below in the vertical meridian. The lancet is held in the right hand between the thumb and first and second fingers, while the little finger is steadied against the head. The patient is directed to look well downward, and the point of the knife is

FIG. 128.—The position of the lancet is changed to the plane of the iris and is held so that the incision on all sides is the same distance from the limbus. Before the incision is completed the lancet penetrates further downward than is shown in the figure.

placed against the sclera, 1 to 1½ mm. back of the limbus, the blade forming an angle of about 45° to the curvature of the sclera (Fig. 127). The point penetrates the sclera, and, as soon as it is seen to have entered the angle of the anterior chamber, the direction of the knife is changed, so that the surface of the blade is parallel with the iris

(Fig. 128). The knife is now pushed downward without interruption until the point passes the lower border of the pupil, or the cut is as large as needed (Fig. 129). After the lancet has entered far enough downward, and the incision is of the desired length, the knife is slowly withdrawn from the eye, with the blade parallel to the iris and the point directed towards the posterior surface of the cornea, so that the capsule of the lens is not injured as the aqueous escapes.

The turning of the lancet at the proper time from its slanting position to parallel with the iris is the most difficult part of the incision, and is determined by the sense of touch, as after the point has perforated the sclera the resistance of the globe is no longer felt. If the direction of the knife is changed too soon, the cut is made irregularly and too far forward, and the internal opening, instead of piercing the angle of the chamber, is found nearer the cornea.

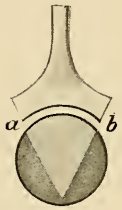

FIG. 129.—The lancet is pushed far down. The solid line a. b. denotes the position of the cut.

During the incision the lancet must not be pressed backward against the sclera, as the wound will gape and the aqueous flow away, in which case the incision could not be lengthened and the iris and lens would be exposed to injury. The knife must not be withdrawn until the incision is completed, as this will also permit escape of the aqueous. If the aqueous is allowed to escape rapidly the iris will float forward with it, but with the blade slowly withdrawn the aqueous flows out gently, and the pupil then remains round.

The incision must be maintained at a uniform distance from the cornea, (Fig. 129, a b), by keeping the blade parallel with the limbus. If one edge of the knife is turned slightly forward, the cut on this side will not remain at the same distance from the limbus at which the point of the lancet was first placed, but will deviate forward into the cornea. Indeed, the difficulty of the incision with the lancet lies in the fact that the eye of the operator must at the same time control the point of the instrument penetrating more and more downward, and also the appearance of the cut above at the limbus.

The point of the knife must not be turned backward, otherwise the lens capsule will be injured while passing the pupil. This can be avoided by a slight sideward movement of the point of the lancet, which is thus carried upward in front of the iris. In withdrawing the lancet we do not increase the length of the incision, as practised by

some operators, by pushing the lancet somewhat forward along the side of the limbus.

Incision with the Graefe Knife.—The Graefe knife may be used: 1. If the anterior chamber is *very* shallow. 2. If the pupil is dilated. 3. If the cornea is so opaque as to prevent the operator's view of the path of the knife. 4. In restless patients.

The same rules apply in the fixation of the eye, the position of the operator, and the employment of the right and left hand as in the operation for cataract. On the right eye, if the anterior chamber is very shallow, it may be preferable to operate from behind, as in this position the right hand can be steadied on the head of the patient better than the left when operating from the front. The length of the incision should be the same as when the lancet is used, about 8 mm. To obtain a sufficiently peripheral position, the knife point is entered in the sclera $1\frac{1}{2}$ mm. from the limbus, and passed approximately parallel to the plane of the iris. If held more upright against the sclera, an injury to the iris, and indeed even to the lens, is easily incurred. After the point of the knife has appeared in the angle of the chamber, the instrument is pushed forward to the outermost part of the opposite angle, always remaining in front of the iris to avoid the pupil, and the counter-puncture is made. The knife is carried upward with a sawing motion, during which it is held in a plane parallel with the iris, so that the incision remains at a uniform distance from the limbus throughout. Not until the blade has arrived beneath the conjunctiva above is its cutting edge turned forward to form the short conjunctival flap, as in the cataract operation.

Advantages and Disadvantages of the Two Knives.—The advantage of employing the lancet is that the edges of the wound are smooth and easily apposed, and healing is complete in a few days. The incision with the Graefe knife is more inclined to gape, and, on account of its irregular edges, does not heal so promptly. But this factor may be considered as an advantage in eyes with an increase of pressure, inasmuch as fluid will ooze out more easily and for a longer time through a wound which does not close rapidly than through one which heals promptly and solidly.

The lancet is easily injured by handling or boiling, and if force is used in an attempt to penetrate the sclera with the dull point, the knife may suddenly slip forward and injure both the iris and lens. The same accident may occur with a perfectly sharp keratome if the

patient makes a sudden movement with the eye or head. The Graefe knife is undoubtedly much less dangerous, especially for the beginner, and a more peripheral incision is more easily attained with it than with the lancet. On this account the lancet is only used in those cases in which the anterior chamber is not too shallow, and those with a contracted pupil, when quiet behavior of the patient is probable.

While the performance of the incision with the Graefe knife lessens somewhat the danger of injuring the iris and lens through too rapid and too deep penetration, it occasionally leads to the opposite error—the intralamellar incision, as fully mentioned in the operation for senile cataract.

Excision of the Iris.—The iridectomy is performed in the same general manner and with the same instruments as described in the operation for cataract. The iris forceps are held in the left hand and are introduced closed into the wound until they reach nearly to the upper margin of the pupil, then opened, and a fold of iris drawn out and excised with the de Wecker scissors which have been held ready. The iris section is, however, essentially different from that in cataract operation. As the object is not only to excise the iris close to its attachment, but also to remove as large a piece as possible, the scissors, held parallel and close to the wound (Fig. 130), which may even be slightly depressed by them, sever the right half of the iridal fold first, after which the rest of the iris is drawn with the forceps still further toward the other angle of the wound, thus pulling still more membrane from the eye, and the left half is cut through. As the excision of the iris is ordinarily quite painful, the scissors should be ready close to the wound to make the cut as soon as the iris is grasped.

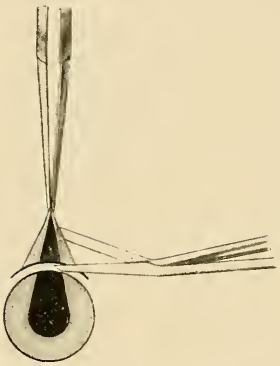

FIG. 130.—The iris drawn out from the eye is cut off near its attachment by the scissors, the blades of which are held parallel with the limbus.

Reposition of the Iris.—The iris is replaced in exactly the same manner as described in the operation for cataract, although reposition is much more difficult, because the relatively higher pressure squeezes the margins of the coloboma into the angles of the wound, and, as the iris is frequently atrophied, it shows little tendency to resume its

normal position. Attempts at reposition are not to be discontinued until both sphincter-margins are in place, as healing of the iris in the wound is likely to lead to a renewed attack of glaucoma. Care must be taken not to touch or injure the capsule of the lens with the spatula. After the sphincter-margins have been stroked from the angle of the wound, the spatula is withdrawn from the eye in the neighborhood of the coloboma to prevent pressing the iris up again.

If the patient cannot be induced to look downward, it may be necessary to desist from replacement. Fixation of the eye has always the great disadvantage that the wound is made to gape, which increases the likelihood of an injury to the lens, as the margin may present in the wound. If one of the cut edges of the iris grows fast in the wound, and increased tension occurs, operation must be directed to freeing it, as neither a second iridectomy nor a sclerotomy nor any other similar operation fulfills the indication.

If the incision was made with the Graefe knife, the final procedure is to restore the conjunctival flap in position before the dressings are applied.

Complications of the Incision.—These have mostly been described in the operation for cataract, and need only brief mention here. The most important are:

Laceration of the conjunctiva when grasped by the forceps.

Intralamellar incision.

Transfixion of the iris by the Graefe knife. If the anterior chamber is shallow, the point of the knife may catch in a protrusion of the surface of the iris and penetrate its tip. This piercing of a few fibers of the iris with the knife is of no significance, as they are always cut through during the continuation of the operation, so that the freed iris again resumes its normal position. As in all other incisions which open the anterior chamber, the knife is not to be withdrawn with the intention of freeing the point, as escape of the aqueous prevents a continuation of the incision. The only indication for the withdrawal of the knife is when the operator, while making the puncture, passes it back of the iris. If the faulty incision were continued, even more extensive injury to the iris and lens would occur than by the immediate withdrawal of the knife. As the incision is relatively much shorter than that in cataract extraction, and is ordinarily above the region of the pupil, "falling of the iris in the way of the knife" is an extr ordinarily rare occurrence in spite of the shallow chamber.

Production of an Iridodialysis during the Incision with the Lancet.—If the point of the lancet catches in the iris, the latter may be pushed down and thus torn off at its ciliary attachment. This is usually followed by hemorrhage, which greatly impedes the further course of the operation, especially as it is difficult to pull the severed piece of iris out with the forceps without endangering the exposed lens capsule. It is then safer to employ the blunt hook for withdrawing the iris instead of the forceps.

Incorrect position of the incision is due to a faulty manner of holding the knife (turning the cutting edge forward) or through improperly inserting the point. A cut directly forward against the cornea naturally lessens the likelihood of excision of the root of the iris. Especially to be avoided is too long an incision, which may be produced by introducing the knife too low down. The high intraocular pressure would cause the wound to gape and the lens to appear in the wound.

Hemorrhage may become a disturbing factor during the performance of the incision, originating either from dilated conjunctival or anterior ciliary vessels or from injury to Schlemm's canal. The anterior chamber becomes filled with blood so that the iris is hidden from view. At first we must try to remove the blood from the eye by stroking it out, assisting it to escape by slightly depressing the peripheral edge of the wound. Usually the blood reaccumulates quickly. It may be impossible, however, to remove the blood, as it becomes attached to the walls of the anterior chamber in the form of a clot. As the pupil cannot be seen, the lens capsule is in danger of injury during the withdrawal of the iris. The presence of the blood also greatly disturbs the replacement.

Complications of the Iridectomy.—The excision of the iris is on the average much more painful than in cataract extraction. The influence of the anesthetic is less on account of the injection of the eye, and perhaps also because of the alteration in absorption conditions. Partial or complete detachment of the root of the iris may occur by the patient suddenly moving the eyeball while the forceps still grasp the membrane. Severe hemorrhage follows, obscuring the field of operation, but the blood is usually absorbed. It is our custom after the incision to instil several drops of a sterile 3 per cent. solution of cocain upon the wound, which, by direct contact, appreciably reduces the sensitiveness of the iris.

The iris may be so atrophic that the forceps tear out at each at-

tempt to withdraw a fold. In well-advanced glaucoma the upper half of the iris may be turned back behind the limbus, necessitating a somewhat broader iridectomy below. The disturbance to vision due to the uncovered coloboma is of no importance, as sight is already seriously damaged by the glaucoma.

The Earlier the Iridectomy in Glaucoma, the Easier the Operation.—So long as the anterior chamber is not too shallow, and the iris almost normal, a large coloboma may be made and the root of the iris included in the section. If the angle of the chamber has been obliterated by adhesion, the incision cannot be made as near to the periphery as desired. Clinical experience shows that, where the operation has been delayed until the root of the iris is adherent in the angle of the anterior chamber, little relief can be expected by the operation of iridectomy.

Injury of the Lens Capsule.—This is caused by the point of the knife, the iris-forceps, or the spatula. The injury occurs in the pupillary region, and is usually followed by cataract. If examination is made by lateral illumination, the scar of the capsule wound, from which the cataract had its origin, can always be demonstrated. The cataract does not always become complete, but may be confined either to a clouding in the neighborhood of the capsular wound, or to a stellar opacity in the anterior or posterior lamellæ of the cortex.

The injury to the capsule is frequently due to the iris-forceps. They should always be introduced into the wound parallel with the iris and pushed close to the margin of the pupil, but not brought within the pupillary space itself. If the iris has already floated into the wound, the forceps need not be entered into the interior of the eye at all, but should lift up the exposed iris, which becomes plainly visible after the conjunctival flap has been laid back on the cornea. Should the patient not look well downward, the excision of the iris may become difficult and the danger of injury to the lens capsule increased, especially if he moves his eyes around, or suddenly looks up, while the forceps are in the eye. In such cases it is better to fix the eye with forceps, which ordinarily we avoid in iridectomy. Instead of the iris-forceps it may be necessary to draw out the iris with a blunt hook which has been bent in a suitable direction. Only a small piece of the iris can be excised, the removal of a large portion, under the circumstances, being inadvisable or impossible.

Spontaneous Rupture of the Lens Capsule.—After completing the iridectomy, a subchoroidal hemorrhage may produce an increase

in the intraocular tension, with rupture of the lens capsule. Spontaneous rupture occurs in the equator of the lens, and no wound is seen in the capsule by lateral illumination. The lens is usually displaced forward, and its border presents in the wound, or the capsule may burst over a wide area, and the lens-substance with the nucleus be either discharged from the eyeball or become incarcerated into the wound (*Hernia lentis*), which remains widely gaping under the conjunctiva. The operator must be prepared for this accident in eyes with long-continued high tension, when the eye is of stony hardness, the anterior chamber almost obliterated, the sclera becoming ectatic, the iris markedly atrophic, and the eye itself painful. The operation often cannot be performed in these cases without a general anesthetic. If the eye is completely blind and painful, enucleation should be advised.

Subluxation of the lens may occur in connection with its altered position after opening the anterior chamber and the escape of the aqueous humor. The lens then inclines forward, and its upper border tends to turn forward on account of the lessened resistance of the coverings of the bulb in the region of the wound. This presages a bad prognosis for the later behavior of the eye. The anterior chamber does not become re-established for a long time, intense attacks of renewed increase in pressure follow, and in spite of repeated sclerotomies and other operations such eyes are usually lost.

Prolapse of the vitreous is relatively rare, and is likely to occur in absolute glaucoma, especially if there is ectasia of the sclera. The prolapse not only makes excision of the iris impossible, but also a reposition of its margins. Besides, the wound gapes because of the interposition of the vitreous, and, although an ugly ectatic scar is formed, it is one of the relatively good outcomes of the operation. In most instances, however, renewed attacks of increase in pressure follow, which, on account of their painfulness, finally render enucleation of the eye compulsory.

Occasionally the vitreous prolapse leads to a still graver complication, namely, expulsive hemorrhage. On account of the sudden decrease in pressure, severe hemorrhages under the choroid occur, and the latter is pushed forward with the retina and squeezed out of the eye through the wound. Particularly in the operations for old absolute glaucoma is this accident seen. Such eyes must be immediately enucleated; otherwise weeks would pass before the eye atrophied and

became quiescent. The bleeding is usually considerable, and to arrest it temporarily the application of a pressure-dressing is necessary.

Glaucoma Due to Anterior Synechia.—The liberation of attached iris is made with a Graefe knife, which is inserted at one angle of the corneal scar, carried through the anterior chamber until it reaches the other side of the site of adhesion, and is then brought out as far in the periphery as possible. The incision is completed with sawing movements. Frequently the knife has already separated the iris from the scar, and the membrane assumes its proper position immediately after the incision has been completed. If this result is not secured, the iris must be brought out from the wound with the iris-forceps, and as large a piece as possible excised. The cut edges are then replaced. Because of the state of ocular irritation, this operation is often difficult of performance, but is usually followed by a favorable result. The blackish scar, which has been ectatic, soon flattens out during healing, and increase in pressure does not recur.

This operation is also indicated in adherent iris after cataract operations in which there has been an increase in tension. In order to prevent a gaping of the wound and a prolapse of the vitreous, it is recommended to leave a bridge of conjunctiva and then bring the iris out under it. By the same method one has to remove the so-called cystic scars after cataract operations.

ANTERIOR SCLEROTOMY (DE WECKER).

This operation was designed to produce a filtration cicatrix in the angle of the anterior chamber which would permit the aqueous to filter out of the eye, and prevent increase in the intraocular tension. Such a filtration scar is not actually secured, as the wound edges are so close to each other that direct union takes place.

Indications.—De Wecker recommended the operation, combined with miotics, in chronic simple glaucoma, and in cases of high tension and shallow anterior chamber, with a view of later performing iridectomy. It has also been employed in hemorrhagic glaucoma, painful blind glaucomatous eyes, and hydrophthalmus. In hemorrhagic glaucoma it is indicated as a preliminary operation to lower the tension in order that an iridectomy may be performed later under less dangerous conditions. Since the introduction of the sclerectomy of Lagrange, which is a much more effective procedure for increased tension, we rarely perform anterior sclerotomy.

The Incision.—The opening into the anterior chamber resembles the incision made for the extraction of a senile cataract, except that it is placed *more peripherally*, and may be made above or below, the eye being fixed at such a point that the forceps will not be in the way of the knife. As the operation has for its object an incision into the angle of the chamber, the points of entrance and exit of the knife must lie in the sclera at least 1 to $1\frac{1}{2}$ mm. from the limbus (Fig. 131).

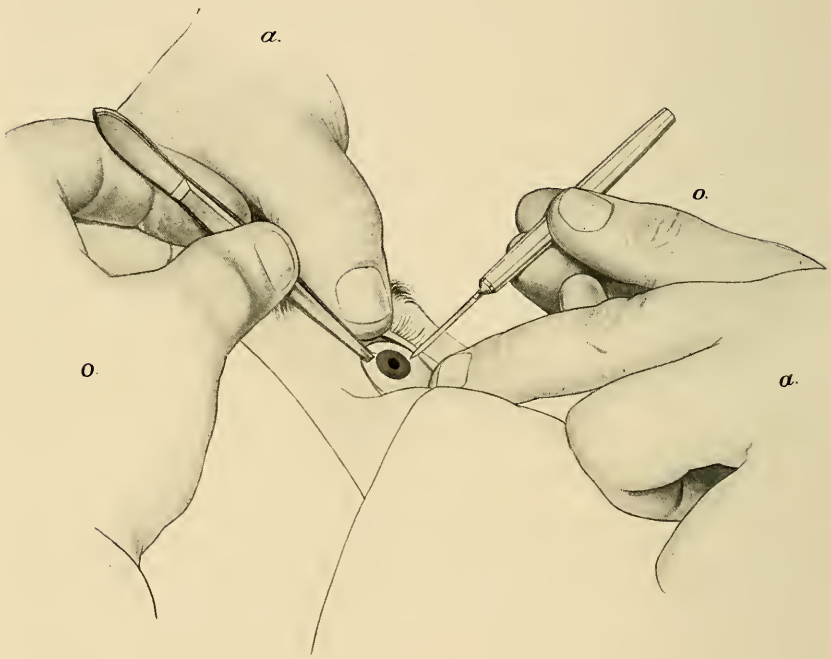

Fig. 131.—Anterior sclerotomy in the left eye, performed below. Beginning of the incision. The left hand of the operator fixes the eye, either laterally or above; the cutting edge of the knife is directed downward. The incision is begun at least 1 mm. away from the limbus in the sclera. The lower lid is drawn far downward by the assistant.

A Graefe knife is held as in the extraction of senile cataract, and the point is thrust through the sclera, 3 mm. from the horizontal meridian and parallel to the surface of the iris, and slowly carried across the anterior chamber, between the cornea and iris, and penetrates the sclera on the opposite side at the same distance from the limbus as the first puncture (Fig. 132).

The incision is continued with sawing movements, as described in

the operation for senile cataract, but the cut is not completed, the knife being withdrawn from the eye before the incision is finished, leaving a small bridge of sclera. As it is the intention to also cut into the angle of the anterior chamber at the bridge of tissue (Fig. 133), the direction of the handle of the knife is changed as the blade is removed, so that the point incises from within the tissues in the angle of the chamber beneath the bridge of sclera (Fig. 134). The length of the entire incision is somewhat less than that of the cut in the cataract operation. Usually after completion of the incision the iris remains in its normal position, especially if the patient is quiet, but should the pupil be distorted or the iris prolapsed, reposition is done. If the iris is prolapsed when

FIG. 132.—Diagram showing the position of the knife in the eye during the incision of the sclera. It lies in the sclera at least 1 mm. away from the limbus.

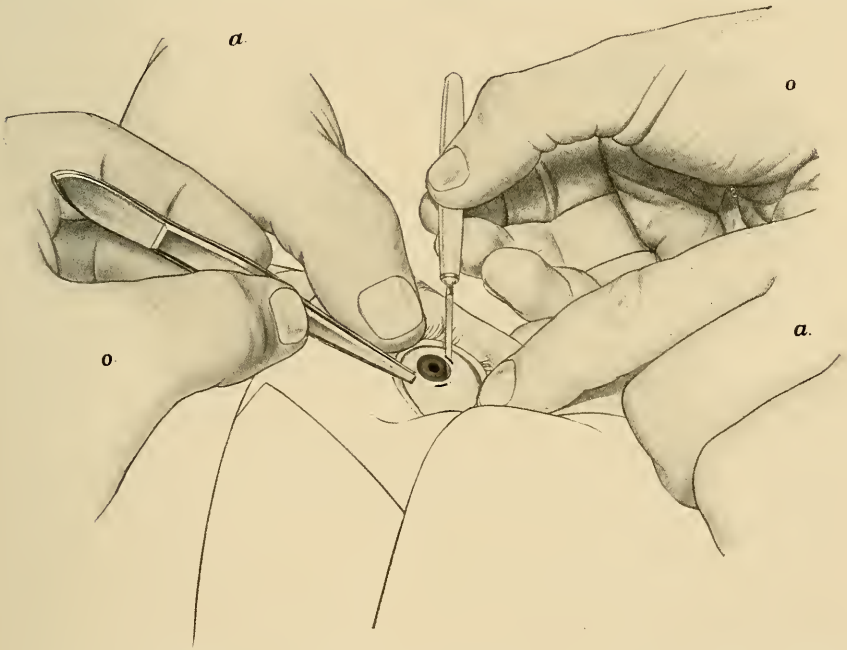

FIG. 133.—Termination of the incision. In order to cut through the inner lamellæ of the sclera in the neighborhood of the scleral bridge, which is permitted to remain, the knife is turned by an elevation of its handle in such a manner that its point produces the desired incision into the angle of the chamber.

Compare the position of the operator's hand holding the knife while performing the first act of the operation (Fig. 131) and while withdrawing it (Fig. 133).

the dressings are changed on the following day, the prolapsed portion must be excised.

Accidents.—These usually follow errors in entering the knife, and have been previously described in the operation for cataract.

Intralamellar Incision.—If the knife is directed slightly forward, instead of parallel to the iris, the point is pushed between the layers of the cornea, an error that is detected by the experienced operator by the resistance offered to the advance of the blade. If the faulty incision is discovered before the anterior chamber is perforated, it is best to withdraw the knife and to make a new puncture, but if the aqueous humor has already escaped, the operation must be postponed, as it is impossible to continue it without injuring the iris. The traumatic opacity of the cornea consecutive to an intralamellar incision is of no real significance, as it eventually clears up.

Fig. 134.—In this diagram the solid line represents the perforating cut, the dotted line that part of the incision in the range of which only the inner lamellæ of the sclera are cut through.

Injury of the Iris.—If the point of the knife is thrust through the sclera too vertically the iris may be pierced and the lens injured. The knife may also divide the root of the iris which in certain conditions fills up the angle of the anterior chamber, causing iridodialysis and severe hemorrhage.

Favorable results can be expected only if the incision passes through the angle of the anterior chamber. It is a mistake to make the cut at the limbus or in the cornea except when the root of the iris is adherent to the posterior surface of the cornea, thus displacing the angle of the chamber further forward and making it impossible for the operator to begin the incision to the outer side of the limbus, as the knife would then be passed in back of the iris.

Results.—In the greater number of cases the results of operation are not only temporarily good but permanently lasting, if reserved for acute glaucoma in which after the usual iridectomy there is a renewed increase of pressure. In such cases it is our custom not to perform a second iridectomy at once, which, as it would have to be made below, is always followed by a severe disturbance in the visual power, but to place our reliance on an anterior sclerotomy. When necessary this operation may be repeated several times on the same eye, and it is optional whether the incision is made above, below or at any other favorable point. In the eyes with a coloboma upward we prefer to

make the sclerotomy below, so that the knife is separated from the lens by the iris, to insure against a possible injury of the capsule.

In this, as in every glaucoma operation, the eye must be energetically treated with eserin before the operation, in order to bring about as marked a contraction of the pupil as possible.

SCLERECTOMY AND IRIDO-SCLERECTOMY (LAGRANGE).

Since its introduction, sclerectomy has been demonstrated to be superior to iridectomy and anterior sclerotomy in the treatment of some forms of glaucoma, and has largely superseded the operation of de Wecker in cases in which the latter was especially indicated.

Indications.—Lagrange does not recommend the operation for acute glaucoma. It is indicated in (1) simple glaucoma, which experience has proved is little influenced by iridectomy; (2) increased ten-



FIG. 135.—Sclerectomy. Puncture and counter-puncture as in ordinary iridectomy.

FIG. 136.—Sclerectomy. Cutting edge of the knife turned back. Incision begins to deviate from the limbus backward.

sion in eyes on which iridectomy has previously been performed for glaucoma, the sclerectomy being preferred to a second iridectomy, as the coloboma is not enlarged, and, if performed above, prolapse of the iris cannot occur; (3) secondary glaucoma of various origin, for instance, anterior synechia, inflammatory affections in which previous iridectomy has proved of no value, and in eyes with increased tension when it is desired to leave the iris untouched, as in sympathetic ophthalmia; (4) in all cases of glaucoma in which iridectomy has failed to act beneficially in one eye, sclerectomy would appear to be indicated if operation for the same affection becomes necessary in the other eye.

The Incision.—After the full effect of eserin has been obtained, the point of the Graefe knife, with the plane of the blade parallel with the iris (Fig. 135), pierces the sclera at a point 1 mm. back of the limbus, and about 4 mm. above the horizontal plane, crosses the anterior chamber in front of the iris, and emerges at a corresponding spot. As soon as the knife reaches the upper part of the angle of the anterior chamber the edge of the blade is turned slightly backward (Fig. 136,)

cutting obliquely through the sclera, about 3 mm. from the limbus, and forming a conjunctival flap, which latter is limited in its length by turning the blade directly forward (Fig. 137).

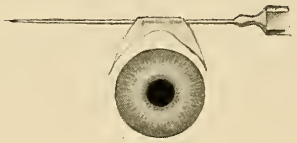

FIG. 137.—Sclerectomy. Cutting edge of the knife turned forward for excising the conjunctiva, behind which the scleral incision is visible.

Excision of a Piece of Sclera.—The conjunctival flap, which has attached to its under surface a piece of the sclera, is turned over the cornea, and the scleral fragment grasped with fine forceps, and cut

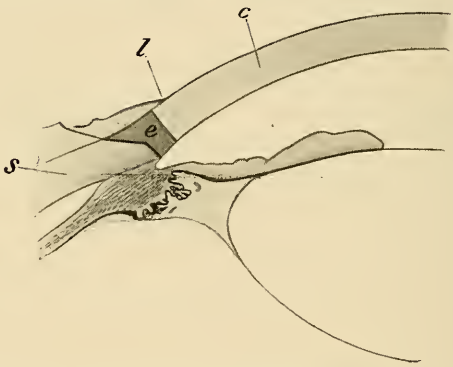

FIG. 138.—Sclerectomy. Vertical section through the eye. c., cornea; s., sclera; l., limbus; e., piece of sclera to be excised.

close to its conjunctival attachment with a pair of flat, curved scissors (Fig. 139). We prefer and have had made especially for the purpose

FIG. 139.—Sclerectomy. Excision of the scleral flap. Conjunctival flap turned down over the cornea.

a pair of de Wecker scissors with large and strong blades.

Iridectomy.—The iridectomy is not an essential part of the opera-

tion, and is usually added to prevent an iris prolapse. A narrow incision of the iris is made, so that a small coloboma results (Fig. 140), or a peripheral portion only of the iris may be removed, leaving the sphincter intact. In simple glaucoma, where no special risk of prolapse exists, the iris is not excised.

Immediately after operation the pillars of the coloboma are stroked in place, the conjunctival flap restored to its proper position, and dressings applied. A dark spot visible beneath the conjunctiva (Figs. 140 and 141) corresponds to the scleral opening. Directly after operation the conjunctival flap above this area is slightly sunken.

Complications.—If the fixation forceps tear out, it is occasionally impossible to turn the knife and obtain the desired scleral section, and iridectomy is all that can be done.

FIG. 140.—Irido-sclerectomy. Appearance of the wound immediately after the operaion. Complete iridectomy.

FIG. 141.—Irido-sclerectomy. Peripheral iridectomy.

If the knife injures the root of the iris, especially when a so-called peripheral synechia exists, the iris is to be drawn out with a blunt hook instead of the forceps, to avoid injury to the lens capsule. In excision of the piece of sclera the iris often protrudes hump-like into the wound and is injured. Generally, the hemorrhage is more profuse than in the ordinary iridectomy.

Excision of the wedge of sclera will be difficult if the conjunctiva is pathologically adherent to the sclera.

Prolapse of the ciliary body may follow a too-peripheral incision, and will result in ectasia of the scar or shrinking of the eye after a lingering inflammation.

Prolapse of the lens and vitreous may follow, as in ordinary iridectomy, although perhaps more frequently, especially in eyes with marked intraocular tension.

Results.—The day after operation the conjunctival flap has usually become adherent, is somewhat swollen, and the anterior chamber remains shallow. There is usually more sensitiveness to light than follows ordinary iridectomy. The scar may show varied appearances:

1. The conjunctival flap appears swollen and distinctly protruding (Fig. 142), with the excised opening in the sclera distinctly shown as a black spot, but the wound-margins are in normal position. This is the most characteristic appearance, and is found in about one-third of the cases.

2. The flap is flat, but the dark spot is distinctly seen, indicating a thinning of the sclera at that point.

3. A round or oval opening is visible in the sclera in the area of the scar, back of the scarcely changed conjunctival flap—a conjunctival fistula.

4. The scar is black, distended, the wound-margins of the sclera erect, and the conjunctival flap unchanged. This form of scar is the

Fig. 142.—Filtration scar after sclerectomy.

most unfavorable, as the pressure usually does not subside, the anterior chamber continues shallow, and the eye remains painful and must finally be removed.

Irido-sclerectomy exerts a decided influence in reducing intraocular tension, probably frequently greater than any other glaucoma operation. In a few instances, even with the development of a typical ampulla-shaped scar, the operation does not reduce the tension of the eye or influence the course of the disease.

Disadvantages.—The objections made to sclerectomy are inability to accurately regulate the size and depth of the excised portion of the sclera, danger of injury to the lens, possibility of the formation of a distended scar, occasionally iritis, loss of vitreous, agglutination of the pupillary border to the lens capsule, and the possibility of secondary infection through the scleral opening.

POSTERIOR SCLEROTOMY.

This operation consists in the puncture of the vitreous space through the sclera with a Graefe cataract knife.

Indications.—*Posterior sclerotomy is used in glaucoma only as a preliminary operation* in cases in which iridectomy is technically impossible because of the complete obliteration of the anterior chamber

FIG. 143.—Posterior sclerotomy. The eye, which is directed well upward and inward, is fixed with forceps at the limbus and the Graefe knife is introduced at the outer and lower portion in a meridional direction, the cutting edge looking backward, the point toward the center of the eyeball. The assistant pushes the lower lid far downward.

in the presence of enormous increase in pressure. In most cases an iridectomy may be proceeded with immediately after the posterior sclerotomy, as the escape of the vitreous produces a softening of the eyeball and simultaneously the anterior chamber commences to reappear.

Posterior sclerotomy is of small value as an operation for glaucoma, as the diminution of pressure induced by it usually soon disappears, sometimes after a few hours, and the scar at the site of the incision is so dense that a filtration of the ocular fluids outward cannot take place.

The Scleral Opening.—The perforation of the sclera is made posterior to the ciliary body; at least 6 to 7 mm. from the limbus, preferably at the outer and lower portion of the eyeball, between the external and inferior rectus muscles, while the patient looks inward and upward. The eye is fixed with forceps and the cutting edge of the knife is directed backward from the ciliary body so as not to bring this organ into danger. The incision is made in a meridional direction, corresponding to the fibers of the sclera and the blood-vessels in the choroid. An equatorial incision, that is, one parallel to the limbus, would divide a series of blood-vessels in the choroid, and a cut in the horizontal meridian would injure the posterior long ciliary artery and destroy the eye through a severe hemorrhage into the vitreous.

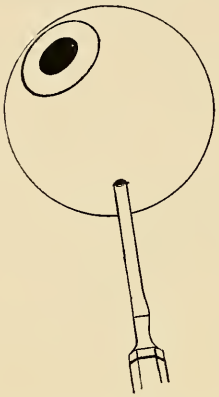

FIG. 144.—Posterior sclerotomy. In this diagram, the knife, which is now in the eyeball, is turned to the equatorial direction, so that the wound gapes, allowing the vitreous to exude.

During the puncture the point of the knife is directed toward the center of the eyeball, in order not to pierce the posterior capsule of the lens, which could readily occur if the blade were passed obliquely forward (Fig. 143). Moreover, the puncture must have a definite length —as long as the breadth of the knife. In order to lower the tension of the eye by the escape of a small amount of vitreous humor, the knife must be turned while in the scleral wound from a meridional direction to an equatorial one (Fig. 144), so that the wound is caused to gape. After the knife has been returned to its original position, it is withdrawn from the eye.

CYCLODIALYSIS (HEINE).

This operation is designed to establish a communication between the anterior chamber and the suprachoroidal space. It was suggested to Heine by Fuchs, who gave detailed descriptions of the choroidal detachment following iridectomy for glaucoma and extraction of cataract, pointing out the *co-existent diminution of pressure*, and presum-

ing that the choroidal detachment was brought about by the aqueous humor oozing backward through tears in the *ligamentum pectinatum* produced by the operation. Heine tried, by establishing through an artificial cleft in the ligament a communication between the anterior chamber and the suprachorioidal space, to give rise to a detachment of the choroid and thereby to a reduction of the intraocular pressure. In conceiving the method of the cyclodialysis he took for granted, first, that the tear would not heal again spontaneously, and, second, that the suprachoroidal space represented either a natural passage for the intraocular circulation for the carrying off of the liquids from the interior of the eye, or that it was created such a one by the operation. But the expected detachment of the choroid failed to appear, even when the eyes had been perfectly soft. The fact that in successful cases the tension remains below normal for months proves that the result is independent of a supposed detachment of the choroid, which, as a rule, passes away within a few days or, if extensive, within a few weeks, and with it the lowering of the tension. The theory, therefore, on which the operation had been based seems to be incorrect. But this should not bias our judgment. It is likely that the occasional success is accomplished by the undermining of the angle of the anterior chamber. Cyclodialysis should be regarded as an operation to free this angle, just as many other methods that have been recommended for glaucoma, to which iridectomy also probably belongs.

Indications.—Cyclodialysis is indicated in:

1. Primary glaucoma, in which the iridectomy is not only difficult but dangerous, either because of an obliterated anterior chamber, atrophic iris, or maximal dilatation of the pupil from increased tension or advanced intraocular changes. The performance of the cyclodialysis is *independent of the existence of the anterior chamber.* Even though the reduction of pressure may be only temporary, the operation is valuable as a preliminary to iridectomy. If the tension is diminished by the cyclodialysis, an iridectomy can be performed without danger.

2. It is also indicated in patients who have lost one eye by malignant glaucoma or a severe hemorrhage after an iridectomy, and also in old, infirm, coughing or restless people, because rest in bed is not required after operation.

3. The operation renders remarkable service in secondary glaucoma caused: (*a*) By anterior synechia, in which after iridectomy the

tension increases. (*b*) By luxation of the lens in the vitreous chamber, in which loss of vitreous would be unavoidable in performing an iridectomy and its result uncertain. (*c*) After cataract extraction, provided that the edges of the coloboma are in proper position. If there is adhesion of one or both sides of the coloboma to the operation scar, excision of the attached iris is the proper treatment for the glaucoma.

Cyclodialysis, although able to diminish the intraocular pressure, cannot be regarded as preferable or even equal to iridectomy. It

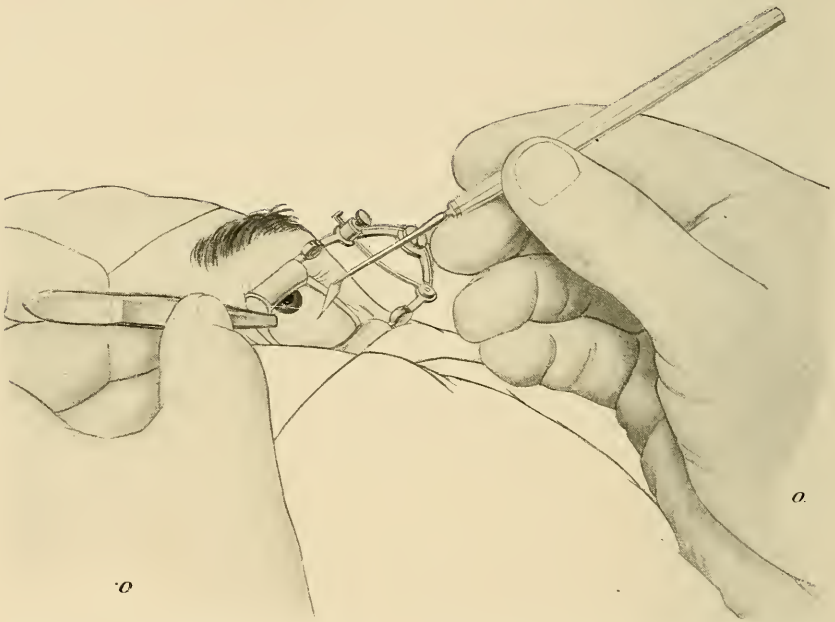

FIG. 145.—Cyclodialysis on the left eye. The eyelids in this operation are held apart by a spring-speculum. After the conjunctiva has been incised and the sclera exposed to view, a short incision is made with the lancet (keratome) parallel to the limbus and at a distance of about 5 mm. to the outer and lower side of it. The lancet is made to cut with its side and not with its point.

should not be used indiscriminately in place of iridectomy, but should be considered as a valuable aid when iridectomy fails or is contra-indicated.

The Operation.—The patient is directed to look upward, and an opening is made with scissors in the conjunctiva in its outer and lower part, at a distance of about 5 mm. from the limbus, and the sclera exposed by undermining. The eye is fixed with forceps, the assistant holds the wound open with two double tenacula, and a cut 2 mm. long

is made, with the lancet vertically, through the sclera at a distance of 5 mm. from the limbus and parallel to it (Fig. 145). The tissues are divided layer by layer until the uvea may be seen through the wound.

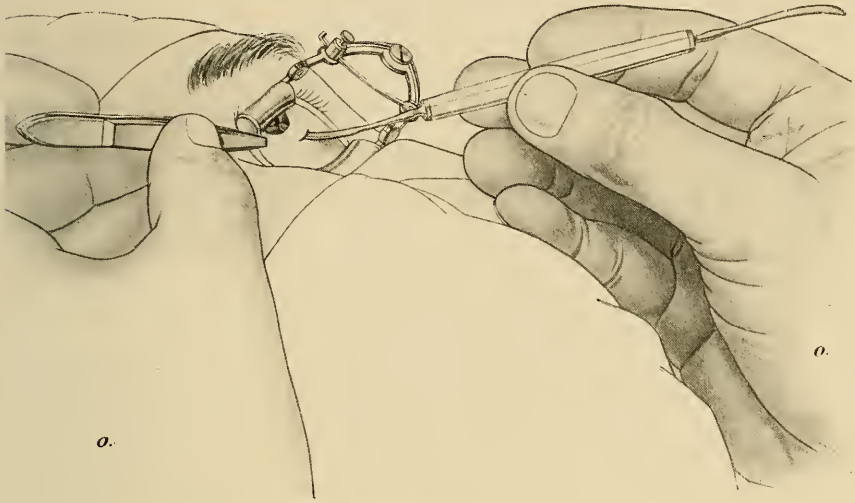

Fig. 146.—Cyclodialysis. The spatula, held parallel with the surface of the sclera, is now inserted through the wound in the sclera in front, between the sclera and the ciliary body, and appears in the angle of the chamber.

Care must be taken that the ciliary body, which lies immediately beneath, is not injured. The incision is made with the lateral edge of the knife, assuring the same depth in the entire length of the wound.

A spatula, such as is used in reposition of the iris, is carefully carried forward through the wound between the sclera and the ciliary body with its plane parallel to both (Fig. 146). If all the fibers of the sclera have been divided, this can be done without any difficulty. The point of the spatula soon appears below in the angle of the chamber and is pushed forward with lateral movements to the right and to the left (Fig. 147) until the ciliary body is detached from the sclera. The aqueous does not escape unless one edge of the spatula is turned forward slightly, causing the wound to gape. If the ciliary body is not injured during the incision, no bleeding occurs into the anterior chamber.

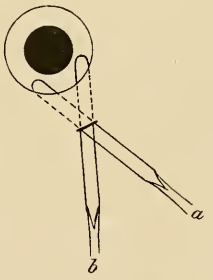

Fig. 147.—The position of the spatula is shown during the performance of the lateral movement intended to detach the ciliary body.

After withdrawing the spatula from the wound the conjunctiva is sutured and the eye bandaged.

Complications.—The anterior ciliary veins, which are often dilated in glaucomatous eyes, should not be injured, as the hemorrhage complicates the operation and causes the blood to be sucked into the anterior chamber during the introduction of the spatula. Bleeding from the small scleral vessels is prevented by repeated dropping of adrenalin into the wound during the incision. Severe bleeding from a ciliary vein at its point of exit from the sclera should be stopped by application of the thermo-cautery. If the incision of the sclera is not carefully made, the knife opens through the choroid, and vitreous appears in the wound.

As the spatula is pushed forward, it must be held close to the inner surface of the sclera, in order not to get behind the iris. As the point enters the anterior chamber the *ligamentum pectinatum* is divided, the angle of the chamber opened, and the ciliary body detached from the sclera.

A frequent complication is detachment of Descemet's membrane. If the spatula is dull, the fibers of the *ligamentum pectinatum* are not severed, and the spatula is caught in Descemet's membrane and the parenchyma of the cornea, detaching the latter and leading to opacity, which, however, disappears in a few weeks. This faulty position of the instrument is recognized by marked resistance to its further advance. By slightly withdrawing the spatula it will be freed from entanglement and then the undermining is continued. Generally the spatula finds its right way even in eyes in which the root of the iris is attached to the posterior surface of the cornea (peripheral anterior synechia), and an iridodialysis is an exceptional occurrence.

An iridodialysis is no more to be feared than an injury to the canal of Schlemm, as the iris arises from the anterior surface of the ciliary body, and the latter is sufficiently protected through a projection of the scleral spur. Occasionally, the detachment of the ciliary body from the sclera may be plainly distinguished by the recess of the chamber becoming black just as in iridodialysis. After withdrawal of the spatula the ciliary body resumes its original position and the angle of the chamber shows no further visible alteration. If, during the operation, a hemorrhage into the anterior chamber occurs, a pressure dressing must at once be applied. This not only prevents a further

accumulation of blood, but also causes a disappearance of part of the blood already present in the eye.

The operation is undoubtedly much less radical and associated with much less danger to the eye than an iridectomy. To test its influence, I purposely did not permit the aqueous humor to escape from the eye in most of my cases, so that immediately after the operation the eye was as hard as before. In this manner, therefore, I could observe the effects of the operation with the factor of puncture omitted from consideration. I do not mean, however, that one should not let out the aqueous humor, as it may be important to reduce the tension at once. Neither did I use miotics after the operation, although we think their employment is a great advantage, as the consequent contraction of the pupil aids in pulling the freed root of the iris away from the angle of the anterior chamber.

Results.—The results of cyclodialysis develop *gradually* and attain their highest degree only *one to three days later*. According to the condition of the eye after the operation, three kinds of cases may be distinguished: Those in which (1) the tension is reduced permanently; (2) the diminution of the pressure is only temporary; (3) the operation had no influence at all. In the first class of cases (about 20 per cent.) the tension sinks gradually during the first three days after the operation, and the eye may even become softer than normal. The previously hazy cornea becomes lustrous, the anterior chamber somewhat deeper, although it remains shallower than normal, and the pupil a little less dilated than before. In this condition the eye may remain permanently. In about 40 per cent. the diminution of the tension is only temporary, and the increase of pressure returns within a few weeks, while in about 40 per cent. the operation had no effect at all on the glaucoma. This is the result especially in *glaucoma absolutum*.

DE VINCENTIIS'S OPERATION.

Indications.—This operation is employed in instances of a return of tension after other glaucoma operations; in hemorrhagic glaucoma, especially if the other eye has been lost by severe hemorrhage after an iridectomy; in secondary glaucoma occurring during iridocyclitis; and in hydropthalmus.

The Operation.—De Vincentiis employs a slightly curved, needle-like instrument (Fig. 148), which has a small, pointed, sickle-shaped

end, sharp on its convex edge. The shaft thickens gradually toward the handle, so that the puncture hole is completely closed and the aqueous does not escape. The pupil is contracted with eserin, the eye cocainized, and the needle entered obliquely through the sclera

FIG. 148.—De Vincentiis's operation. The needle-like instrument employed.

about 1 mm. back of the limbus and a little below the horizontal meridian, with the convex blade directed downward (Fig. 149). The needle is advanced across the anterior chamber, parallel to the iris, until the point reaches the angle of the chamber at a spot somewhat

FIG. 149.—De Vincentiis's operation. Knife introduced and its point inserted in the angle of the chamber.

lower than the puncture. The point then penetrates into the tissue of the angle a distance of about 1 mm. As the needle is gradually withdrawn, the handle is turned so that the convex blade incises all of the tissues of the inferior periphery of the angle, including the inner scleral layers, until it reaches near the original puncture (Fig 150). The shallower the chamber the more difficult is the operation.

FIG. 150 —De Vincentiis's operation. Incision nearly finished. The handle of the instrument turned up.

The advantages of the operation are that a large opening is not made into the eyeball, and there are not the complications to be feared that are likely to follow an iridectomy in the type of cases mentioned. Should hemorrhage occur in the anterior chamber, a firm pressure-bandage should be applied.

In many instances the operation exercises a favorable influence; in others it fails to reduce the tension.

SCLERAL TREPHINING.

Trephining the sclera immediately back of the limbus to secure permanent filtration has been suggested by both Fergus and Elliott. Both operations are modifications of the Lagrange sclerectomy, that of Fergus being combined with cyclodialysis. Fergus dissects a large conjunctival flap to the corneo-scleral margin, and removes from near the limbus a piece of sclera with the Bowman trephine. A spatula is then entered through the opening in the sclera, and kept in close contact with the sclera and cornea until it appears in the anterior chamber, separating the pectinate ligament, as in cyclodialysis.

Elliott also dissects up a large triangular flap of conjunctiva, the attached base of the triangle lying at the corneo-scleral margin. This flap is loosened close to the limbal attachment of the conjunctiva by the points of the scissors directed toward the posterior pole of the lens, undermining the limbus and forming a deep groove. If the dissection is made in a tangent with the ball, the flap will be button-

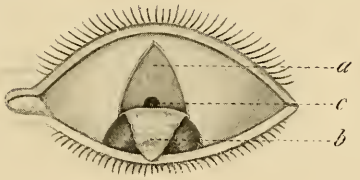

FIG. 151.—Scleral trephining. The conjunctival flap has been turned over the cornea, and the sclera trephined close to the limbus; a., exposed sclera; b., flap of conjunctiva turned down over the cornea; c., hole through sclera made by trephine.

holed. The trephine is from 2 mm. to $2\frac{1}{2}$ mm. in diameter and is placed as close to the limbus as possible. Before using the trephine all conjunctival tissue is scraped or cut away, otherwise the flap will be drawn upon as the parts are trephined.

It is advisable to press a little more on the corneal than on the scleral edge of the disc to be cut out, so as to be certain of entering the chamber as far forward as possible. The trephine is raised from time to time to note the depth of the cut. The operator is conscious of the completion of the cut by the lack of resistance, by escape of the aqueous, and by the movement of the patient from the slight pain which accompanies the opening of the chamber.

In many instances the disc remains attached at one small point, and is removed with the scissors, leaving a clean cut circular hole without ragged edges (Fig. 151). The conjunctival flap is then replaced, and three sutures inserted, one above and one at each side.

OPERATIONS FOR SECONDARY GLAUCOMA.

Secondary glaucoma may follow perforating wounds of the eye, with anterior synechia; injury or dislocation of the lens, and after operations on the lens; serous iritis and cyclitis; and intraocular tumors.

The indications for operation are dependent upon whether the phenomena are only *temporary* or whether the increase of pressure will remain *permanent.*

Paracentesis of the Cornea.—Operation is indicated in transient increase of pressure, as, for example, in traumatic cataract with rapid swelling of the lens; and in acute iritis, in which the increased tension is associated with pathologically deep anterior chamber. The operation should not be done until after the usual local applications of ice-compresses and atropin have failed, especially in cases of iritis.

The Incision.—The eye is cocainized, fixed laterally, and a narrow keratome, held almost vertically against the limbus below, is entered through the cornea. As soon as the point appears in the anterior chamber, the blade is changed to the plane of the iris, and the incision completed, which must not exceed 3 mm. in length. All backward movement of the lancet should be avoided, so that the aqueous will not escape.

When the lancet is withdrawn, the wound-edges come together and the aqueous cannot flow off. The operator may permit it to run out as slowly as he desires, and in any quantity he pleases, by slightly depressing the scleral wound-margin with the spatula, thus causing the wound to gape slightly. Sudden escape of the aqueous is not only painful, but may cause prolapse of the iris and hemorrhage in the anterior chamber and even in the retina as a result of the sudden diminution of pressure.

If the pressure is greatly increased, it is our custom not to permit all the aqueous to escape, but only sufficient to reduce the tension to normal or a trifle below. Thus, we are more likely to prevent disastrous intraocular hemorrhage. If the iris has floated out during the sudden escape of the aqueous, it is at once accurately replaced with a

spatula. When the incision is too long the protrusion of the iris is often repeated, and excision of a small piece is indicated.

Puncture of the cornea may be repeated as often as needed. If, for example, in acute iritis the tension increases the next day, the eye is cocainized, the scleral lip of the wound slightly depressed with the spatula, and the aqueous allowed to again escape. The wound does not heal so firmly for several days as to prevent easy re-opening by passing the spatula carefully between the edges.

If the increased tension is due to a swollen lens, a larger incision (5 mm.) is made to permit some of the lens masses to escape by massage, as in linear extraction.

In progressive corneal ulcers the paracentesis is frequently combined with cauterization of the ulcer. The puncture may be advantageous in ulcers in which a rupture is imminent, since the obliteration of the anterior chamber by the puncture, instead of spontaneous rupture, prevents sudden escape of the aqueous and prolapse of the iris. In chronic inflammation of the cornea (*keratitis profunda*) puncture occasionally exerts a favorable influence on the disease process.

Iridectomy.—Increase of tension not of transient nature requires the typical iridectomy. This is especially true if the glaucoma is due to adhesion of the iris to the cornea or to change of position of the lens, and other conditions previously mentioned.

The performance of the iridectomy in secondary glaucoma may be difficult because of the accompanying pathological changes in the eye. For instance, the iris may be so atrophic from the chronic inflammation that it tears at each attempt to withdraw it with the forceps, and we must be satisfied with tearing out single pieces instead of excising one section. Again, the iris may have grown fast to the lens capsule, and we may succeed in drawing it forward and in excising a portion, but the pigment layer remains adherent to the capsule, rendering valueless the optical effect of the operation.

Dislocation of the Lens.—In luxation of the lens or ectasia of the sclera severe complications during operation are due to prolapse of the vitreous. Operation should not be undertaken in luxation or subluxation of the lens (except luxation in the anterior chamber) unless rendered necessary by an increase of tension. Experience has shown that some eyes tolerate a displacement of the lens without a corresponding increase of pressure, at least for some time. As the zonula is torn, the vitreous presents in the wound as soon as the incision is made. If

the iris floats forward, it may be easily grasped and excised. If, however, the vitreous pushes the iris backward, all attempts to bring it forward would terminate in failures and should, therefore, be abandoned. Occasionally we may be able to catch the iris with a blunt hook. Should that also fail, one has to desist from excising a piece of the iris. If afterward the wound becomes ectatic, the eye constantly painful because of the increased pressure, and vision ultimately lost, nothing remains except to enucleate the eye.

If the lens is dislocated into the anterior chamber immediate operation is required for its removal, as experience has shown that increased intraocular tension quickly follows. In order to prevent a slipping of the lens backward into the vitreous chamber, the pupil is first contracted with eserin. The anterior chamber is then opened by an incision with the Graefe knife at the upper or lower limbus and the lens



Fig. 152.—Transfixion in seclusion of the pupil.

brought forward with the loop. As the vitreous and anterior chambers communicate, the appearance of the vitreous in the wound is the rule, notwithstanding every precaution.

A cyst of the iris may lead to increase of pressure, and we must not be satisfied with iridectomy alone, but endeavor to extirpate the entire cyst by suitable incision.

Transfixion.—This is especially indicated in seclusion of the pupil from complete annular synechia, in which the body of the iris is pushed forward in a hump. The usual iridectomy is hardly possible, as the root of the iris is often applied extensively against the posterior wall of the cornea. The operation is done with a Graefe knife, which is pushed into the anterior chamber through the cornea 1 mm. to the inner side of the temporal border of the cornea and a counterpuncture made at a corresponding point. The knife is then withdrawn. The points of entrance and exit lie in the horizontal meridian of the cornea, and the blade of the knife, held parallel to the base of the cornea, penetrates through the projecting iris and produces in it sev-

eral openings (Fig. 152), through which a new communication is established between the anterior and posterior chambers. In most cases the iris assumes its normal position almost immediately, and the intraocular pressure becomes normal. If no new inflammation of the iris follows, a permanent result may be expected. If, however, there is a new outbreak of iritis, which would cause a closure of the openings through a formation of an exudate, it is better to proceed to establish a normally deep chamber, and then to perform iridectomy, in order to prevent a recurrence of the increase in tension.

TONOMETRY.

It is now generally recognized that the Schiötz tonometer furnishes an accurate and certain means of determining the intraocular tension. Even the skilled diagnostician concedes the uncertainty of the results of digital palpation, and the uniformity of the readings of the tonometer. While determination of tension with the finger was of approximate value where one eye was still normal, and allowed comparison with the affected eye, it was impossible in binocular affections to accurately judge whether the tension exceeded the normal.

The tests with the tonometer are on the average reliable. Exceptionally great difference is noted between tests with the tonometer and with digital palpation. Thickness and rigidity of the external coats of the eye influence the determinations, as Schiötz himself has stated, since he found a marked difference in the measurements made on the cornea and those on the sclera, the former showing the greater movements of the index-arm of the instrument. This difference must be due to the greater rigidity of the sclera. Measurements made on the thinned cornea of a hydrophthalmic eye of a child must therefore cause greater movement of the index-arm, and hence make the pressure seem lower than it is. On the other hand, the pressure would appear higher in elderly people because of the greater rigidity of the sclera. These are, however, exceptions which can scarcely lead to a clinical error.

Description of the Instrument.—The cylindrical sleeve, b, has two arms, a, by which the apparatus is held between the thumb and index finger. In this sleeve, b, there glides easily the tube, c, which widens at its lower end into a foot-piece, 9 mm. in diameter. The bottom of the foot-piece has a concave surface, with a radius of curvature of 15 mm. Fastened to the tube is the support, d, which carries the scale, e, and a small pin, f, as fulcrum for the unevenly-armed lever, gg′. In the interior of the tube, c, is the long rod, h, 3 mm. in diameter, which

slides easily up and down. The lower end of the rod, which during the examination rests on the cornea, is concave, with the radius of curvature the same as the foot-piece, 15 mm. The upper end of the rod is pointed, and slips through a hole in the different sized weights. At one side of the central opening in the weights is a groove, into which slides a projection on the side of the rod. A slight turn carries the projection out of the groove so that the rod will not fall out as the instrument is held up. When the apparatus is in use, the short arm of the lever, g′, rests on the upper end of the rod, which it follows in movements up and down. The long arm, g, of the lever slides along the indicating scale. The relation of the two arms of the lever is 1 to 20. If the end of the rod is level with the concavity of the bottom foot-piece, the end of the long arm of the lever stands at 0 on the millimeter scale, and if the rod descends 1 mm., then the indicator moves to 20 mm. on the scale. The radius of curvature of the foot-piece, 15 mm., was selected, so that the curvature of the cornea would in all instances be greater than the concavity of the foot-piece.

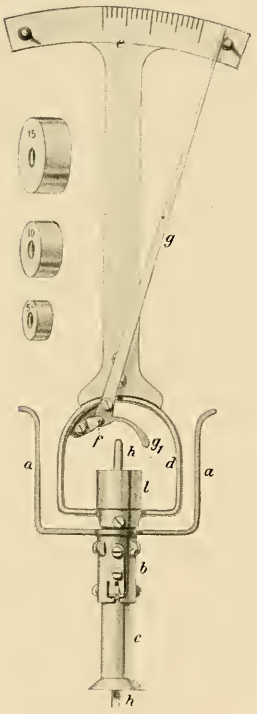

Fig. 153.—Schiötz tonometer.

In the perpendicular position, the indicator falls to the right of the scale, as shown in the illustration (Fig. 153), but in use the upper part of the sliding rod touches the short arm of the lever, and the indicator moves to the left. A metal test block, with a convex surface of the same curvature as the concave foot-piece comes with the instrument, and is used to test its correct adjustment. If the foot-piece is rested on the surface of the test block, the upper point of the rod raises the short lever arm, and the indicator stands at 0 of the scale.

When the apparatus is used (Fig. 154), the eyes are anesthetized with a 2 per cent. holocain solution. The patient lies flat on a table, and is instructed to look directly upward. The examiner separates the upper and lower lids with the fingers of one hand, exercising care that no pressure is made upon the eyeball, and with the other hand holds the tonometer with the smallest weight (5.5) in place. The instrument is held perpendicular, with the concave foot-piece on the cornea, and the sleeve surrounding the tube is moved down until it is about the center of the tube, c, so that in this position the apparatus stands free. The lever and the small arm, with the attached weight, exert pressure on the cornea, and the arm of the indicator gives a reading on the

scale. If no movement of the indicator occurs, a heavier weight is slipped on the rod. The softer the eye the deeper is the impression made by the rod, and, with the short arm of the lever following the sinking point of the rod, the long lever turns on the scale to the right.

Weights of different size are used, marked 5.5, 7.5, 10, and 15. In high tension, no reading on the scale will be given by a certain weight, and a heavier one must be used.

The apparatus should be applied only for a few moments, and the results at once read. Three measurements should be made and the average taken. The examination is begun with the first weight, marked 5.5 gm. If tension is normal, the indicator stands at about 5 mm. In increased tension the indicator rests at or to the left of 0, and the next weight, 7.5 gm. is then used. Readings from 3 to 7 on the scale are the most accurate. If, therefore, a lesser weight gives a result up to this limit, a greater weight is not employed.

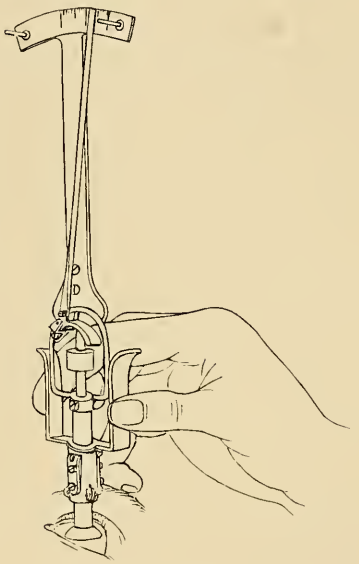

FIG. 154.—The instrument placed on the patient's cornea.

A diagram of curves, each corresponding to the weighting of the apparatus with four weights, accompanies the apparatus. The abscisses of the diagram represent the reading of the tonometer and the ordinates the intraocular pressure expressed in millimeters of mercury. Thus, a reading of six division lines of the tonometer scale with the smallest weight (5.5) is a pressure of 15 mm. of mercury, or with the second weight (7.5) a pressure of 42.5 mm. of mercury.

According to Schiötz the normal intraocular tension, as indicated by the tonometer, varies between 15 to 25 mm. of mercury; others have found the variation between 9 and 26. It is possible, therefore, for an eye to be affected with glaucoma and yet the tension be within the normal limits. This may be regarded as exceptional, and eyes whose normal tension is on the lower physiological border, such as near-sighted eyes, have no particular tendency toward pressure in-

crease. If increased tension does appear it remains within moderate limits, and may be recognized only with the tonometer.

In normal eyes the pressure does not seem to vary much during the course of the day, and is apparently unaffected by the use of mydriatics or miotics. In eyes the subject of iridocyclitis, changes in the vitreous, spontaneous intraocular hemorrhage, and similar conditions, marked variations are to be found. Simple glaucoma almost always shows with the tonometer a slight increase of tension. Only exceptionally is it found below 25 mm.

The tonometer should be employed in all cases of glaucoma and in eyes in which there is a suspicion of increase of intraocular pressure. Notwithstanding the recognized value of the instrument, therapeutic measures should not rest alone on its findings with the exclusion of clinical symptoms. The expressions glaucoma and increase of pressure are not identical. Abnormal intraocular tension is only one symptom of glaucoma, important as it is to the integrity of the eye. Even though the tonometer may indicate a pressure, say of 28 mm., an operation would not be indicated in the absence of the clinical symptoms of cloudiness of vision, narrowing of the visual field, and progressive cupping of the optic nerve. If, however, the increase in pressure were associated with the usual clinical manifestations of abnormal tension, operation would be indicated as soon as the character of the disease is established.

For those who adhere to the medicinal treatment of glaucoma, and operate only as a last resort, the tonometer will be of considerable value in indicating the value of miotics in controlling the tension, and the period when the operation must be performed.

The tonometer also teaches that in types of advanced glaucoma the vision decreases and finally entirely fails notwithstanding decided decrease in the intraocular pressure.

CHAPTER XIII.

OPTICAL IRIDECTOMY—CONJUNCTIVOPLASTY—OPERATIONS FOR IRIS PROLAPSE AND ANTERIOR SYNECHIA.

OPTICAL IRIDECTOMY.

The indications for optical iridectomy are (1) perinuclear opacities of the lens in young persons in whom sight is improved by dilatation of the pupil; (2) central corneal scars; (3) connective-tissue membranes in the pupillary area following iritis.

Nuclear Opacities.—If the opacity only slightly interferes with sight iridectomy is not indicated, but if the disk-shaped cataract is small, and tests with the ordinary sized pupil and with the pupil fully dilated show that vision can be made suitable for the necessities of the individual concerned, *i.e.*, at least a third of the normal acuity, this degree of sight can be obtained permanently by an optical iridectomy, whereby the patient has the advantage of still possessing the lens and with it the power of accommodation. In such cases, the coloboma should be made below and to the inner side.

If, however, the improvement in vision following dilatation of the pupil is not marked, discission of the cataract is indicated. By this means the opacity can be completely removed, and the visual power restored to its normal acuity. The patient, of course, is forced to wear permanently strong convex glasses. In the greater number of cases of perinuclear cataract the latter operation is indicated, and in a much smaller number, iridectomy. The objection made against iridectomy that the cataract will probably become progressive and lead to total opacity of the lens, thus rendering the operation valueless, is, however, not sustained.

Central Corneal Opacity.—The ideal indication for an optical iridectomy is when corneal scars cover the center of the pupillary area. Unless a careful examination of the cornea is made with the magnifying lens, to ascertain the condition of the so-called transparent parts of the cornea, the results of optical iridectomy will often be disappointing. Delicate diffuse opacities will frequently be found in those por-

tions which were judged to be of perfectly normal transparency when examined with the naked eye. Not until the iridectomy is completed are the corneal opacities easily visible against the black background, and they then often seem quite intense, while previously they entirely escaped notice. In examination with the magnifying lens, not only those portions of the cornea must be looked for which are the most central and transparent, but also the areas where the opacity contrasts most sharply with the surrounding parts. The sharper the margin, the denser the opacity; the broader the remaining transparent border, the better the outlook for a good result.

Optical iridectomy for corneal opacities should not be performed too early. Opacities resulting from deep-seated keratitis, especially after parenchymatous keratitis in young people, often clear up slowly after many months, but the scars after severe ulcerative processes in adults usually remain unchanged. The operation is, therefore, particularly suited to cases in which the opacity has resulted from a well-circumscribed area of disease (especially from ulcus serpens, infected wounds, etc.) while the rest of the cornea has remained practically free. A less favorable result may be expected when the opacities have resulted from deep corneal inflammations, because the cornea is usually so affected that delicate, grayish, indefinite areas are found throughout its entire structure. Optical iridectomy, therefore, improves the vision but little, even when the pupillary area of the cornea is affected by a rather dense opacity. It must be remembered that the diffuse haziness of the peripheral portion of the cornea often causes marked disturbance of vision.

Before operation it is necessary to make an exact determination of the visual acuity after painstaking correction of the errors of refraction, especially astigmatism, by the use of a movable stenopaic disk. This disk is lodged in a frame that can be adjusted to any pair of spectacles, and may therefore be readily rotated into the various meridians. As often only a certain definite position of the slit gives the patient a substantial improvement in vision, the ordinary examination with the trial frame commonly found in the test-case does not serve the purpose. We determine the lens that gives the patient the best vision for near work and for distance, order the lenses from the optician, and then adjust the disk to the glasses, so as to indicate to the optician the position the slit is to occupy on the lenses. This method of examination is of the greatest importance, especially for

those patients who are dependent upon one eye. The improvements occasionally produced by application of the stenopaic disk are quite marked, and not infrequently the vision can be increased from finger-counting at 2 meters to $\frac{6}{24}$ or $\frac{6}{18}$, and restoring also the power of reading and writing.

Tests with Dilated Pupil.—Before deciding on operation we determine the effect on vision of an optical iridectomy by dilating the pupil with atropin. Artificial mydriasis, however, cannot be exactly compared to that produced by an optical iridectomy, as atropin dilates the pupil symmetrically; but the operator learns from such an examination that in complete absence of improvement from uncovering a portion of the pupil behind a less clouded part of the cornea, a satisfactory result cannot be expected from an optical iridectomy. Moreover, if the patient's vision is lessened by dilatation of the pupil, a permanent reduction in his sight will follow an optical iridectomy, as it is in such cases that the impairment of the sight is dependent upon the irregular diffusion of the rays of light. Many persons with diffuse corneal opacities see much better with a contracted pupil, comparable to a stenopaic disk, than with the pupillary orifice widened.

Tattooing the Cornea.—Frequently it is necessary to decide whether the vision may be improved by tattooing of the cornea, with or without subsequent iridectomy. In such cases it is recommended to tattoo the corneal scars provisionally, as it were, by applying a piece of fine silk paper, absolutely black in color and cut to exactly fit the opacity in the cornea. This paper adheres readily and makes possible a test of the visual power for comparison with the earlier test. In order that the piece of paper can be applied, the cornea should be rendered anesthetic by the use of alypin, which unlike cocain has no influence on the pupil, so that there is no artificial dilatation to modify the results. (See page 242.)

The Operation.—The technic of optical iridectomy differs from that of iridectomy for glaucoma not only in the method of incision but also in the type of excision of the iris. As the purpose of optical iridectomy is to alter the position of the pupil slightly, only that portion of the iris which borders on the pupillary margin should be excised. As the periphery of the iris must be preserved for optical reasons, the incision is placed in the limbus or a little in the cornea. Otherwise, essentially the same details are followed as in iridectomy for glaucoma. The incision is made with the lancet, except when a

shallow anterior chamber, the result of an anterior synechia, compels the use of the Graefe knife. Whenever possible, the coloboma is made to the inner and lower quadrant, as experience shows that this position gives the best optical results. Often, however, there is no choice, and the iridectomy is to be made behind any clear portion of the cornea. Care must be taken that the coloboma is not entirely covered by the upper lid. If in a one-eyed individual only the part of the cornea covered by the upper lid remains transparent and is suitable for an optical iridectomy, nothing remains but to produce a permanent depression of the eyeball by tenotomizing the superior rectus, so that the coloboma will lie uncovered in the palpebral fissure.

The iris is withdrawn with the forceps in the same manner as previously described. It is sufficient, however, to draw out the smallest possible fold and to cut off the tip with the blades of the de Wecker scissors held perpendicular to the corneal incision. In this manner, a coloboma limited to the pupillary border of the iris is produced, which at once enlarges considerably by retraction of its margins.

Precorneal iridotomy is an operation to obtain a smaller coloboma. It consists in drawing the iris out of the wound, making a radial incision in the pupillary margin, and then replacing the membrane. As the ends of the cut sphincter retract, a small coloboma is formed, and it is nearly impossible to tell whether it was produced by an iridotomy or an iridectomy. The operation is seldom performed, as the replacement of the iris after it has been in contact with the conjunctival tissue is liable to lead to infection.

Results of Optical Iridectomy.—The value of the operation in corneal opacity is only moderate, and the cases suitable for the operation are relatively few. The beneficent clearing effect on corneal opacities which has been ascribed to iridectomy depends probably only upon a delusion, which has been originated by the improvement of vision that follows the natural clearing of the cornea in the eyes in which iridectomy was performed before the healing process had subsided.

Optical iridectomy gives much more favorable results in central lenticular opacity, that is, large central capsular cataract, and especially in dense lamellar cataract in which the opacity is sharply defined and has a small diameter.

Exudates, such as the connective-tissue membranes in the pupillary area following iritis, also afford an indication for optical

iridectomy. Of course, due consideration must be given to the usually existing adhesions of the iris to the capsule of the lens resulting from the iritis, and a broader iridectomy performed in order to prevent a later rise in pressure. The result may be nullified, however, by the pigmented layer of the iris membrane adhering to the capsule of the lens and covering the coloboma.

PROLAPSE OF THE IRIS.

Every Prolapse of the Iris, if Not Too Large, Should be Excised.—Attempts at reposition of a prolapsed iris should be avoided, because they are useless and expose the eye to infection. The replaced iris will again prolapse. It is, therefore, best to excise not only an iris that has protruded through the opening of a perforated ulcer or through a wound due to injury, but also a prolapsed iris following an extraction of cataract without iridectomy.

The Operation.—After that portion protruding from the opening is cut off, the iris should be completely freed from its connection with the wound, in order to avoid the formation of an anterior synechia, with its sequelæ. If a day or more has elapsed since the injury, the prolapsed iris is covered with fibrinous exudation, making its borders indefinable. This exudate must first be pulled off with forceps, after which the black point or swelling of the prolapse makes its appearance. By means of a conical sound the prolapse is then freed from the edges of the wound in all directions, care being taken to avoid wounding the capsule of the lens, which, by obliteration of the anterior chamber, lies close to the posterior surface of the cornea. The sound is carefully pushed around the whole periphery of the opening between the prolapse and the posterior surface of the cornea, so that the iris is loosened on all sides. During this procedure the aqueous humor is continually escaping. The prolapsed iris is then seized with the iris forceps close to the opening, drawn out a little, and cut off with the de Wecker scissors close to the edge of the wound. As the iris usually retains its power of retraction, it withdraws itself immediately after the excision into the anterior chamber and produces a well-situated coloboma in place of the previous prolapse.

If the edges of the coloboma do not lie in a proper position, and the size of the opening permits, it is advisable to introduce a spatula and replace the iris. Should the corneal wound be too small the iris should be again drawn out and excised. If, however, the iris does not retract,

a blunt tenaculum may be introduced into the anterior chamber, and the iris withdrawn from the wound, and properly excised. After operation a drop of atropin is instilled in the eye to retract the iris and prevent its adhesion to the edges of the wound.

Recurrence of the prolapse through perforation of an ulcer is not a contraindication to its immediate excision, notwithstanding the claim that there is great possibility of an infection of the interior of the eye through replacement of the borders of the coloboma. Indeed, if the tendency to infection should exist, the prolapse would afford the best channel by which the microörganisms could gain entrance to the eye.

Before excision of the iris, a 3 per cent. cocain-solution should be instilled. As the eyes are usually much irritated and injected, adrenalin should be used simultaneously, as the cocain develops its greatest effect after contraction of the blood-vessels. Notwithstanding thorough cocainization, the iris often remains extremely sensitive, and, notwithstanding fixation of the eyeball, an abrupt movement of the patient at that moment when the iris is drawn out and excised may give rise to severe injury of the iris (iridodialysis). In children the operation should always be done under general anesthesia. This should also be the rule in restless and timorous adults.

A wound of the capsule of the lens can be readily avoided if the operator takes sufficient precautions in introducing the blunt tenaculum for the purpose of replacing the iris. However, this accident may be caused by restlessness on the part of the patient during the undermining of the prolapse with the pointed conical sound. If cocain is dropped directly on the prolapsed iris after it is uncovered, its sensitiveness is greatly diminished.

The wound in the cornea which remains after excision of the prolapse usually closes rapidly; frequently the anterior chamber is reestablished on the day after the operation. The smaller the opening, the more readily and surely does the wound close. A large wound of the cornea should be closed with a conjunctival flap. (See page 234.)

Large Corneal Wounds with Iris Prolapse.—It is our established rule *not to excise a prolapse of the iris if the opening amounts to one-fourth the diameter of the cornea.* Naturally, this cannot be readily determined in advance. A large prolapse sometimes comes out through a small opening and, with mushroom-like swelling, overlaps the borders of the corneal wound. If the patient has been seen before the prolapse occurred, the operator will not be thus deceived, but it may

happen that the real conditions are revealed only at the time of operation, when undermining the prolapse. If one-fourth or more of the cornea has been lost by ulceration, the excision of the iris brings the lens capsule to lie in the wound throughout its extent. As the scar-formation is not as rapid in the cornea as it is in other tissues, the wound may remain open for some time, and during this period the eye is constantly exposed to the danger of infection. If the exposed lens capsule cannot withstand the intraocular pressure, it finally protrudes and ruptures, the lens-substance first appears in the opening and later the hyaloid membrane bursts, allowing the vitreous humor to prolapse. These sequelæ are to be feared only in large prolapses, such as occur in destruction of the cornea by acute blennorrhea or serpiginous ulcer. But, even with the medium-sized openings, the operator has to be satisfied if a flat cicatrization results, with fusion of the lens capsule and partial or total clouding of the lens. Frequently these cases end with a slowly developing atrophy of the eyeball. Therefore, it is best not to excise the prolapse, which is the natural means of closing the large wound. The endeavor should be rather to produce merely a flat cicatrix. Therefore, the intraocular pressure should be carefully controlled, and, if it rises, an immediate iridectomy done.

After-treatment.—If extensive anterior synechia has occurred, an iridectomy should be performed before the patient leaves the hospital, in order to avoid the danger of increase in pressure and development of a staphyloma. The continuous application of a pressure-bandage is advisable to produce a flat cicatrix. A typical picture is seen in those patients who have suffered from a well-advanced serpiginous ulcer. An extensive synechia of the iris has been produced, either spontaneously or after Saemisch's incision, with a peripheral part of the cornea still transparent. At first the tension is reduced, but finally becomes normal. At the seat of the prolapse there is formed a flat scar. Suddenly the pressure increases, usually with violent pains, and immediately the still soft cicatrix, which is often the seat of hemorrhages, protrudes in the form of a hump. Under such circumstances the performance of iridectomy is difficult, as the anterior chamber is usually obliterated, the iris atrophic, and the eye painful. This almost invariable result can be avoided if a broad iridectomy is executed in the unaffected portion of the cornea as soon as an anterior chamber has been established during the course of cicatrization of the prolapse and before tension rises.

CONJUNCTIVOPLASTY.

Transplantation of a pedicled flap of conjunctiva, especially advocated by Kuhnt, is a significant advance in the treatment of large prolapses of the iris.

The method is also used in the treatment of recent corneal wounds, with or without iris prolapse; in transplantation of the cornea, to retain the new tissue in proper position; in gaping incisions after cataract extraction; and in some types of corneal ulcers.

Flaps after Excision of Prolapsed Iris.—After excision of a prolapsed iris, a clean perforated ulcer lies exposed. If the edges of the defect are flat and offer a large surface for adhesion to the conjunctival flap, the margins should be scraped with a sharp curet, to remove the epithelium that has grown over them. If the edges of the wound are perpendicular, the chances for fusion with the flap are

FIG. 155.

FIG. 156.

FIG. 155.—Conjunctivoplasty. Diagram showng appearances after excision of the prolapsed part of the iris. The ulcer in the lower half of the cornea is free from the iris, which shows the ordinary coloboma. To cover this defect a flap has been cut out of the bulbar conjunctiva.

FIG. 156.—Diagram showing the conjunctival flap turned over the ulcer, and attached to the bulbar conjunctiva in such manner that the ulcer is completely covered.

less favorable. A flap is now made from the bulbar conjunctiva by first detaching with the scissors the conjunctiva at the limbus close to the ulcer, making a second cut parallel to the first at a distance almost twice as great as the width of the ulcer, and uniting the two by a curved incision (Fig. 155). The flap formed is undermined, and its base removed far enough back to render it freely movable. If the ulcer is at the edge of the cornea, the flap may arise from the bordering limbus; but if the loss of substance is central, it may be covered by a flap brought either horizontally or vertically over it. In the former, the detachment of the conjunctiva must be performed above or below, and the base of the flap lie externally or internally. A vertical flap is, therefore, to be preferred, on account of the abundance of conjunctiva in the superior fold, which readily permits the formation of a flap, while internally and externally there is little con-

junctiva to spare. The only objection is the possible danger of limiting the movements of the eyeball by shortening the conjunctival fold.

After the flap has been rotated to the correct position, so that it well covers the loss of substance, its apex is fastened by a few fine silk sutures to the bulbar conjunctiva on the side opposite to that on which the base of the flap is attached (Fig. 156). As the conjunctiva often shows a tendency to curl, one or more sutures may be introduced through the lateral edges of the flap, in order to keep it well stretched. The wound in the bulbar conjunctiva left by excision of the flap may be permitted to heal by itself, especially if there is difficulty in drawing upon the surrounding membrane; or an attempt may be made to at least partly close the defect by undermining the wound-edges and inserting sutures.

After-treatment.—Both eyes are bandaged for three days to insure retention of the flap by excluding the possibility of ocular movements. Before applying the dressings, the operator should assure himself that the flap does not shift its position during the upward rotation that accompanies closure of the eyelids, and, if necessary, introduce an additional suture to prevent this displacement. The bandage should be changed on the following day, as we have to deal frequently with excessive conjunctival and lachrymal secretion. At first the flap appears quite swollen, and some time may elapse before it again assumes the condition of normal conjunctiva. It is generally not necessary to remove the stitches, as they drop out of themselves in a few days. If the loss of substance has occurred in the middle of the cornea, the separation of the flap from its base can be undertaken when the eye has become completely free from congestion and the process of healing is at an end. The results of this operation are in many cases remarkable, but occasionally, notwithstanding closure of the ulceration, an atrophy of the eyeball finally sets in. Of course the method cannot be blamed for these bad results, as they are caused by severity of the primary injury.

Flaps in Corneal Injuries.—A double pedunculated conjunctival flap (Fig. 157) may be employed in peripherally located corneal wounds in the same manner as described in the operation for cataract (page 170). The flap, formed by two curved incisions of the conjunctiva a short distance from and parallel with the limbus, after being drawn over the corneal wound, is fastened near the two attached ends

to the conjunctiva of the eyeball. The conjunctival bridge draws back to its normal position after a few days.

Instead of incising the conjunctiva to form a bridge of tissue, the membrane may be drawn over the corneal wound, apron-like, as shown in Fig. 158.

In extensive injuries de Wecker undermines the conjunctiva on all sides from the limbus to the insertions of the recti muscles, after which this movable conjunctiva is drawn completely over the cornea and

a b

FIG. 157.—Kuhnt's double pedunculated conjunctival flap. a., the dotted lines indicate the incison through the conjunctiva, the black line in the cornea indicates the wound; b., the flap drawn over the wound.

closed in purse-string fashion by several sutures. The raw surface of the conjunctiva closes the defect and fuses with the edges of the wound. After completion of the cicatricial process, the conjunctiva may again be detached, after which it returns to its normal position in all directions, with the exception of the point of fusion. A total detachment of the conjunctiva is not always necessary, as a partial separation will often supply sufficient membrane to be attached to the opposite limbus and cover the corneal defect.



a b

FIG. 158.—a., conjunctiva detached only at the limbus (dotted line); b., conjunctiva drawn down apron-like over the wound.

Large Scleral Wounds.—In wounds of the sclera with prolapse of portions of the ciliary body or choroid, in which there is hope of preserving the eye, the same rule is to be observed as in prolapse of the iris. The prolapsed portion which lies exposed in the wound is excised, but, for reasons that can readily be understood, we avoid drawing upon the prolapse with the forceps. The wound is closed by a conjunctival flap. If it is desired to introduce scleral sutures, they must include only the superficial layers of the sclera, so that the needle

does not produce a perforation and thus cause a fresh injury of the deeper parts. Scleral sutures are usually not employed, as the pressure necessary to pass the needle through the sclera causes further protrusion of the vitreous which lies in the wound. Scleral sutures are advisable only if the wound gapes, in which case they will prevent the formation of a wide cicatrix that upon contraction would likely lead to detachment of the retina. Absolute rest of the patient and bandaging of both eyes during the first few days are requisites to promote healing of the wound. If a large part of the ciliary body or of the choroid has prolapsed, the best course is to enucleate the eyeball at once. The patient is thus relieved of a long convalescence, which ends with an atrophic, painful bulb that is a source of danger, and may cause sympathetic ophthalmia.

OPERATIONS FOR ANTERIOR SYNECHIA.

Increased tension may occur in cases of anterior synechia, in which the corneal scar is not only flat but also solid, especially if a considerable portion rather than a small tip of the iris is adherent to the scar. It is difficult to give a general rule for operative interference in anterior synechia—a flat cicatrix being naturally implied. An ectatic scar should be subjected to operation under all circumstances. (See page 246). But, in our opinion, an operation is not required in every case of anterior synechia with flat solid cicatrix.

Indications.—The following are considered indications for operation: (1) If the fusion is extensive, so that a large part of the pupillary border is adherent to the cicatrix. (2) If signs of increased pressure are present even though they occur intermittently. (3) If the cicatrix, although originally flat, begins to yield to the intraocular pressure and protrudes. (4) If dislocation of the pupil, as a result of distortion of the iris, hides the pupillary opening completely behind the cicatrix. A drawn up pupil from a peripheral adhesion of the iris, or a pupil covered by a central corneal cicatrix, demands operation on essentially optical grounds.

Operation is not indicated if the adhesion consists merely of a fine filament which unites the anterior surface of the iris with a solid corneal cicatrix, or if a small part of the pupillary border is attached to the cornea, provided the cicatrix is firm.

If the iris has healed in an operation cicatrix, as after an iridectomy for glaucoma, and one or both sides are adherent to the wound, no

additional interference is called for if tension is normal and the operative cicatrix remains flat, presenting at most a dark coloration of the scar due to the adhesion of the iris.

Temporary Resection of the Cicatrix with the Trephine.—While we were formerly well satisfied with iridectomy in all of the above mentioned cases requiring operation, we now prefer a temporary resection of the cicatrix with the aid of the trephine—a method which was first recommended by Sachs. As the scar is solid, it does not require to be replaced by a piece removed from another cornea, as in a fistulous or ectatic cicatrix. (See page 246.)

In order to avoid the danger of delayed healing of the excised flap of cornea, it is only separated in a little more than half its circumference by placing the trephine obliquely upon the cornea. In this way an assistant may lift the flap like a lid with a sharp tenaculum, while through the opening thus produced the operator enters the anterior chamber with the forceps or a tenaculum, draws the iris carefully out on all sides and excises it. The base of the flap is so placed that the iris can be most readily reached through the opening produced by lifting the flap. In most cases, therefore, this base will lie toward the center; that is, toward the pupil. After the iris is completely freed, the flap is returned to its original position, in which it is firmly held by the pressure of the upper lid when the eye is closed. A light compress and bandage may be used to support the lid. By the use of atropin an attempt is made to retract the iris as far as possible from its former point of adhesion. The anterior chamber will be re-established on the next day, but it is advisable to keep the eye bandaged for at least one week. The corneal cicatrix, which was formerly somewhat thin and had already become slightly ectatic, is often observed to become flat and solid after this operation. After detachment of the iris from the cicatrix, the former withdraws, and the pupil returns to its position behind the center of the cornea. Therefore, by this means not only have the optical disturbances been remedied but also the anterior synechia is removed. When the eye has become entirely free from inflammation, and healing is complete, the scar may be tatooed.

The only danger in trephining the cornea lies in an injury to the lens. Sometimes this cannot be avoided, as, for instance, when the lens capsule is adherent to the scar, and the capsule is cut when the corneal cicatrix is incised. But injury to the lens is not so important,

as it is usually cloudy and, in young persons, frequently shrunken. The most dreaded sequel occurs after the escape of the lens-substance, when the delicate hyaloid membrane appears in the wound, ruptures, and leads to prolapse of the vitreous and prevents completion of the operation.

Iris Healed in an Operation Cicatrix.—Usually these synechia cause no trouble, but should increased tension arise, the adherent iris must be removed. If the attached iris followed an iridectomy for glaucoma, it would be a mistake to proceed immediately to the performance of a second iridectomy, as the latter, being carried out inferiorly, would exert an unfavorable influence upon the visual function. It is necessary, therefore, to remove the adhesion of the iris.

One method of operation consists in making an incision with a lancet corresponding to the adherent side of the coloboma, and as near the periphery as possible. The iris is then drawn out with the iris-forceps and excised, after which it either spontaneously returns to its proper position or is replaced with a spatula.

A much safer procedure, and one that guards against the possibility of an injury to the lens, is to make an incision in the region of the iris-adhesion similar to that of an anterior sclerotomy. A Graefe knife is introduced on one side of the adhesion, and brought out of the anterior chamber on the other side of the adhesion, and a scleral cut made as near the periphery as possible, so that the iris is thereby severed from its adhesion. The incision need not completely sever the flap, especially if a prolapse of the vitreous humor is to be feared. If the iris does not retract after the incision, this method also permits the operator to draw the membrane out with tenaculum or forceps and excise it to its proper position.

Adhesions consisting merely of a fine filament joining the iris and cornea, or a small adhesion of the pupillary border to the cornea, may be divided by a needle-knife or Graefe knife.

Period When Excision is Safe.—No definite time can be stated as to how long after the occurrence of the prolapse may excision be undertaken. The possibility of loosening the prolapsed iris with the conical sound pre-supposes a loose connection between the iris and the edges of the wound. If cicatrization has advanced too far the undermining with the sound can no longer be carried out. No definite time can be stated. Even after two or three weeks adhesion between the prolapsed iris and the edges of the wound may be slight, so that their

separation, though difficult, is still possible. When the cicatrization has already led to a firm union, so that an ectatic black scar is seen in place of the prolapse, the manner of the operative interference again depends materially upon the size of the prolapse. The simplest method is to avoid freeing the iris from the corneal scar and to perform a broad iridectomy behind the normal portion of the cornea. In this way the pressure is diminished, and, by simultaneously applying a pressure-bandage, an attempt is made to produce a flat cicatrix. Although this simple procedure often leads to the desired result, it fails in many cases, for the ectasis of the cicatrix sometimes does not disappear after iridectomy, and the eye may be destroyed by a renewed increase in pressure.

For these, as well as for all other cases of anterior synechia (especially when the cicatrix is not solid, but dimly transparent or somewhat ectatic), modern ophthalmic surgery has proposed separation of the iris from the cornea, and has devised various methods for its accomplishment.

When the scar is small and the prolapse the size of a fly's head or slightly larger, it is best to cut off the protruding cicatrix with a lancet applied flat against the cornea. The opening in the cornea is usually too small to permit the introduction of iris-forceps for the withdrawal and excision of the iris. The latter is better accomplished by means of a blunt hook. After its excision, the iris is either drawn back spontaneously into its proper position, or it may be pushed back with the blunt tenaculum, as the introduction of a spatula through the small opening is impossible. The small wound cicatrizes in a short time, and the anterior chamber is usually established on the following day.

When the ectatic cicatrix is large, it is removed with the lancet as before, and the iris is more readily excised, as it can be drawn out with the forceps. After this has been done, the defect is covered with a conjunctival flap as already described, the conjunctiva replacing the cicatrix.

CHAPTER XIV.

OPERATIONS ON THE CORNEA.

PARACENTISIS—TATTOOING—KERATECTOMY—KERATOPLASTY.

Paracentisis and Cauterization.—If medicinal measures of treatment of purulent ulcers of the cornea, including sub-conjunctival injections of 1-1000 corrosive sublimate solution, and touching the infected area with carbolic acid, formol, or tincture of iodine, fail to stop the progress of the ulceration, the thermo-cautery must be at once employed, with puncture of the anterior chamber. The cautery is applied to the entire ulcer, paying especial attention to its yellow, infiltrated, progressing borders. A simultaneous puncture of the anterior chamber has a favorable influence on the course of the disease, and should therefore not be neglected in view of the insignificance of the procedure. It makes no difference whether or not the hypopyon is thereby removed from the eye. If the ulcer has penetrated deeply, the opening of the anterior chamber may be accomplished after first thoroughly cauterizing the whole ulcer by burning through the cornea in a punctiform spot, so that the aqueous humor trickles out slowly. The slight perforation soon closes, and an adhesion of the iris is not to be feared if the opening is in the region of the pupil.

A puncture in the limbus with the lancet fulfils the same purpose as perforation with the cautery in relieving the tension and relaxing the corneal tissue, and at the same time permits the removal of the hypopyon. It is therefore to be preferred. Should new areas of infiltration later appear, cauterization of the ulcer must be repeated.

Saemisch Section.—Serpiginous ulcers that have affected more than one-third of the cornea are not longer amenable to this form of treatment, as the extensive destruction of the cornea in its whole thickness leads to perforation before completion of the cauterization. It is in these cases, and only in these cases, that splitting the cornea according to Saemisch method is indicated. The cocainized eye is held with the forceps below, and the cornea is then split in the region of the serpiginous ulcer with a Graefe knife. The knife, with the cutting edge directed forward, is introduced into the healthy part of the cornea

close to one edge of the ulcer, and is brought out at the opposite edge, so that the ulcer is cut through (Fig. 159). The blade of the instrument must be parallel to the cornea, in order that the lens will not be injured. By a slow, sawing motion, the cornea is then split in the region of the ulcer from behind forward. The incision is so directed that it passes through the extending, yellow, infiltrated part of the border. The aqueous humor escapes rapidly through the incision, and the hypopyon is frequently forced into the wound, whence it can readily be extracted in a compact mass by a pair of forceps.

After-treatment.—The opening into the anterior chamber must not be allowed to close until the ulcer has become clean and retrogressive. The reopening of the incision on the succeeding days is not difficult, and may be accomplished by slightly depressing one lip of the wound with a spatula. The splitting of the cornea does not always

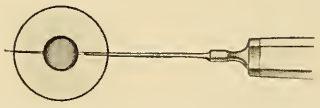

FIG. 159.—Saemisch incision through serpiginous ulcer.

have the desired effect, and the serpiginous ulcer progresses further and destroys the whole cornea. However, a favorable result usually follows, but the operation has the disadvantage of causing extensive attachments between the cornea and the iris. These adhesions cannot be avoided, but we select the Saemisch section only in advanced serpiginous ulcers to preserve an eye that would probably otherwise be entirely ruined by infection.

Before the patient leaves the hospital, a broad iridectomy is performed behind the transparent part of the cornea, to prevent the otherwise certain onset of increased pressure, which would completely destroy the visual power and cause the patient other inconveniences through the transformation of the flat cicatrix into a staphyloma. Serpiginous ulcers are frequently associated with purulent disease of the lachrymal canal, and an important part of the treatment of the corneal affection is the immediate removal of the diseased sac.

TATTOOING THE CORNEA.

Only solid, flat scars of the cornea are suitable for tattooing. If there is a tendency to ectasis or if the scar is thinned, tattooing is to

be avoided. India-ink is the only pigment applicable for the purpose. It is introduced into the corneal scar by pricking either with a cluster of needles (Fig. 160), or with a single, broad needle, provided with a groove for holding the coloring matter (Fig. 161). In order to produce the best results, the tattooing must usually be done in several sittings. Thorough cocainization is always necessary. To hold the eye steady, the conjunctiva should be grasped with slightly roughened forceps, as toothed forceps produce slight wounds which become impregnated with the pigment.

FIG. 160.—Cluster of needles.

Tattooing with the cluster of needles is to be preferred to that done with the grooved needle. The latter is better suited, however, for accurate definition of the border. With the cluster of needles which is put in vertically, the operator produces simultaneously a series of closely-placed points, and, therefore, works more rapidly. There is also less danger of perforating the cornea than with the grooved needle, which has to be applied in a slanting direction to prevent perforation. If the latter should accidently be produced and the pigment enters the anterior chamber, the latter must be opened with a lancet and washed out.



FIG. 161.—Grooved needle.

Froelich's method is an excellent procedure for imitating a beautiful, round, black pupil. It is recommended for very large and thick, flat scars. With a von Hippel trephine a superficial furrow is cut, corresponding in position and size to the pupil of the other eye. Then, with a lancet applied on the flat, the superficial layers of the cicatrix, containing epithelium and a few lamellæ, are removed in the form of a disk. The exposed base is scarified in all directions with the cutting edge of the lancet and the ink is rubbed in well. In this way a pronounced and uniformly black pupil is produced, which closely resembles a true pupil. The surroundings are then tattooed by pricking with the cluster of needles until the desired shade is produced.

CONICAL CORNEA.

Conical cornea (Kerataconous) is treated either by trephining or by cauterization with the galvano-cautery.

Trephining.—The pupil is dilated with atropin, several drops of a 3 per cent. cocain-solution instilled, and a disk, 1 mm. in diameter, excised with the trephine from the exact summit of the cone and through the entire thickness of the cornea. Only a few rotations of the instrument will be required to penetrate the thinned cornea. As soon as the circular blade has cut through, the instrument is immediately withdrawn to prevent injury of the lens. The aqueous gushes out, the pupil contracts, and the cornea collapses, forming small radiating folds around the opening. As most of the trephines in use have crowns larger than 1 mm., a special blade must be secured, as a larger opening than 1 mm. is not to be made.

Both eyes are bandaged, and the patient put to bed. Atropin is to be used every five to six hours until the wound is healed and the anterior chamber reformed. Neglect of this course will result in adhesion of the iris in the opening, with the usual serious consequences of anterior synechia and increased tension.

The anterior chamber is often restored in three or four days, although a week or two may elapse before closure of the wound occurs. Until healing is complete, the patient should remain in bed with both eyes bandaged. Afterward, the operated eye is bandaged for several months, at first gently, to prevent breaking open of the wound, but later more firmly to secure as flat a cicatrization as possible. Occasionally the dressings are removed for a few hours, and then, as firmer union takes place, applied only at night. The use of atropin is indicated by the ocular injection.

The resulting scar is not perfectly round, having slightly scalloped edges, but is never so prominent as to require tattooing.

The results of the operation are superior to other forms of treatment, not only in the ultimate results as to vision but in its safety. The smallness of the scar renders optical iridectomy unnecessary, while the flattened cornea restores good vision, which in the majority of instances is permanent. In the event of insufficient flattening a second trephining may be made close to the first. Most of the discredit that the method received was due to the excision of too large a disk from the cornea.

Cautery Puncture.—Cauterization of the summit of the cone is frequently performed. The central area is touched with the cautery loop brought to red heat, and, if a thorough effect is desired from one cauterization, perforation is made. The scars after this procedure are much larger and less sharply bordered than after trephining, and usually require subsequent tattooing and almost always optical iridectomy. The visual results are therefore usually far from satisfactory.

CORNEAL STAPHYLOMA.

Keratectomy.—Beer-de Wecker Operation.—This method is employed for the removal of a complete corneal staphyloma. The conjunctiva is detached around the limbus, as in the operation for enucleation, is thoroughly undermined, and a purse-string suture introduced, which is at first left loose. The epithelium on the limbus and the border of the staphyloma is then carefully denuded, in order to produce a raw surface to which the conjunctiva can adhere when drawn over it. The staphyloma is then cut away; the lower half first separated by a Graefe knife as in the operation for cataract, and the upper half with the scissors. A narrow band should remain above and below, through which sutures are introduced but not tied. The lens is allowed to escape by opening the lens capsule, after which the sutures are rapidly drawn together to avoid loss of the vitreous humor. The wound in the conjunctiva is then closed by drawing upon the purse-string suture.

In a recent staphyloma with thin walls an attempt may be made to produce a flat scar by simply splitting the staphyloma. A bow-shaped incision like that for cataract is so made that the flap is formed from the wall of the staphyloma. By retraction of the flap, the wound is made to gape, which effect may be increased by excising a narrow edge from the flap. The lens is removed by rupture of the anterior capsule, and a compress and bandage applied, so that a flat cicatrix may be produced.

The incision of a staphyloma has only one advantage over enucleation, namely, that the patient is left with a freely movable stump upon which an artificial eye can be well fitted. On the other hand, the operation has the disadvantage of not guarding against sympathetic ophthalmia. It is, therefore, evident that enucleation should be preferred in all cases in which there is suspicion of sympathetic ophthalmia or in which the latter may readily develop.

CORNEAL TRANSPLANTATION.

Fuchs was the first to recommend that the fistulous or ectatic cicatrix be excised with a corneal trephine, and that the defect be covered with a piece of cornea removed by a trephine from a freshly enucleated eye. The excised portion may include the entire thickness of the cornea, *total keratoplasty*, or all but the posterior transparent layer and Descemet's membrane, *partial keratoplasty*. While the new piece of cornea inserted usually adheres well, it becomes cloudy in a short time, so that from an optical point of view the operations are worthless, and are only employed to replace a fistulous or ectatic portion of the cornea. The treatment of anterior synechia, in which the cicatrix is solid, has already been given (page 237).

Total Keratoplasty.—Local anesthesia is sufficient except in restless patients. The cutting edge of the trephine, which should project only slightly to avoid injury of the lens capsule, is pressed lightly upon the cornea over the cicatrix, and the assistant presses the button starting the trephine. After a few rotations the instrument must be raised to determine the depth of the cut, and to observe finally if the instrument has perforated. As the scars are thin, perforation often occurs with unexpected rapidity. After the aqueous humor has escaped, if the circumscribed piece is not cut through in its entire circumference, it is better, rather than re-apply the trephine, to raise the flap with forceps at its cut end and carefully separate it at the periphery with a lancet. This is not difficult, as a rather deep furrow will have been made. On the posterior wall of the excised piece may be seen adhering the remnants of the pigmented epithelium, as the excised cicatrix is nothing more than the iris which has undergone cicatricial change.

Carefully avoiding the capsule of the lens, which lies exposed in the opening, the operator then proceeds with the forceps to draw the iris out a trifle on all sides, and to excise it with de Wecker's scissors. In doing this there is the danger of producing an iridodialysis, especially if the iris is short on one side. This is most likely to occur when the iris is roughly drawn out with the forceps. It is, therefore, better to break up the adhesions with a blunt tenaculum and thus free the iris, whereupon it will usually withdraw itself from the scar, or it may be pushed away with the spatula.

The defect is then covered with a piece of cornea removed with the

same trephine from a freshly-enucleated human eye. If the lens does not protrude it is sufficient to insert the piece without further fixation, care being taken to place the side covered with epithelium externally. When the flap is placed in the proper position, the upper lid is drawn down carefully over the eye, a bandage is applied to both eyes and not removed for two days, and the patient kept in bed.

While the inserted piece usually remains fixed in position, it may be forced out into the conjunctival sac after the bandage has been applied. If the new disk shows no tendency to stay in place immediately after operation, which occurs if the lens or hyaloid protrude, it must be held in position for a few days with a conjunctival flap. The flap should be twice the width of the corneal defect, as one that is scanty tends to slip from the bulging cornea. The conjunctiva lies upon a surface completely covered with epithelium, so that there is no adhesion between the two. If the sutures have not spontaneously cut through, the conjunctiva may be loosened in a few days and returned to its normal position or excised.

It is evident that the operation for removal of an ectatic cicatrix with the trephine can only be applied to scars with a maximum diameter of 4 mm. If a large piece is trephined from the cornea, the transplanted flap will not hold, and the large opening will have to be covered later by a conjunctival flap. Therefore, for large ectatic scars there remains only the original simple method of producing a flattening of the scar by a broad iridectomy and subsequent pressure-bandage. Ectatic cicatrices should be removed by operative means, as they not only carry with them the danger of increased pressure, but also afford a portal of entry for infection of the eye.

Partial Keratoplasty.—This method has been perfected especially by von Hippel. It is suitable only for those cases in which the cicatricial clouding of the cornea that is to be replaced by a transparent piece does not include the whole thickness of the cornea. The trephine cut should never exceed 4 mm. in diameter, and is carefully cut out with the aid of forceps and a lancet applied flat, the result being that the transparent posterior layer of the cornea lies exposed in the opening. A corneal segment of the same size is then excised in its whole thickness from a suitable freshly-enucleated human eye. The defect is covered with this piece. The eyes are carefully closed and bandaged, the bandage being changed in three days. It can be entirely dispensed with in nine days. The adhesion of the transplanted piece

usually occurs promptly, but the expectation that the flap will remain transparent is almost never realized. A complete cloudiness gradually develops.

The trephine of von Hippel (Fig. 162) contains a drum at its upper end, in which a clock-work arrangement is introduced. On the

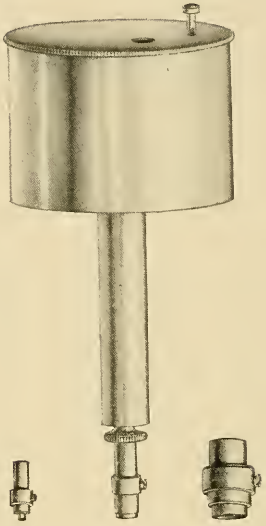

FIG. 162.—The von Hippel corneal trephine.

cover of the drum is placed a button, the pressure of which with the finger causes the crown of the trephine to be set into rapid rotation. This crown can be varied in height, thus regulating at will the depth of the incision. The trephine contains a set of crowns of varying size.

CHAPTER XV.

EXTRACTION OF FOREIGN BODIES FROM THE INTERIOR OF THE EYE.

The extraction of foreign bodies from the interior of the eye is usually a most delicate operation, particularly if attempted weeks or months after the original injury. There is no typical operative method that may guide the less skillful, and, as many of the most important structures of the eye are directly or indirectly affected in any form of operation, these may readily receive more injury than aid from the operator of limited experience.

Diagnosis.—The means of diagnosis employed in ocular injuries by a foreign body comprise external examination, the ophthalmoscope, the sideroscope, and the Roentgen rays.

External Examination.—In some cases one can recognize at first glance a perforation of the eyeball by a foreign body and determine the presence of the latter within the eye, but in others it may be difficult to find the point of entrance and to discover the foreign body itself. It frequently happens that a patient will complain of diminution in visual power without known cause and with positive denial of any injury, while the skilled eye of the physician, warned by the finding of a unilateral partial or total cataract, will examine the eye with a magnifying glass and at once discover a positive sign of previous penetrating wound in the form of a fine linear corneal cicatrix.

Often a vain search is made for the cicatrix. A fine narrow splinter with sharp edges, penetrating the sclera at the limbus or through the bulbar conjunctiva, will leave behind not the slightest trace of a visible cicatrix.

In general the presence of small wounds caused by the impact of foreign bodies usually points to the likelihood of these bodies having entered the eye; while in patients showing large wounds the injury is caused by larger pieces which rebound and do not remain in the eye. For example, if, in a recent injury of the cornea in the form of a small perforating wound, the history is obtained that a small splinter had come in contact with the eye, such circumstances will allow the presumption that there is a foreign body within the eye. If it is not

found lying in the anterior chamber, the search for a perforation of the iris, lens capsule, etc., will not be in vain. On the other hand, a larger piece, striking the eye with its fine point, might wound the cornea, iris and lens capsule and then drop away. In this case the patient's statement concerning the size of the splinter may be of importance.

The Ophthalmoscope.—If the media are sufficiently transparent to permit an ophthalmoscopic examination, the splinter may be found in the vitreous or retina. An advanced cataract may render impossible the illumination of the eye-ground and the consequent discovery of the foreign body. The lens, however, may remain transparent if the perforation has occurred through the sclera. The diagnosis is difficult, however, from dense vitreous turbidity, usually greatest around a foreign body lodged posteriorly in the eyeball, owing to the separation of the retina, which occurs frequently in such injuries. An exact and complete diagnosis, including the localization of the splinter, is most readily made when the opportunity is afforded of examining the patient immediately after the injury. Under these conditions, even if the lens is pierced, it is frequently possible, in spite of beginning lenticular turbidity, to find the splinter by means of the ophthalmoscope in the vitreous or in the retina.

The position of the foreign body does not always correspond to the direction indicated by the corneal wound and the turbidity of the lens. It frequently happens that the splinter has been deprived of its momentum through resistance of the cornea and lens, and simply falls to the bottom of the vitreous chamber. On the other hand, it may have been projected as far as the retina without penetrating the latter, and may have sunk downward from the point of impact. It is, therefore, always advisable to examine first the fundus, especially in the direction of the corneal and lenticular wounds. Here there may be discovered a wound in the retina and choroid, appearing as a glistening, white spot (the exposed sclera), which may even assume the form of the foreign body; or there may at least be seen a hemorrhage corresponding to the point of impact.

In most cases the foreign body is a splinter of metal, which is rendered conspicuous by its metallic luster, as its outer surface reflects light strongly. In recent cases, air-bubbles may not infrequently be seen in the vitreous or around the foreign body. If a dense opacity of the vitreous lies in front of the foreign body, the position of the latter is betrayed by a conspicuous whitish luster.

The Sideroscope.—In the presence of iron or steel splinters within the eye, the sideroscope renders valuable assistance. It not only indicates the presence of small particles, but at the same time allows an incidental localization, manifested by a marked deviation of the magnetic needle upon approaching the position of the fragment.

A negative result from the examination with the sideroscope is not always to be accepted as a certainty that no steel is in the eyeball or orbit; a slight deviation may frequently have no significance, especially in large cities, where the magnetic needle is always in a state of unrest. Nor does a marked deviation of the magnetic needle always indicate that the splinter is within the eyeball. We have recently seen an illustrative case in which a patient declared that he had been wounded by a splinter while hammering on iron two months previously. The splinter penetrated the lower lid about 8 mm. below the margin. The wound bled slightly, and it was only after the lapse of some time that the patient noticed a gradual diminution in the visual power of this eye, without having experienced any inflammation. When seen for the first time, there was found a delicate scar in the skin of the lower lid about 3 mm. in length. No cicatrix could be found on the eye by the minutest examination, but the vision was about one-fourth normal. By means of the ophthalmoscope, floating vitreous opacities could be seen, which were fixed below and moved about freely in the upper part of the eyeball. Upon looking downward, the red reflex was lost entirely on account of increasing density of the opacities. As the visual field was much limited in its upper part, a separation of the retina in the lower part of the eye seemed probable. The splinter could not be seen. The patient was placed in front of the sideroscope, and the needle showed a marked deviation. This occurred with almost the same intensity in all positions of the eyeball, but was greatest when the eye was directed upward. With the large magnet even the strongest currents did not draw out the splinter, and the patient did not have the slightest pain. This was more remarkable, since the presence of a large splinter had been assumed from the size of the palpebral cicatrix and the deviation of the sideroscope. However, examination with the Roentgen rays showed that a splinter, 5 mm. long, was lodged in the orbit outside of the eyeball. In its course through the orbit the splinter either had perforated the sclera twice, or had slit up the envelope of the eyeball below, and had thus produced the intraocular changes.

Roentgen Rays.—The Roentgen rays are the most positive means

of diagnosis, and not only indicate the presence of the foreign body, but accurately *locate its size and position* in the eyeball or the orbit. Only in rare instances, in which the shadow cast by a minute body is lost in the shadow of the bones of the skull, will the Roentgen rays fail to give a positive diagnosis. The rays are applicable to injuries from metal of all kinds, shot, glass, or stone.

Magnetic Foreign Bodies.—The majority of foreign body injuries are inflicted with iron or steel, and extraction by the magnet is usually successful in recent cases. Of the various magnets, the Haab is the most powerful, but numerous other forms are employed.

The Giant Magnet.—The Haab magnet is now made in bell form, with the working point in the shape of a cone of 90 degrees, so that the operator has a clear view of the field of operation. Four tips of different shapes are supplied. The magnet is mounted on a hollow cast-iron pillar, with a shelf to support the arms of the patient and keep the head steady, while at the base is a foot pedal for closing the circuit.

Small Hand Magnets.—The original small Hirschberg magnet, operated by battery, has been generally superseded by larger and more powerful hand magnets. The newer-type hand magnets weigh from eight to twelve pounds, are operated like the Haab instrument on the general lighting circuit, and are extremely powerful. Points of different sizes and shapes are used. Owing to the difficulty of manipulating the Haab magnet in extracting the body after it has been drawn into the anterior chamber, the operator should be supplied with one of the small hand magnets.

Foreign Bodies in the Vitreous Chamber.—The method chiefly employed in our clinic in extraction of iron or steel from the vitreous chamber is to draw the splinter into the anterior chamber with the giant magnet, and then extract it through a corneal incision with a small magnet. There are two means at our command to lessen the attractive power of the large magnet on the eye, either by employing a weak current so that the iron core is given but slight magnetic pull, or by keeping the eye at some distance from the pole of the magnet. The object is to use the least possible magnetic force necessary to draw the splinter gently around the edge of the lens, first behind the iris and then through the pupil into the anterior chamber.

Drawing the Body into the Anterior Chamber.—After the position of the splinter has been determined, it is not difficult to rotate the eye into the proper position for the application of the magnet.

For example, if the splinter lies in the lower part of the vitreous chamber, the eye will be directed downward upon approaching the magnet, so that the latter is brought approximately opposite the center of the cornea. In recent injuries the foreign body will soon be attracted by the magnet, and will appear behind the iris, causing a protrusion of the latter, but in injuries of longer duration, it may take some time before the splinter yields to the traction of the magnet. If it is seen that the extraction cannot be accomplished with mild currents, the strength of the latter is gradually increased. Should the patient experience pain even with a mild current this is an indication that the splinter is perhaps in contact with the ciliary body, and greater care must then be taken in the operation. If the foreign body has become firmly lodged in the posterior part of the eye-ground by means of inflammatory bands, even the large magnet may not be sufficient to dislodge it, especially if the splinter is very small. It may then be necessary to subject the patient to the magnet repeatedly, and each time for a longer period, before we succeed in drawing the splinter gradually from its bed. Failure of the magnet to extract the foreign body after numerous trials usually compels enucleation of the eyeball.

Extraction of the Body from the Anterior Chamber.—After the splinter has been drawn into the anterior chamber, it may fall upon the iris or at the bottom of the chamber, or the magnet may have pulled it to the posterior wall of the cornea, where it remains hanging. To remove the splinter an incision is made with the lancet, usually below, and of sufficient size so that an instrument, such as forceps or the tip of a small magnet, may readily be introduced without compressing the iris or cornea. It is best to attempt to combine the incision and the extraction of the foreign body in one act. The assistant by means of the small Hirschberg magnet holds the splinter against the center of the posterior corneal wall, while the operator introduces the lancet. At the moment when the operator begins to withdraw the lancet from the eye, the assistant moves the magnet downward along the outer surface of the cornea, so that the splinter makes its exit from the wound along the outer surface of the lancet simultaneously with the latter.

Unfortunately, the result with our small magnet is often unsatisfactory. It is not sufficiently strong to exert its magnetic power through the cornea and to direct the splinter at will. If the attempt just

described is not successful, the splinter may be drawn out of the anterior chamber through the wound by means of the magnet. The tip of the magnet is introduced through the wound into the anterior chamber and brought close to the foreign body, so that the force is sufficient to attract the splinter. As the various terminals of the magnet are relatively thick, it is less injurious to grasp the foreign body directly with a pair of forceps and thus withdraw it. Occasionally the splinter can be removed with the aid of Daviel's curet. This instrument is introduced behind the foreign body, presses it against the posterior corneal wall, and renders its extraction easy along the channel formed by the curet. In all these procedures care must be taken not to allow the splinter to disappear behind the iris, either by falling downward or by being pushed upward behind the pupil by the use of an instrument. In order to bring again to view the foreign body, recourse must usually be had to the large magnet, especially if a minute splinter has disappeared below into the bottom of the chamber. The iris is to be excised only if severely injured by the accident, or, as rarely occurs, it has been badly contused during the operation. If the foreign body has perforated the lens and the wound in the capsule becomes closed by the iris, the opacity in the lens may remain slight and stationary. In this case that part of the iris which covers the wound in the capsule should be carefully avoided during the operation.

In all recent injuries, whether the splinter is of iron or of other material, immediate operation should be undertaken. It is otherwise, however, with old injuries. We know that splinters of iron are not well borne, but cause a gradual disintegration of the eye through an insidious inflammation and siderosis. As extraction with the magnet is often successful even in these old cases, the operation is always to be performed, especially when there are already signs of a deleterious influence exerted by the foreign body.

Extraction through the Sclera.—Removal of a foreign body from the vitreous through the anterior chamber is contraindicated only if the foreign body has penetrated the sclera behind the lens, so that the latter has remained completely transparent. In this case the splinter is withdrawn directly through the original wound by means of the large magnet, applied as described. If necessary, the wound can be enlarged to a sufficient size. Only by gross carelessness on the part of the operator will parts of the choroid and retina be withdrawn with the foreign body. If the magnet is made sufficiently weak, the splinter

can slowly be brought into the wound whence it may be readily extracted.

Some operators believe that extraction through an opening in the sclera, preferably between the external and inferior rectus muscles, with the magnet-point between the lips of the wound, but not entered into the vitreous, is a safer procedure than removal of the foreign body around the lens into the anterior chamber. This is the method largely followed in America, the position of the metal being accurately determined by means of the Roentgen rays before operation.

Prognosis.—Foreign bodies situated in the anterior chamber, iris, or lens give a better prognosis than when the body has passed into the vitreous chamber. The smaller the body the less damage to the ocular structures. Large splinters render the prognosis bad, because of the immediate injury to important parts of the eye, and the subsequent inflammation that occurs. Prognosis depends largely upon the promptness with which the body is removed. If a long period has elapsed since the injury, the body may become covered with exudate, and, even though extraction may have been performed smoothly, separation of the retina or chronic iridocyclitis may follow, usually necessitating enucleation of the eye.

Non-Magnetic Foreign Bodies.—Penetrating wounds of the eyeball are often made by particles of copper from exploding percussion caps, pieces of wood and stone, and bird shot. Before the introduction of the Roentgen rays, the lodgment of a non-magnetic foreign body in the posterior section of the eyeball made immediate enucleation imperative. The employment of the rays has effected a great change in the treatment of these cases, and has made it possible to save many eyes that were formerly regarded as lost. Without a previous examination with the Roengten rays, no operation should be undertaken in any case where there is suspicion of an intraocular foreign body, with perhaps the exception of an iron splinter. This examination gives accurate information concerning the size and position of the foreign body.

Bodies in the Posterior Segment of the Eye.—The extraction of non-magnetic foreign bodies from the vitreous chamber is a complicated procedure, even after accurate localization by the Roentgen rays. Quite frequently substances like copper and grains of shot fall to the bottom of the chamber, where they often become fixed by exudate. They can most readily be recovered, if they lie to the temporal side and

below. The operative procedure is as follows: After dissecting up a flap of conjunctiva and uncovering the sclera, a meridional opening, at least 6 to 8 mm. long, is made in the neighborhood of the foreign body, the cut extending through the sclera into the vitreous. With double tenacula the assistant raises and separates the edges of the wound, in order to facilitate an examination of the interior of the eye. During this procedure the loss of vitreous can readily be avoided. It is best to have the patient in a condition of profound anesthesia.

If the incision corresponds with the position of the foreign body, the latter will appear in the wound and can be removed with forceps. But if it has not appeared in the wound, the attempt to find it in the vitreous chamber is usually hopeless. The immediate neighborhood of the wound must be carefully explored with the iris-forceps, in the hope of locating the foreign body. Occasionally, the use of Sachs' lamp will be of material assistance in the operation. If the lamp is placed by an assistant laterally against the cornea, without exerting pressure on the eye, the open incision and the whole vitreous space is illuminated and transparent, so that in fortunate cases the foreign body is recognized as a dark structure, and can be grasped and withdrawn with the forceps. After the extraction a suture may be entered through the superficial layers of the sclera if the wound gapes, but usually the stitching of the conjunctival flap over the incision will be sufficient. The patient should be kept in bed for several days. The prognosis even in successful cases is bad on account of detachment of the retina.

In injuries that are not recent the difficulties of extraction are greater. Of the different foreign bodies that enter the eye copper splinters are least well borne, and the attempt to remove them should be made in every case. But if a foreign body is securely lodged without signs of irritation or inflammation, the operation should be avoided on account of its unfavorable prognosis, and only undertaken if threatening phenomena arise.

Failure to Extract Body.—If the extraction of the foreign body has not been accomplished, it is best to proceed at once to the enucleation. The consent of the patient to this operation should be obtained beforehand, telling him that the other procedure is merely an attempt to save the eye through search for and extraction of the foreign body. Non-magnetic foreign bodies situated in the neighborhood of the macula give no hope of extraction with preservation of the eye.

Bodies in the Anterior Segment of the Eye.—Non-magnetic bodies that lodge in the anterior section of the eye, may in exceptional cases be extracted through the original wound in the cornea, after its enlargement by means of scissors. Only peripheral wounds, however, are suitable for this procedure. Wounds near the center of the cornea if similarly treated would later produce still greater disturbance of vision through the larger cicatrix resulting from the incision, and it is, therefore, the best procedure to make a lancet incision elsewhere of sufficient size to permit the introduction of forceps. This incision may be difficult if the wound produced by the foreign body has not yet closed, permitting escape of the aqueous and shallowing of the anterior chamber. But even then a correct incision can be made between the cornea and the iris without wounding the latter, especially if a Graefe knife is used and is slowly introduced between both membranes. If the splinter in the anterior chamber is large and warped, care must be taken during its withdrawal not to wound the iris or capsule of the lens. The incision into the anterior chamber is made below or externally, from which directions instruments can be most readily introduced into the eye.

CHAPTER XVI.

MINOR OPHTHALMIC OPERATIONS.

SUBCONJUNCTIVAL INJECTIONS—PTERYGIUM—OPERATIVE TREATMENT OF TRACHOMA—RETINAL DETACHMENT—THE OPHTHALMIC ASSISTANT—ANESTHESIA.

Everting the Upper Lid with Groenholm Spoon.—This instrument (Fig. 163), modelled after the Desmarres elevator, permits eversion and fixation of the upper lid with one hand, and exposure of the upper conjunctival fold.

The patient is directed to look downward, the lashes are grasped

Fig. 163.—Groenholm spoon.

between the thumb and forefinger, and the convex rim and surface of the spoon is applied to the skin of the lid back of the upper border of the tarsus (Fig. 164). The spoon is pressed backward as the lid

Fig. 164.—Spoon applied to the surface of the lid.

is everted over its convex rim. The handle of the spoon is now turned toward the forehead, and the lid stretched over the spoon, the rim of which firmly holds it in place. The entire surface of the tarsus as well as the fornix (Fig. 165) is exposed and spread upon the spoon. The spoons are of various shapes and sizes to be adaptable to all lids.

The rim of the spoon should be straight and not sharp, and its surface only slightly curved. If the lid should slide off the spoon, it may be still held in place with the thumb, while the middle and index fingers support the spoon handle.

The employment of the spoon permits the surgeon to have one hand free for operation, exposes the conjunctival fold, and smoothes out all recesses, so that treatment may be readily made.

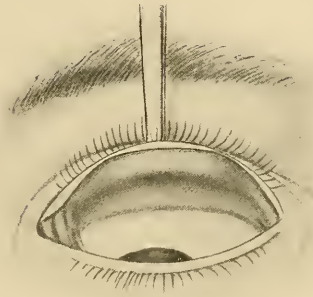

Fig. 165.—Lid everted over the spoon.

Detachment of the Retina.—The operation of puncture of the subretinal space in the treatment of retinal detachment does not differ materially from posterior sclerotomy performed for glaucoma. After the knife has punctured the sclera, and the blade turned transversely to the cut, pressure is made on the globe to evacuate the subretinal fluid. The operation must often be repeated, and, according to Deutschmann, may be combined with perforation of the retina itself. Good results are unfortunately not to be expected. Subconjunctival injections of salt-solution in Tenon's capsule are also employed.

SUBCONJUNCTIVAL INJECTIONS.

Subconjunctival injections of salt-solution or weak solutions of bichlorid of mercury or cyanid of mercury are employed in both external and internal ocular affections.

Injections of Salt-Solution.—These are indicated in (1) Cloudiness of the vitreous, whether of inflammatory nature or produced by hemorrhages. The more recent the affection, the more favorable their influence. (2) In retinal detachment. The result is only transitory. (3) In choroiditis, especially in myopic eyes, and in hemorrhages in the retina. (4) In deep keratitis, to promote absorption of

the corneal infiltration. Old corneal cloudiness is little influenced by the injections.

Injections of Solutions of Mercury.—These are employed in (1) rapidly progressive corneal infiltration and ulceration, especially scrofulous ulcers, infected corneal wounds, and incipient serpiginous ulcers; (2) commencing infections of the interior of the eye, either after injury or following operation.

The Method of Injection.—After local anesthesia with a 3 per cent. solution of cocain, the lower lid is drawn away from the globe with one hand, while the other hand, holding the syringe horizontally and nearly parallel with the surface of the sclera, enters the needle beneath the conjunctiva, midway between the limbus and the lower conjunctival fold. If the fluid is injected close to the limbus, the violent detachment of the closely adherent conjunctiva causes severe pain and occasionally stippling of the corneal epithelium from circulatory disturbances. The injection may be made at any point around the globe, and the desired quantity of solution slowly introduced. The patients complain of slight discomfort after the injection, but intense pain of long duration is rare. Adrenalin may be dropped in the conjunctival sac prior to the stronger injections.

The injection fluid consists of a 10 per cent. solution of common salt, a 1–1000. solution of bichlorid of mercury, or 1–5000 solution of cyanid of mercury. A 1 per cent. solution of cocain is added, with or without adrenalin. The quantity of the salt-solution injected equals the entire contents of a Pravaz syringe (1 c.c.). Immediately following the injection, a large conjunctival bleb forms, which is distributed by slight massage. No more than $\frac{1}{10}$ or $\frac{2}{10}$ c.c. of the mercury solutions should be injected, otherwise necrosis of the tissues and vessels would ensue, with possible corneal complications. The effect of small injections is to cause a moderate irritation of the conjunctiva, with more active exchange of fluids between the cornea and its adjacent tissues. Their value therefore depends more upon increased tissue metamorphosis than the antiseptic influence of the minimal quantity of the mercury injected. The injection is repeated after the chemosis has subsided and the disease shows no signs of distinct improvement. The second entrance of the needle should be some distance from the first, even though the corneal disease is much farther removed. As many as four or five injections may be given if the disease has been favorably influenced.

The injections are often useful in scrofulous ulcerations of the cornea, but frequently fail in serpent ulcer, particularly if the ulcer has passed the incipient stage.

No complications occur from properly given injections, although the injury of a large conjunctival vessel may cause a subconjunctival hemorrhage. Deep injection of salt-solution in Tenon's capsule, a procedure employed in the treatment of retinal detachment, may cause transitory diplopia with slight exophthalmos.

OPERATIVE TREATMENT OF PTERYGIUM.

Operations for pterygium consist of inversion, excision or transplantation. Cauterization of the apex of the growth and the operation of ligation are inferior methods of treatment, and have few advocates. Local anesthesia is used in all cases.

Inversion.—This is a simple and at the same time a most reliable method. After well cocainizing the eye, the lids are opened with a spring-speculum, and the patient is told to look toward the side opposite to the pterygium. The operator grasps the neck of the pterygium with toothed forceps, stretches it somewhat, and applies a lancet flat against the cornea completely separating the head (*a*, Fig. 166) from the corneal tissue, with which it is firmly united. This peeling off must be done carefully and thoroughly. When the head is once free, the remaining loosely connected portion of the growth is separated as far as the border of the cornea and for a short distance on the sclera. The margins of the pterygium at the apex of the loosened conjunctiva are excised with the scissors, and the pterygium with its apex (*a*) turned inward so that its raw surface is directed forward and its two borders (*ab*, *ac*) diverge toward the cornea (Fig. 167). By two or three suitable sutures the borders are now united, taking care that no open wound remains at the limbus. The first suture is therefore introduced vertically in the neighborhood of the limbus, including with the needle a few superficial fibers of the sclera between the two edges. A projection is formed on the conjunctiva by the transplanted pterygium, which in a short time completely disappears.

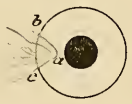

FIG. 166.—Inversion of the pterygium.

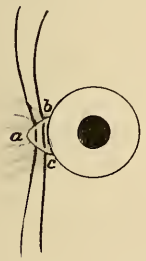

FIG. 167.—Inversion of the pterygium. Sutures in position.

Excision (Arlt).—This method is also used frequently. The pterygium is held with toothed forceps at its neck, where it can be slightly lifted from the underlying part. The separation is the same as previously described. While none of the advancing head should be left on the cornea, no normal corneal layers should be removed, as this would produce a more extensive scar. After separation of the pterygium, two convergent incisions (*c b*, *b d*) are made in its body (Fig. 168). A rhomboidal piece is thus excised, consisting of the head and part of the body. The conjunctival opening is closed by two sutures which are introduced in a vertical position. Unless the wound is entirely covered by the conjunctiva, the growth will be drawn on to the cornea by cicatricial tissue. The wound in the cornea heals by cicatrization and leaves a permanent opacity.

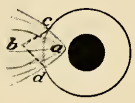

FIG. 168.—Arlt's method of operation for pterygium.

Transplantation (McReynolds).—This is a modification of the Desmarres operation. The separation of the pterygium from the cornea is performed in the manner previously described. While the fixation forceps still hold the neck of the growth, a slender, straight pair of scissors divides the conjunctival and subconjunctival tissue along the lower margin *only* of the pterygium, commencing at its neck and extending toward the canthus, a distance of $\frac{1}{4}$ to $\frac{1}{2}$ inch. The body of the growth is now separated from the sclera with the

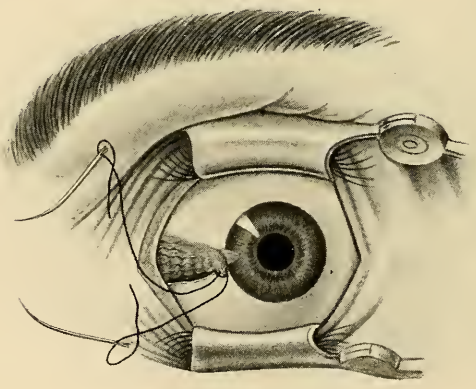

FIG. 169.—Transplantation. An incision has been made along the lower border of the pterygium, and the needles passed through the head of the growth.

blunt points of the closed scissors, and the conjunctiva below the oblique incision undermined well into the lower culdesac with a few cuts of the scissors. Small curved needles, double-armed with black silk, are passed through the apex of the pterygium from without inward and separated from each other by a sufficient amount of the tissue to secure a firm hold (Fig. 169). These needles are carried downward through the lower conjunctival incision, and emerge in the lower fornix about $\frac{1}{4}$ inch from each other. The forceps now lift the loosened lower segment of conjunctiva, and with traction upon the free ends of the thread the pterygium glides beneath the loosened conjunctiva (Fig. 170). The threads are then tied and cut off.

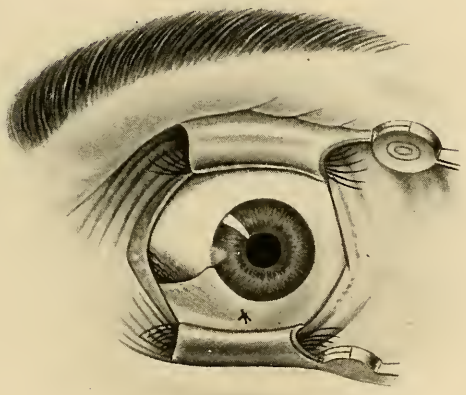

Fig. 170.—Transplantation. The pterygium has been drawn down beneath the conjunctiva in the lower culdesac, and the conjunctiva attached to the upper border covers the former site of the growth.

It is important that the upper border of the pterygium should not be incised, otherwise there will be a denuded space after the growth has been drawn into the inferior fornix. If the growth is not separated at its upper portion from the conjunctiva, the elasticity of the latter is such that when the downward traction is exerted the membrane thins out and is smoothly applied to the sclera over the former site of the body of the pterygium, and the margin of the conjunctiva corresponds accurately to the corneo-scleral junction. Since the sclera is then covered by non-vascular conjunctiva, there is no tendency to the formation of new blood-vessels, with thickening of the tissue and return of the growth. In a short time the corneal wound heals and the thin

conjunctival tissue becomes adherent to the sclera. In two days the stitch is to be removed, and the pterygium will be found firmly adherent to the sclera and hidden by the loosened lower segment of the conjunctiva. If the head of the pterygium is large, it should be cut off before the growth is drawn down into the conjunctival pocket.

OPERATIVE TREATMENT OF TRACHOMA.

The surgical treatment of trachoma comprises (1) the removal of the granulations by expression with the Knapp roller-forceps or the Kuhnt expressor; (2) curetment or scarification of the granules, followed by rubbing with strong solutions of bichlorid of mercury (Grattage); (3) excision of the upper transitional fold; and (4) excision of the tarsus.

Expression.—This operation is performed with the Knapp roller-forceps or the Kuhnt expressor. Anesthesia is secured by several instillations of a 3 per cent. solution of cocain, followed by a subconjunctival injection of a 1 per cent. solution beneath that part of the conjunctiva where expression is to be commenced. The upper lid is everted, so as to gain access to the conjunctival fold. Before the forceps are applied, the conjunctiva over the granules is superficially scarified to permit their contents to be easily expressed.

Knapp's Roller-forceps.—One end of the roller-forceps (Fig. 171) is introduced between the conjunctiva of the eyeball and the lid, and



Fig. 171.—Knapp's roller-forceps.

the other placed upon the everted surface of the tarsus. The two arms of the forceps are pressed together forcibly, and drawn slowly along the conjunctiva, and the granular material squeezed out as the ridged rollers pass over the fold of the membrane between the two blades. The traction should not be made forcibly, or lacerations of the conjunctiva with fresh scar-formation will be produced. The more carefully the operation is done, the less painful will it be and the less injurious to the conjunctiva. The considerable bleeding which follows is combated by active sponging with a weak bichlorid solution.

In a similar manner the lower lid is freed of its granulations. With the Knapp roller it is more difficult to strip the semilunar fold, and especially to squeeze out isolated granulations, without including and compressing the surrounding conjunctiva. For these cases it is best to employ simply small forceps, the narrow branches of which can readily grasp and express isolated granulations. If a group of granulations is found on a sharply circumscribed area of the upper fold or elsewhere, it may be excised, together with the underlying conjunctiva. In order to extract the granulations from the tarsal conjunctiva, the tarsus itself must be seized between the branches of the roller-forceps.

Kuhnt's Expressor.—This forceps-like instrument (Fig. 172) ends in two plates, the perforations in which are not opposite to each other



Fig. 172.—Kuhnt's expressor.

when the two plates come together. Its advantage lies in the avoidance of lacerations of the conjunctiva which occasionally follow the use of the roller-forceps. The instrument expresses the granulations without traction, and is especially recommended by Kuhnt for advanced, felty trachoma, in which the conjunctiva of the transitional fold is easily lacerated and wounded by rolling, followed by a marked contraction of the conjunctival sac. With the Kuhnt expressor this is avoided, as the granulations are pressed out of their beds like comedones.

After-treatment.—Immediately after operation, cold compresses are to be constantly applied for several hours. Each day the lids are everted, and the grayish exudate wiped off, and, as soon as the swelling has subsided, applications of a 2 per cent. nitrate of silver solution are resumed.

Grattage.—Deep scarifications of the trachomatous tissue, with subsequent vigorous scrubbing of the conjunctiva with the ordinary tooth brush and bichlorid solution, are recommended and followed by some operators. Severe measures of this character are not followed in

our clinic, as they are likely to result in destruction of normal structures and are particularly liable to the formation of adhesions of the retro-tarsal folds.

Excision of the Upper Transitional Fold (Kuhnt).—If the trachomatous infiltration is restricted to the upper transitional fold, and the disease has failed to be relieved by medicinal treatment, excision may be made as suggested by Kuhnt. Cocain is applied locally and by injection, the lid is everted over a spoon, and the patient directed to look downward, so that the transitional fold is spread out. The thickened and granular fold is sharply defined from the normal conjunctiva, and incision is made in the healthy region in the entire length of the conjunctiva and from within outward. The bulbar conjunctiva retracts and the incision gapes, and becomes somewhat undermined. Sutures are at once inserted close to the incision of the conjunctiva. The second incision is carried along the margin of the affected part near the upper tarsal border. The circumscribed area is then carefully dissected out with scissors without injuring Mueller's muscle, which lies immediately beneath. The threads are now carried over the corresponding points of the tarsus. In a few days the wound heals.

Extirpation of the Tarsus.—This operation is indicated, according to Kuhnt, in marked cicatrization of the conjunctiva with thickened and curved tarsus, and especially in obstinate pannus; in entropion with trichiasis; and in ptosis due to trachoma. After the lid is everted, the margin is seized with strong hook forceps, and a horn plate is inserted beneath the skin surface of the lid, putting the cartilage on the stretch. Incision is made parallel to and $2\frac{1}{2}$ mm. from the lid-margin, without injuring the pretarsal conjunctiva or the orbicularis muscle, and the conjunctiva dissected loose from the tarsus. As in this stage of trachoma the normal connection between the conjunctiva and tarsus no longer exists, the conjunctiva immediately retracts and the tarsus is separated in its anterior surface from the pretarsal connective-tissue as far as its upper margin. If the sharp edge of the knife is directed toward the cartilage, there is no danger of cutting through the conjunctiva. Kuhnt separates the entire tarsus from the levator tendon, but we follow the suggestion of Lyritza and allow a small strip of the tarsus to remain in order to exclude the possibility of ptosis. The wound is sutured with fine silk threads, although this is not absolutely necessary. If the conjunctiva is greatly shrunken, trans-

plantation of mucous membrane from the lip to the surface of the wound is of value.

This operation not only relieves entropion and trichiasis, but exerts an excellent influence upon pannus. In order to prevent the ptosis double-armed needles should be carried through the conjunctiva and levator tendon and passed down along the anterior surface of the remaining tarsal margin and brought out through the skin above the cilia and knotted over a bead.

THE OPHTHALMIC ASSISTANT.

In order to obtain free access to the eye with the instruments during operations, the lids must be adequately opened. In those operations in which the eyeball is not cut into or is incised only to a slight extent, we employ the spring-speculum. It is therefore used in the operation for strabismus, pterygium, discissions, puncture of the anterior chamber, etc. On the other hand, we dispense with the use of the speculum in iridectomy for glaucoma and in cataract operations. Even those operators who regularly use the lid speculum designate it as "an instrument dangerous to the eye, but indispensable" (Terrien). The first attribute is correct, but not the second. The lid speculum will cause no injury to the patient who is quiet and who does not twitch, especially if the assistant holds it carefully in his hand and directs it so that there is no pressure exerted on the eye. In any case, the lid speculum often becomes a great hindrance; indeed, with a small palpebral fissure it may render impossible, for example, an upward incision. The injury produced by introduction of the lid speculum may even amount to a catastrophe if the patient strains, the wound begins to gape, and the vitreous humor presents itself. In addition, it may then become difficult to free the lids from the instrument. In Mueller's lid speculum, the branches are turned around by closure of the speculum so that the lids free themselves. If the operator can command the services of even a half-trained assistant, this is certainly to be preferred to the lid speculum.

The work of the assistant consists in separating the lids and holding the palpebral fissure open only during the short periods that the operator works on the eye. In the intervals, while the instruments are being changed, the eye washed out, etc., the lids are released so that they cover the eye.

In opening the palpebral fissure (see page 137), the assistant applies

the thumb of the right hand to the edge of the upper lid, raises it and draws the lower lid down with a finger of the left hand laid on its edge. The upper lid is at the same time somewhat drawn away from the globe, so that its border does not enter the wound if the eye should be suddenly rotated upward or if the lid should suddenly slip. The lower lid should be drawn downward in such manner that it does not roll outward. The extent of separation of the lids depends upon the operative procedure to be undertaken.

The Assistant During Cataract Operation.—The work of the assistant during the extraction of cataract is detailed as follows:

The Incision.—The palpebral fissure is held open as above described, and, after the operator has completed the incision, the assistant

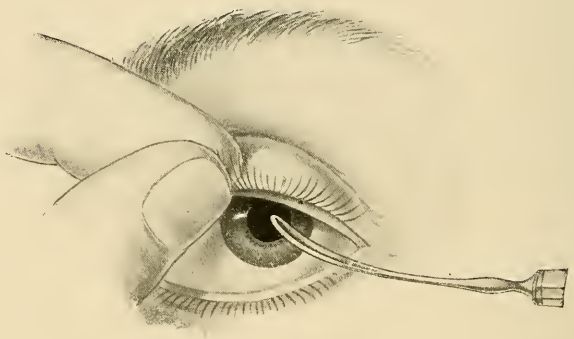

FIG. 173.—Assistance. The operator grasps the upper lid by its cilia, draws it slightly away from the eyeball, and guides it downward over the wound, while the spoon is inserted under the lid to keep it away from the surface of the globe.

draws the external canthus somewhat downward, and allows the upper lid to slide down at a slight distance from the cornea, so that the wound does not gape. The lower lid must not be released until the upper lid covers the wound.

The Iridectomy.—The palpebral fissure is opened as before, and the assistant need only see that the finger which holds the upper lid is not placed in the way of the operator. (See Fig. 90, page 143.) As the operator must introduce the forceps into the wound from above, the assistant places his finger on the lid either on the nasal or temporal side.

Opening the Capsule.—The operator raises the upper lid with his left hand. The assistant holds the lower lid with one hand, and at the same time takes a Daviel spoon in the other hand, which is held

against the border of the upper lid. If the lid should slip through the fault of the operator or from the twitching of the patient, it will fall upon the spoon, and will thus slide over the wound without turning the latter back. At the critical moment the operator can help himself without much chance of failure, by slipping the rapidly closed capsule forceps under the upper lid and thus drawing it down. Fig. 173 shows how the operator himself may draw down the lid by its cilia, while the spoon in the assistant's hand is ready to slip under the lid and hold it away from the eye.

Control of the lower lid always requires great care. Even though the patient twitches but slightly, the lower lid should never remain without fixation after the upper lid is raised. If the lower lid is left free, and the patient makes it tense through innervation of the palpebral muscle, the lid will be pressed against the globe and will cause the wound to gape and open. It is possible for the vitreous humor to be expressed in this way.

If the operator contemplates removing the lens in its capsule, on account of thickening of the latter, he should allow the assistant to hold both lids, so that he himself may take in his left hand the spatula with which the scleral edge of the wound is somewhat depressed to favor the escape of the lens.

Expression of the Cataract.—The operator, while raising the upper lid with either hand, performs with the lower lid the massage-movements that have been described for expressing the lens. The assistant holds the Daviel spoon, prepared to introduce it under the upper lid, if necessary, and to extract the lens when it protrudes to the extent of one-half. In performing this latter act, the spoon is placed against the equator of the lens and thus lifts it out.

Reposition of the Iris.—The operator raises the upper lid and the assistant holds the lower. If the patient is quiet and does not twitch the lids the assistant's task is an easy one. Of course, the assistant must never press the lids against the eye. In protruding eyes the opening of the lids requires special care. The lids must not be pushed far backward, but must be opened merely enough for the requirements of the operator. The work of the assistant is much more difficult in the case of a patient who strains. But it is just in such cases that the value of a good assistant is fully appreciated. Skilful separation of the lids in the correct manner and at the right time often prevents the otherwise certain prolapse of the vitreous.

During Complications.—In unruly patients it may be quite impossible to proceed in the manner described. The upper lid must then be elevated by inserting a Desmarres elevator. All pressure on the eye, however, must be carefully avoided. This elevator is permitted to remain in place during the whole operation, while the lower lid must also be fixed at the same time, for reasons that have been mentioned. The only disadvantage of the elevator is that it stands in the way of instruments that are to be introduced from above. The spring-speculum, however, must never be used in restless patients.

If a prolapse of the vitreous occurs, the lids must not be aimlessly released, as is often done by frightened assistants. On the contrary, the upper lid still firmly held must be cautiously lowered over the gaping wound, while the operator inserts under the lid for its guidance the instrument which he happens to have in his hand. This may be a closed pair of de Wecker scissors, the capsule forceps, the spatula, the spoon, or even the handle of the Graefe knife. The lower lid may be released by the assistant only after the upper lid has covered the wound, otherwise the patient will raise the flap still further with his lower lid, and will thus express the vitreous. In patients who are known beforehand to be restless and likely to twitch, the opening of the lids may be materially facilitated by performing an extensive canthotomy immediately before the operation.

Fixation of the Eyeball.—Occasionally the assistant must hold the eye with fixation forceps. As repeatedly stated, fixation is only employed in cataract operation while the incision is being made. In non-congested and well-cocainized eyes, iridectomy is usually accompanied by so little pain that the patients are perfectly quiet during its performance. After opening the eyeball by a long incision, the use of fixation forceps, even with the greatest care, causes a gaping of the wound. The fixation forceps should only be employed when absolutely necessary. Especially in the cataract operation their use can only be forced by unreasonable patients. In such cases the assistant applies the forceps to the limbus exactly at the lower edge of the cornea, and draws the eye slightly down. The forceps also keep the lower lid away from the globe. The iridectomy may under these circumstances become difficult.

If the upper lid is held up by the Daviel spoon, the eyeball must be carefully drawn downward a little with the forceps; otherwise, it may be impossible in the small space to draw out the iris with the forceps.

On the other hand, it may be easier to slip into the anterior chamber from the side with a properly bent, blunt tenaculum, and thus draw out and excise a fold of iris from the pupillary border. Likewise the opening of the anterior lens capsule must then be performed with a sharp tenaculum that has been bent in the required direction.

In certain cases the eye must be held with the forceps in order that operation may be safely done, and this course is followed regularly in excision of a prolapsed iris in an inflamed eye. During reposition of the iris it may be necessary to draw the eye downward with the forceps, because the patient will not voluntarily look in the desired direction. In this case it is best for the operator himself to hold the eye in the required position.

As already mentioned, the eye must be fixed in all procedures with cutting or puncturing instruments, as, during the cataract incision, during discission, etc. Occasionally an exception can be made in very quiet patients who will turn their eyes as required. For example, if the conjunctiva tears away during the incision, and the patient looks in the right direction, there is no objection to completing the incision without further fixation. Discission, the incision in a linear extraction, or a puncture may exceptionally be performed without fixation.

Position of the Operator's Fingers.—The support of the operator's hand must always be at a safe point. The fourth finger of the hand therefore usually rests in a suitable position on the head of the patient. In incisions from the external side the operator's hand is supported on the temple or malar bone. In incisions from below, the hand is supported on the cheek; and in incisions from above, on the forehead. The operator is not then taken unaware by an unexpected movement of the patient's head. The incision directed downward is the more readily accomplished because every patient shows a tendency to avoid the instrument by an upward movement of the eye, and it is usually much easier to look upward than downward.

It was formerly repeatedly recommended to perform all ophthalmic operations, including cataract extraction, by the inferior incision, and in fact, special methods were devised for this purpose, but, as iridectomy must be performed in most cases, operators soon adhered to the upward cut. In fact, in the establishment of a broad coloboma for glaucoma, it is of importance that the coloboma be covered by the upper lid. The lower operations are therefore limited to those cases

in which it is known beforehand that a coloboma will not be necessary, such as puncture of the cornea, linear extraction and similar operations. There are, however, certain cases which are especially suit for the inferior operation. In cataract patients an accompany ptosis may cause the pupillary region to be covered by the upper lid, an amyotrophic ptosis being not uncommon in old persons. This is an indication for the inferior operation, with a narrow coloboma which avoids the periphery of the iris.

Auxiliary minor assistance may be serviceable during an operation. It is the duty of the assistant to remove the blood from the conjunctival sac by sponging. The sponges consist of small pledgets of cotton, which are kept in sterilized physiologic saline solution, and are well squeezed out and one end is formed into a point. This end is inserted into the internal angle of the eye so that it absorbs the blood from the point outward; or the end may be drawn from the internal angle outward along the inferior transitional fold, taking the blood with it. Direct sponging of the operation wound in the eye is to be avoided as much as possible. With marked hemorrhage into the anterior chamber it will serve the purpose very well if the assistant strokes the blood out of the anterior chamber, while the operator stands ready with the instrument to perform rapidly the next operation (iridectomy or opening of the capsule) as soon as he can obtain a clear view of the chamber.

If the conjunctival flap should get in the way of the operator, the assistant should turn it back with a spatula. He should stroke the iris back into its place, if, during an extraction without iridectomy, the border of the pupil should become stretched against the lens as it makes its exit. Occasionally it may be necessary for the assistant to cut off the iris with the de Wecker scissors, if the operator, for example, in the excision of a prolapsed iris, holds and directs the eye with one hand while the other hand draws out the iris.

ANESTHESIA.

In all ophthalmic operations there is an advantage in being able to operate under local anesthesia. We use it on the most extensive scale, and endeavor to make it suffice wherever possible in the place of general anesthesia. In most operations on the eyeball itself, the co-operation of the patient in bringing the eye into the proper position will make the procedure much less difficult and will render unnecessary the

dangerous fixation of the eye during many operations. General anesthesia not only robs us of this factor, which is important for the faultless accomplishment of many operations, but also draws in its train another series of baneful influences which are important in patients subjected to any eye operation. Among these latter may be mentioned the dulled consciousness, the restlessness of the patient upon awakening, and often violent vomiting.

General anesthesia is therefore confined to the following cases:

1. Children who do not possess sufficient intelligence to keep quiet and conduct themselves sensibly.

2. Extensive operations in the orbit and on the lids, especially if the parts subjected to operation are sensitive on account of inflammatory conditions, such as exenteration, enucleation of inflamed eyes, extensive plastic operations, and similar procedures.

3. Severe operations on the eye itself, if local anesthesia is refused (especially in inflammatory glaucoma, excision of prolapsed iris in marked inflammatory conditions, etc.) or if the patient is not suitable for local anesthesia on account of other circumstances, such as pronounced blepharospasm, dementia, great irritability, etc.

Cocain anesthesia in operations on the eye itself is usually effected by a 3 per cent. solution, which is dropped into the eye several times during a period of ten minutes. The eye must be kept closed during this process of cocainization. If it remain open, the cocain may readily produce a dryness of the cornea with epithelial changes, which may not only impede the operation on account of cloudiness of the cornea, but may also cause the patient pain after the operation. If the eye is injected, a few drops of adrenalin solution should be instilled in the eye. The last application should be made just before the operation, as the constriction of the vessels caused by the adrenalin soon disappears and is replaced by a vascular relaxation which might cause considerable bleeding during the operation.

The advantages of cocain surpass those of all its substitutes. Its constricting influence on the vessels is an excellent property, which is of great value in every operation. The dilatation of the pupil which it causes is undesirable only in glaucoma operations, but can usually be prevented by a preceding instillation of eserin. Recently we have substituted for cocain in these cases a 3 per cent. solution of alypin, which must be supplemented by adrenalin, as it does not possess any vaso-constrictor properties. We also prefer alypin for sounding, for

extraction of foreign bodies from the surface of the cornea, etc., as it does not cause the patient the inconvenience of pupillary dilatation.

To produce a more profound anesthesia of the deeper parts of the eye, we drop some cocain-solution into the anterior chamber after it is opened in cases in which manipulation of the iris will presumably be painful, as in inflamed eyes. For this purpose only a sterilized solution should be used.

Injections of Cocain and Adrenalin.—For operations on the eyelids, ocular muscles, and enucleation an injection of a 1 per cent. cocain-solution will usually suffice. The addition of adrenalin (3 to 5 drops) to the cocain-solution will reduce the bleeding to a minimum. More accurate directions have been given in the description of the various operations, so that the best effect can be produced with the least quantity. Aimless injection in one place with neglect of other parts of the operative field will not produce the desired result. The dose of cocain which we employ in most operations is a minimal one, amounting at most to one Pravaz syringeful (0.01 gm. cocain), so that poisoning need not be feared in the most sensitive individuals. Only in enucleation is as much as 0.03 gram allotted, a quantity which is also far below the maximum dose.

Scopolamin and Morphin Narcosis.—In place of general chloroform or ether narcosis, the general anesthesia with scopolamin and morphin is recommended, carried out according to the following prescription. These solutions should be freshly prepared each time:

℞

Scopolamin. hydrobromat,	0.01
Aq. destillat	30.0

℞

Morphin. hydrochlorat,	0.075
Aq. destillat	9.0

Three hours before the operation 1 c.c. of each solution is injected under the skin of the upper arm, first injecting one solution, and then, without withdrawing the needle, making the other injection in the same place, but in another direction. After these injections the patient will become somnolent, quiet and so insensible of pain that the operation can often be performed in this stage with the aid of simultaneous cocainization of the eye. If the desired effect is not obtained, the same

dose of each solution must again be injected fifteen minutes before the operation. The patient then can be subjected to the operation in a completely relaxed condition, if at the same time the eye is made insensible by cocain. The advantage of this method is that the patient sleeps quietly for several hours after the operation, does not vomit, and exhibits no restlessness upon awakening. Moreover, after carrying out these methods, if a general narcosis is indicated, it can be rapidly produced by a few drops of ether or chloroform.

Bandaging After Operations on the Eye.—We employ the Fuchs' lattice in men, and the Snellen cup in women, the cup being attached by strips of adhesive. The latter is not advisable for men, because the plaster will not adhere to the bearded skin. In children and restless patients bandages are applied, and with the aid of starch a stiff dressing is produced, which will also sufficiently protect the eye against careless contact. The application of pressure-bandages has been described in connection with the operations in which they are indicated.

INDEX

A

Abduction, in strabismus, 115
Abscess, lachrymal, 1
  rupture of, 17
Abscission of cornea, 128, 245
Actual cautery, in corneal ulcers, 241
  in enucleation, 128
Adduction in strabismus, 115
Adrenalin, injections of, with cocain, 274
  in operations upon lachrymal apparatus, 3
Adults, young, linear extraction for total cataract, 192
Advancement, 108, 114, 116
  conjunctival fixation of muscle, 112
  fixation of muscle to limbus, 109
  in convergent strabismus, 108
  in divergent strabismus, 116
  in heterophoria, 118
  of rectus externus, 108
  of rectus internus, 116
  preferable to tenotomy, 115
  with tenotomy, 114, 116
After-cataract. *See Secondary Cataract*, 183
Alypin, 273
  in iridectomy for glaucoma, 193
Anagnostakis-Hotz operation, 51
Anatomy of lachrymal sac, 1
  anterior portion of orbit, 85
Anel's syringe, 26
Anesthesia, 272
  ganglion, 120
  infiltration, 2, 274
  in canthotomy, 66
  in enucleation, 120
  in glaucoma operations, 193
  in lachrymal probing, 26
  in strabismus operations, 101
  local, 120, 272
  of lachrymal apparatus, 2
  scopolamin-morphin, 122, 274
Ankyloblepharon, canthotomy for, 66
Annular synechia, operation for, 222
Anterior chamber, angle of, 193
    blood in, 172
    foreign bodies in, 253
    growth of epithelium into, 177
    in cataract extraction, 168
    in cyclodialysis, 213
    irrigation of, after cataract extraction, 147
  lachrymal crest, 1, 17
    resection of, 34
  lens capsule, incision of, 178
  sclerotomy, 203
  synechia, extensive, iridectomy in, 233
    following cataract extraction, 158
    glaucoma following, 203
    operations for, 203, 237
    Sachs' operation, 238
Aqueous, escape of, during discission through cornea, 178
Arlt median tarsorrhaphy, 73
  operation for pterygium, 262
    for trichiasis, 59
Assistant, duties of, 267
Axenfeld method of excision of palpebral lachrymal gland, 24

B

Bandaging after operation, 275
  of fixing eye in strabismus, 101
Barraquez operation of enucleation, 129
Basedow's disease, tarsorrhaphy for, 69
Beer-de Wecker operation for staphyloma, 245
Bichlorid of mercury, subconjunctival injections of, 175, 259
Bielschowsky, method of preventing overcorrection in squint operation, 114
Blennorrhea, canthotomy for, 65
Blepharophimosis, canthotomy for, 66

Blepharoplasty, 75
Blepharospasm, canthotomy for, 65
Bowman's operation of discission, 183
probes, 30
Büdinger's operation, 77
Buphthalmos, canthotomy for, 65
Burns, followed by ectropion, 47
complete closure of palpebral fissure for, 73

C

Canaliculi, cutting of, in sac operation, 11
Canaliculus, 26
dilatation of, 27
knife, Weber's, 29
slitting the, 28
superior, probing through, 32
Canthal ligament, internal, 4, 6
Canthoplasty, 66
Kuhnt operation for, 67
Canthotomy, 65
indications for, 65
in exenteration of orbit, 66, 131
Capsule forceps, 144
injury of, 201
Capsulotomy, 142, 161
Caries of orbital margin, 36, 45
Carlsbad needles, 49
Caruncle, retraction of, after tenotomy, 105
Cataract, 133, 178
after. *See Secondary Cataract*, 183
anterior chamber in extraction, 168
artificial ripening of, 135
binocular, 134
black, 162
capsular, 183
central, 135, 227
Chandler operation, 156
complicated, 156, 161
congenital, 178
couching for, 170
diabetic, 152
discission for, 178, 186
extraction of senile, 136
accidents and complications during operation, 157
backward displacement of lens, 169
collapse of cornea, 169
dislocation of the lens, 163
Cataract extraction, errors in making incision, 157
expulsive hemorrhage, 169
fixation of eyeball, 157
in expression of the cataract, 162
in iridectomy, 160
in opening the capsule, 161
prolapse of the vitreous, 164
complications during healing, 171
blood in anterior chamber, 172
cloudiness of cornea, 173
delayed closure of wound, 171
eversion of corneal flap, 172
increased tension, 176
infection, 174
iridocyclitis, 175
lens particles in pupil, 172
pain, 173
post-operative delirium, 173
prolapsed iris, 172
rupture of wound, 173
secondary infection, 176
duties of the assistant, 267
in capsule, 157
Kalt suture, 170
Kuhnt conjunctival flap, 170
method of Wenzel, 161
position of the patient, 133
preliminary iridectomy, 135
preparation of eye, 135
preparation of patient, 135
sterilization of hands and instruments, 136
with iridectomy, 136
with peripheral iridectomy, 156
without iridectomy, 153
following iridectomy for glaucoma, 201
glaucoma, after extraction, 176, 182
hard, 136
hemorrhage during extraction, 169
hypermature, 165
immature, 134
in children, discission for, 178
iridectomy in, 142, 160
knife, Graefe, 139
light-field in, 133
linear extraction for, 188
mature, treatment, 136
membranous, 184
monocular, treatment, 135

Cataract, Morgagnian, 165
needle operation for, 178
nuclear, 227
optical iridectomy, 227
overripeness of, 135, 165
perinuclear, 227
Pflüger operation, 156
ripe, 136
ripening of, artificial, 135
secondary, 183
discission of, 183
iridotomy, 184
senile, 133
simple extraction, 153
soft, 178, 188
discission of, 178
linear extraction for, 188
traumatic, 188
unripe, 134
Cautery puncture in conical cornea, 245
Chandler's method of cataract extraction, 156
Children, occlusion of lachrymal duct, 32
Choroid, detachment of, in cyclodialysis, 213
prolapse of, in scleral wounds, 236
Cicatricial ectropion, 45
from caries, 45
from extensive burns, 47
prevention of, 73
Cicatrix after iris prolapse, 237
fistulous, corneal transplantation for, 246
Cilia forceps, 62
inversion of, 51
Ciliary body, injury of, in cyclodialysis, 215
prolapse of, in scleral wounds, 236
Cocain, anesthesia, 273
ganglion anesthesia with, 120
in enucleation, 120
in operations upon the lachrymal apparatus, 2
in probing lachrymo-nasal duct, 26
in strabismus operations, 102
Collodion for entropion, 62
Congenital cataract, discission for, 178
ptosis, 84
Conical cornea, 244
cautery puncture, 245
trephining of, 244
probe, 27
Conjunctiva, rabbit's, transplantation of, 80
tearing of, during cataract extraction, 157
transplantation of, de Wecker's method, 236
Conjunctival flaps, in corneal transplantation, 247
in extraction operation, 142
in iris prolapse, 234
in large scleral wounds, 236
in symblepharon, 80
sac, sterilization of, 135
Conjunctivitis, granular, excision of upper transitional fold, 266
expression for, 264
extirpation of tarsus, 266
grattage in, 265
Conjunctivoplasty, 234
in corneal injuries, 235
in large scleral wounds, 236
in prolapse of iris, 234
Convergent strabismus, 102
Cornea, abscission of, 128, 245
cauterization of, 241
central opacity of, 227
cloudiness of, after cataract extraction, 173
collapse of, after cataract extraction, 169
conical, 244
discission through, 179
infection of, following cataract extraction, 173
injuries of, 235
operations on, 241
paracentesis of, 220, 241
purulent infiltration of after cataract extraction, 174
ulcer of, 241
Saemisch section, 241
sloughing ulcer of, 241
splitting of, 241
staphyloma of, 245
tattooing of, 229, 242
Froelich's method, 243
transplantation of, 246
trephining of, 238, 244
ulcers of, 241
wounds of, conjunctival flaps for, 235
with iris prolapse, 232

Corneal erosion in excision of lachrymal sac, 5, 16
puncture, 241
staphyloma, operation for, 245
transplantation, 246
partial, 247
total, 246
trephine, 248
trephining, 238, 244
ulcers, 241
after Motais operation for ptosis, 100
Corrosive sublimate, subconjunctival injection of, 260
Cortical substance, removal of, in cataract extraction, 148, 155
Couching cataract, 170
Counteracting sutures in tenotomy, 107
Counter-puncture in extraction operation, 139, 157
Crest, anterior lachrymal, 1, 17, 34
Crystalline lens. *See Lens.*
Curet, Daviel's, in foreign bodies in eyeball, 254
Cureting naso-lachrymal duct, 14
Cyanid of mercury, subconjunctival injection of, 260
Cyclodialysis (Heine), 212
complications of, 216
indications for, 213
results of, 217
Cyst of iris as cause of secondary glaucoma, 222
Cystoid cicatrix, operation for, 246
Cystotome, 146

D

Dacryocystitis, acute, 17
chronic, 17
fistulous, 17
Dacryocysto-Rhinostomia, Toti, 33
Daviel's spoon in cataract operation, 136, 148, 268
in foreign bodies, 254
Deep fascia in excision of lachrymal sac, 6
Descemet's membrane, detachment of, in cyclodialysis, 216
Desmarres elevator, 166
Detachment of Descemet's membrane in cyclodialysis, 216
of conjunctiva in enucleation, 122
Detachment of retina, following prolapse of vitreous, 169
posterior sclerotomy for, 259
De Vincentiis's operation, 217
De Wecker's anterior sclerotomy, 203
method of excision of palpebral lachrymal gland, 22
method of transplantation of the conjunctiva, 236
operation for staphyloma, 245
pince-ciseaux, 142
Diabetic cataract, 152
Dieffenbach's blepharoplasty, 75
Dieffenbach-Büdinger operation, 77
Dilaceration of secondary cataract, 183
Dilatation of the canaliculus, 27
of the lachrymal sac, 18
Dionin, 175, 176
Discission, 178
Bowman's, with two needles, 183
for congenital cataract, 178
for high myopia, 180
for secondary cataract, 183
glaucoma after, 182
needles, 178
of a transparent lens, 180
prolapse of vitreous in, 182
through cornea, 178
through sclera, 186
with two needles, 183
Disk, movable stenopaic, 228
Dislocation of lens, 169, 202, 221
Divergent strabismus, 116
Ducts, lachrymal, 16
naso-lachrymal, cureting, 14
probing, 30
Duties of ophthalmic assistant, 267

E

Ear cartilage, use of flaps from, 77
Ectasia of sclera as cause of secondary glaucoma, 221
as contraindication for advancement, 113
enucleation for, 120
Edema of lids, canthotomy for, 65
Ectropion, 36
acute, 36
chronic, 45
cicatricial, 45

Ectropion following fistulous dacryocystitis, 18
from caries, 45
from extensive burns, 47, 73
paralytic, 45, 69
prevention of, after burns, 73
senile, 37
spasmodic, 36
spastic, 36
Electrolytic epilation for trichiasis, 61
Electromagnet, 252
Elevator, Desmarres, 166
Elliott operation for glaucoma, 219
Elschnig's ganglion anesthesia in enucleation, 120
Entropion, 51, 62
Gaillard suture, 63
Graefe operation, 63
senile, 63
spasmodic, 62
spastic, 62
use of collodion, 62
Enucleation, 119, 122
abscission of cornea, 128, 245
complications of, 127
for foreign bodies, 256
for painful blind eyes, 119
ganglion anesthesia, 120
in irido-cyclitis, 176
in panophthalmitis, 120, 175
in prolapse of ciliary body and choroid, 237
indications for, 119
orbital hemorrhage in, 128
perforation of sclera in, 128
resection of optic nerve in, 128, 130
substitute operations, 120
with implantation of artificial globe in Tenon's capsule, 129
with implantation of fat in Tenon's capsule, 129
Epilation in trichiasis, 61
Erosion of the cornea in excision of lachrymal sac, 5, 16
Eserin after simple extraction, 155
in glaucoma operations, 207
in iridectomy for glaucoma, 194
Ethmoid cells, resection of, 35
Eversbusch operation for ptosis, 85
contraindications, 90
Eversbusch operation, results of, 89
Eversion of eyelid, 36
Evisceration of eyeball, 129
during panophthalmitis, 120, 129
with insertion of artificial vitreous, 129
Excision, for pterygium, 262
for senile entropion, 63
of corneal cicatrix, 246
of iris, after prolapse, indications, 231
of lachrymal sac, 1
of palpebral lachrymal gland, 22
of tarsus in ectropion, 39
Exenteration of orbital cavity, 131
Exenteratio orbitæ, canthotomy for, 66
Exophoria, 117
Exophthalmic goiter, tarsorrhaphy for, 69
Exophthalmos following tenotomy, 104
Expression of cataract, 148, 162
of trachoma granules, 264
Expressor, Kuhnt's, 265
Expulsive hemorrhage in cataract extraction, 169
in iridectomy for glaucoma, 202
External rectus, advancement of, 108
tenotomy of, 116
tarsorrhaphy, 69
Extirpation of lachrymal gland, 22
of lachrymal sac, 1
of tarsus for trachoma, 266
Extraction of cataract. *See Cataract.*
of foreign bodies from the interior of the eye, 249
of non-magnetic bodies, 255
iron splinters by magnet operation, 252
Eye, extraction of foreign bodies from, 249
preparation of, for cataract extraction, 135
speculum, use of, 267
Eyeball, collapse of, due to fluid vitreous, 169
enucleation of, 119, 122
evisceration of, 129
foreign bodies in, 249
Mules' operation, 129
optico-ciliary neurotomy, 130, 202
rupture of, 119
steel in, 249
wounds of, 249
Eyelid, blepharoplasty, 75
Dieffenbach operation, 75

Eyelid, Dieffenbach-Büdinger operation, 77
eversion of, 36
everting with Groenholm spoon, 258
Fricke operation, 75
inversion of, 51
lacerations of, 36
new-growths, excision of, 75
plastic operations with pedicled flaps, 75
restoration of, 76
Thiersch graft, 75
Wolfe graft, 75
Eye-muscles, operations on, 101

F

Fascia, in excision of lachrymal sac, 5, 6, 14
tarso-orbital, 24
Fat, implantation of in Tenon's capsule, 129
Fergus operation for glaucoma, 219
Filtration scar after sclerectomy, 210
Fistula of lachrymal gland, 32
of lachrymal sac, 17
Fistulous cicatrix of cornea, 246
Fixation forceps 136
Flap, conjunctival, in corneal transplantation, 247
in extraction operation, 142
in injuries, 235
in iris prolapse, 234
in symblepharon, 80
pedicled, in eyelid operations, 75
skin graft, in operation for cicatricial ectropion, 46
Flarer operation for trichiasis, 59
Forceps, capsule, 144
cilia, 62
fixation, used in cataract extraction, 136
iris, 142
Knapp's roller, 264
Foreign bodies in eyeball, 249
diagnosis of, 249
extraction of, 252
magnetic, 252
non-magnetic, 255
Fricke operation on eyelids, 75
Fricker's method of excision of palpebral lachrymal gland, 25
Froelich's method of tattooing the cornea, 243
Frost-Lang operation of implantation, 129
Fuchs' keratoplasty, 246
lattice bandage, 152
method of tarsorrhaphy, 69
treatment to avert expulsive hemorrhage in cataract extraction, 170

G

Gaillard's suture for entropion, 63
Galvanocautery. *See Actual Cautery.*
Ganglion anesthesia, 120
Giant magnet, 252
Gland, palpebral lachrymal, excision of, 22
Glasses in strabismus, 101
Glaucoma, 193
absolute, 130, 202
optico-ciliary neurotomy in, 130
acute, 193
after cataract extraction, 176
after discission, 182
anterior sclerotomy (de Wecker), 203
chronic, 203
cyclodialysis in, 212
de Vincentiis's operation, 217
due to anterior synechia, 203, 213, 237
due to growth of epithelium into anterior chamber, 177
Elliott operation, 219
Fergus operation, 219
hemorrhagic, 202, 213
incision with Graefe knife, 197
with keratome, 195
inflammatory, 193
intraocular tension, determination of, 223
iridectomy for, 193
expulsive hemorrhage after, 202
for secondary glaucoma, 221
indications for, 193
iridodialysis after, 200
prolapse of vitreous, 202
spontaneous rupture of lens capsule in, 201
irido-sclerectomy, 207
malignant, 213
non-inflammatory, 203
posterior sclerotomy, 211
primary, 193
scleral puncture in, 211
trephining, 219
sclerectomy and irido-sclerectomy, 207
sclerotomy, 203, 211

Glaucoma, secondary, 213, 220
iridectomy in, 221
simple, 203
Graefe. See von Graefe.
Granular lids, 264
Grattage, 265
Groenholm spoon for everting lid, 258

H

Haab's giant magnet, 252
Heine's cyclodialysis, 212
Hemorrhage after cataract extraction, 169
after iridotomy, 185
after tenotomy, 104
during iridectomy for glaucoma, 200
expulsive, in cataract extraction, 169
in iridectomy for glaucoma, 202
in cyclodialysis, 216
in enucleation of eyeball, 128
Hernia lentis, 202
Hess operation for ptosis, 90
contraindications, 95
indications, 90
results of, 94
Hirschberg electromagnet, 252
Hollow probes, 32
Hook, blunt, in iridectomy for cataract, 160
Hooks in excision of lachrymal sac, 15
Hotz-Anagnostakis operation, 51

I

Implantation of artificial globe in Tenon's capsule after enucleation, 129
of fat in Tenon's capsule after enucleation, 129
India-ink in tattooing of cornea, 243
Infection following cataract extraction, 174
Infiltration anesthesia, 2, 120, 274
solution, 3, 274
Injection of cocain in enucleation, 120
ganglion anesthesia, 120
subconjunctival, 241, 259
in serpiginous ulcer, 241
Injuries by foreign bodies, 249
Injury to lachrymal canaliculus during dilatation, 27
sac during excision, 19
lens capsule in iridectomy for glaucoma, 201
in trephining the cornea, 238
Ink, India, in tattooing of cornea, 243
Instruments, sterilization of, 136
Intermarginal incision in Kuhnt-Szymanowski operation, 38
Internal canthal ligament, 4, 6
palpebral ligament, 1
rectus advancement of, 116
tenotomy of, 103, 117
tarsorrhaphy, 72
Intraocular tension, determination of, 223
Iridectomy after serpiginous ulcer, 242
after wounds of globe, 231
complications of in cataract extraction, 160
extraction of cataract, without, 153
extraction of cataract with, 136
extraction of cataract with peripheral, 156
for nuclear cataract, 227
hemorrhage during cataract extraction, 169
in glaucoma, 193, 221
cataract following, 201
expulsive hemorrhage in, 202
hemorrhage during, 200
indications for, 193
iridodialysis after incision for, 200
prolapse of vitreous in, 202
spontaneous rupture of lens capsule, 201
subluxation of lens, 202
method of Wenzel, 161
optical, 227
peripheral, in cataract extraction, 156
preliminary, in cataract extraction, 135
Iridocyclitis, after cataract extraction, 175
Iridodialysis, after incision for iridectomy, 200, 206
in cyclodialysis, 216
Iridosclerectomy, 207
Iridotomy, hemorrhage after, 185
in secondary cataract, 184
precorneal, 230
Iris, atrophic, in glaucoma, 200
cyst of, as a cause of secondary glaucoma, 222
forceps, 142
operations for prolapse of, 231
prolapse of, after simple extraction, 155
conjunctivoplasty in, 234

Iris, prolapse of, in anterior sclerotomy, 205
in extraction without iridectomy, 155
operations for, 231
scissors, 142
time for excision after prolapse, 239
transfixion of, in iridectomy for glaucoma, 222
Iritis, acute, corneal puncture in, 220
Iron splinters in eye, 249
Irrigation of anterior chamber after cataract extraction, 147

J

Jaesche-Arlt operation for trichiasis, 59

K

Kalt suture, 170
Keratitis profunda, corneal puncture in, 221
Keratectomy, 128, 245
Keratoconus, 244
Keratome, incision in glaucoma, 195
Keratoplasty, 246
partial, 247
total, 246
Knapp's operation for trachoma, 264
roller-forceps, 264
Knife, Graefe, incision for cataract, 139
in anterior sclerotomy, 204
incision for glaucoma, 197
operations for anterior synechia, 239
posterior sclerotomy, 211, 259
Saemisch section, 241
sclerectomy, 207
transfixion for seclusion of pupil, 222
Weber's, 29
Kuhnt's conjunctival flap, 170
conjunctivoplasty, 234
expressor, 265
operation for canthoplasty, 67
for senile ectropion, 37
tarsal enucleation for trichiasis, 58
for trachoma, 266
Kuhnt-Müller operation for ectropion, 37
Kuhnt-Szymanowski operation for senile ectropion, 38

L

Lachrymal abscess, 1, 17
rupture of, 17
apparatus, 1
bone, necrosis of, 18
Lachrymal canaliculus, 26
dilatation of, 27
slitting of, 28
superior, probing through, 32
crest, anterior, 1 , 17, 34
posterior, 10
fistula, 17, 18
gland, excision of palpebral, 22
Axenfeld method, 24
de Wecker's method, 22
fistula of, 32
Fricker's method, 25
hemorrhage during excision, 24
indications for, 22
results of operation, 25
passages, test for permeability of, 26
probe, Bowman, 30
conical, 27
hollow, 32
probing, 25
anesthesia, 26
contraindications to use of probes, 32
diagnosis of stenosis, 26
indications for, 25
slitting the canaliculus, 28
through superior canaliculus, 32
Weber's knife, 29
sac, anatomy of, 1
acute inflammation of, 17
disease, varieties of, 17
acute dacryocystitis, 17
chronic dacryocystitis, 17
dilated sac, 18
fistulous dacryocystitis, 17
tuberculosis, 18
excision of, 1
accidents and complications, 18
after-treatment, 16
anesthesia, 2
cureting naso-lachrymal duct, 14
exposing the sac, 7
fistula following, 17
hemorrhage during, 11
indications for, 1
infiltration solution, 3
injury of sac during, 19
locating the sac, 18
opening into the orbit, 19
retained portions of sac, 20
results of, 21

Lachrymal sac, excision of, suppuration after, 20
Toti's dacryocysto-rhinostomia, 33
tuberculous disease, 18
syringe, introduction of, 26
Lachrymo-nasal duct, cureting, 14
occlusion of, in new-born, 32
probing of, 30
Lagophthalmos, after Motais operation for ptosis, 100
Lagrange operation for glaucoma, 207
Lamp, Sachs', 256
Latent outward deviation, 117
Lattice bandage, Fuchs', 152, 275
Lens, backward luxation of, 169
discisson for cataractous, 178
transparent, 180
dislocation of, 169, 202, 221
extraction of cataractous, 133
injury to, during iridectomy for glaucoma, 201
in trephining cornea, 238
linear extraction of soft cataractous, 188
removal of, in high myopia, 180
subluxation of, in iridectomy for glaucoma, 202
Lens capsule, anterior, incision of, 178
spontaneous rupture of, in iridectomy for glaucoma, 201
wound of, in excision of iris, 201
Lid-elevator, 166, 258
Lid, ectropion, 36
trichiasis and entropion, 51
Lids, granular. *See Conjunctivitis Granular.*
Ligament, internal canthal, 4, 6
palpebral, 1
Light-field in cataract, 133
Linear extraction, 188
for soft cataract, 188
for total cataract in young adults, 192
Local anesthesia, 120, 272
Loop, Weber's, 164
Lower lid, ectropion, 36
trichiasis and entropion, 51
Luxation of lens as cause of secondary glaucoma, 220
Lyritza operation for trachoma, 266

M

Magnet, Haab, 252
Hirschberg, 252
operation, 252
Magnetic foreign bodies, 252
Malar bone, caries of, 36, 45
Malignant growths, operation for, 75
glaucoma, 213
McReynolds operation for pterygium, 262
Median tarsorrhaphy (Arlt), 73
Mercury, subconjunctival injections of, 241, 259
Metallic foreign bodies, removal of, 249
Method of excision of palpebral lachrymal gland, 22
Middle turbinated bone, resection of, 34
Morgagnian cataract, 163
Motais operation for ptosis, 96
complications of, 100
corneal ulceration after, 100
lagophthalmos after, 100
staphyloma after, 100
Movable stenopaic disk, 228
Mucous membrane flaps, for trichiasis, 60
Mules' operation, 129
Müller operation for ectropion, 37
tear-sac speculum, 5
Muscles, operations on, 101
Myopia, discission for, 180
indications for discission, 181

N

Naso-lachrymal duct, cureting, 14
occlusion of, in new-born, 32
probing of, 30
Needle, knife, 178
operation for congenital cataract, 178
for secondary cataract, 183
Needles, discission, 178
for tattooing cornea, 243
Nerve, optic, resection of, 128, 131
Neurectomy, optico-ciliary, 131
Neurotomy, optico-ciliary, 130, 202
New-born children, probing in, 32
Non-magnetic foreign bodies, 255

O

Occlusion of lachrymal duct in new-born children, 32
Ocular muscles, operations upon, 101

Ocular muscles, paralysis of, 118
Opacities, corneal, 227
Ophthalmic assistant, duties of, 267
Ophthalmoscope, diagnosis in foreign body injuries, 250
Optic nerve, resection of, 128, 131
Optical iridectomy, 227
Optico-ciliary neurectomy, 131
neurotomy, 130, 202
Orbicularis muscle in excision of lachrymal sac, 5
Orbit, anatomy of, 85
removal of contents of, 131
Orbital cavity, exenteration of, 131
margin, caries of, 36, 45

P

Pagenstecher's sutures for ptosis, 95
Palpebral fissure, complete closure of, 73
operation for lengthening, 65, 66
for shortening, 69
lachrymal gland, excision of, 22
Panas operation for ptosis, 96
for trichiasis and entropion, 56
Panophthalmitis, enucleation in, 120, 175
evisceration in, 120, 129
Paquelin cautery in enucleation, 128
Paracentesis of cornea, 220, 241
Paraffin-covered plates for symblepharon, 82
Paralysis of ocular muscles. *See Ocular Muscles.*
Paralytic ectropion, 45, 69
squint, 118
Partial keratoplasty, 247
trichiasis, 59
Passing of probes in new-born children, 32
Pedicled flaps in eyelid operations, 75
Penetrating wounds of eyeball, 249
Perinuclear cataract, 227
Peripheral iridectomy, 156
Pflüger, method of cataract extraction, 156
Pince-ciseaux, de Wecker's, 142
Plastic operation on eyelids, Dieffenbach, 75
Dieffenbach-Büdinger, 77
for symblepharon, 80
for trichiasis, 60
Fricke, 75
with pedicled flaps, 75
Posterior lachrymal crest, 10
Posterior sclerotomy, for detachment of retina, 259
in glaucoma, 211
Post-operative delirium, 173
Pravaz's syringe, 2, 121
Precorneal iridotomy, 230
Preliminary iridectomy, 135
Primary glaucoma, operation for, 193
Probes, Bowman's, 30
conical, 27
contraindications to use of, 32
hollow, 32
Probing of naso-lachrymal duct, 30
contraindications, 32
in new-born, 32
superior canaliculus, 32
Prolapse of ciliary body and choroid in scleral wounds, 236
of iris, after simple extraction, 155
conjunctivoplasty in, 234
in anterior sclerotomy, 205
in linear extraction for soft cataract, 191
operations for, 231
time for excision after, 239
of vitreous, during discission, 182
in cataract extraction, 164
in iridectomy for glaucoma, 202
Prothesis after symblepharon operation, 82
Pterygium, 261
Arlt operation, 262
excision of, 262
inversion operation, 261
McReynolds operation for, 262
transplantation, 262
Ptosis, after excision of lachrymal gland, 24
contraindications for operation, 84
Eversbusch operation, 85
Hess operation, 90
Motais operation, 96
Pagenstecher's sutures, 95
Panas operation, 96
Puncture of cornea, 220, 241
of sclera for retinal detachment, 259
Pupil, connective-tissue membranes in, 230
seclusion of, operation for, 222

R

Rabbit's conjunctiva, transplantation of, 80
Reclination for cataract, 170

Rectus externus, advancement of, 102, 114
advancement and resection of, 108
tenotomy of, 116
internus, advancement of, 116
tenotomy of, 103, 117
Reisinger's double tenaculum, 164, 166
Removing the lachrymal sac, 8
Resection of lachrymal sac, 1
of nasal bone, 34
of optic nerve in enucleation, 131
Retina, detachment of, posterior sclerotomy for, 259
following prolapse of vitreous, 169
Retraction of caruncle following tenotomy, 105
Rhinostomia, Toti's dacryocysto, 33
Roentgen rays in foreign bodies in eyeball, 251
Rogman's operation for complete symblepharon, 81
Roller-forceps, Knapp's, 264

S

Sac, excision of lachrymal, 1
Sachs' lamp, in foreign body in vitreous, 256
operation for anterior synechia, 238
Saemisch section in serpiginous ulcer, 241
Salt-solution, subconjunctival injections of, 259
Scars, cystic, 246
Schiötz tonometer, 223
Scissors, enucleation, 124
iris, 142
Sclera, discission through, in secondary cataract, 186
extraction of foreign bodies through, 254
rupture of, 119
Scleral puncture in glaucoma, 211
sutures, 236, 256
trephining, 219
wounds, treatment of, 236
Sclerectomy, 207
anterior, 203
posterior, for retinal detachment, 259
in glaucoma, 211
Scopolamin-morphin anesthesia, 122, 274
Seclusion of pupil, operation for, 222
Secondary cataract, 183
capsulotomy, 184
Secondary cataract, discission, 183
through sclera, 186
with two needles, 183
iridotomy, 184
glaucoma, 220
iridectomy, 221
paracentesis, 220
transfixion, 222
Senile cataract, extraction of, 136
ectropion, 37
Kuhnt operation, 37
Kuhnt-Syzmanowski operation, 38
Kuhnt-Müller operation, 37
entropion, 63
Graefe operation, 63
Serpiginous ulcer, iridectomy after healing, 242
Saemisch section in, 241
subconjunctival injections in, 241
thermocautery in, 241
Sideroscope, in foreign bodies in eyeball, 251
Simple extraction, 153
glaucoma, 203
Skin grafting, for ectropion, 45
for symblepharon, 80
Thiersch method, 75
with pedicle, 46, 75
without pedicle, 46, 75
preparation of the flaps, 47
Wolfe graft, 75
Slitting of lachrymal canaliculus, 28
Snellen's cup, 151
operation for trichiasis, 55
suture for spasmodic ectropion, 36
Soft cataract, linear extraction for, 188
Sounds, use of, in lachrymal disease, 25
Spasmodic ectropion, 36
Snellen suture, 36
entropion, 62
Gaillard suture, 63
Spastic ectropion, 36
entropion, 62
Spatula, in cataract extraction, 136, 150
Speculum, lid, indications for use of, 267
Müller's tear-sac, 5
Spencer Watson operation for partial trichiasis, 59
Splitting of cornea, 242
Spontaneous rupture of lens capsule in iridectomy for glaucoma, 201

Spoon, Daviel's, in expression of cataractous lens, 136, 148, 268
in foreign bodies in eyeball, 254
Squint, paralytic, indications for operation in, 118
Staphyloma, after Motais operation for ptosis, 100
Beer-de Wecker operation, 245
operations for, 128, 245
Steel in eyeball, 249
Stenopaic disk, movable, 228
Stenosis of lachrymal duct, 26
Stent's composition for prothesis, 82
Strabismus, 101
abduction in, 115
adduction in, 115
advancement of rectus externus, 108
of rectus internus, 116
anesthesia, 101
bandaging of fixing eye, 101
convergent, 102
advancement of rectus externus, 108
indications for operation, 102
spectacle treatment, 101
stereoscope in, 101
tenotomy of rectus internus, 103
counteracting suture after tenotomy, 107
divergent, 116
advancement of rectus internus, 116
after tenotomy of rectus internus, 117
exophoria, 117
glasses in, 101
paralytic, 118
supporting suture after tenotomy, 106
tenotomy of rectus externus, 116
of rectus internus, 103, 114
Subconjunctival injections, 241, 259
for serpiginous ulcer, 241
Subcutaneous injection of cocain-solution, 2, 26, 65, 86, 274
of scopolamin-morphin, 122, 274
Subluxation of lens in iridectomy for glaucoma, 202
Superficial fascia in excision of lachrymal sac, 5
Superior maxillary process, resection of, 34
rectus muscle in ptosis operation, 96
Supporting sutures, in tenotomy, 106
Suppuration, after excision of lachrymal sac, 20
Sutures, counteracting, in tenotomy, 107
Pagenstecher's, for ptosis, 95
scleral, 236, 256
Snellen, for spasmodic ectropion, 36
supporting, in tenotomy, 106
Symblepharon, 80
complete, of lower lid, 81
partial, 80
Rogman's operation, 81
total, 82
Sympathetic inflammation, after cataract extraction, 175
after injuries, 119
Synechia, annular, operation for, 222
anterior, extensive, iridectomy in, 233
following cataract extraction, 158
glaucoma following, 203, 213, 237
operations for, 203, 237
Sachs' operation, 238
Syringe, Anel's, 26
Pravaz's, 2, 121
Szymanowski operation for senile ectropion, 38

T

Tarsal enucleation for trichiasis, 58
Tarso-orbital fascia, 24
Tarsorrhaphy, 69
Arlt operation, 73
for Basedow's disease, 69
Fuchs' operation, 69
Tarsus, excision of, for ectropion, 39
extirpation of, for trachoma, 266
Tattooing needles, 243
of cornea, 229, 242
Froelich's method of, 243
Tear-duct, blennorrhea of, 1
Tear-sac speculum (Müller's), 5
Tenaculum, blunt, in operation for anterior synechia, 232, 246
pointed, to open lens capsule, 161
Reisinger's double, 164
Tenon's capsule, artificial globe in, after enucleation, 129
implantation of fat in, after enucleation, 129
Tenotomy, 103, 116

Tenotomy and advancement performed simultaneously, 114, 116
counteracting sutures in, 107
rectus, externus, 116
internus, 103
accidents and complications, 104
hemorrhage, 104
regulating the effect of, 105
results of, 105
retraction of caruncle, 105
supporting suture in, 106
Tension, intraocular, determination of, 223
Thermocautery in serpiginous ulcers, 241
Thiersch skin grafting method, 75
Third nerve, paralysis of, 84
Thread operation for ptosis, subcutaneous, 90, 95
Tonometer, Schiötz, 223
Tonometry, 223
Total cataract of young adults, 192
keratoplasty, 246
staphyloma, operation for, 129, 245
symblepharon, operations for, 82
Toti, dacryocysto-rhinostomia, 33
results of operation, 35
Trachoma, 264
canthotomy for, 65
excision of upper transitional fold, 266
expression for, 264
extirpation of tarsus for, 266
forceps, Knapp's, 264
grattage in, 265
Lyritza method, 266
Transfixion of iris in iridectomy for glaucoma, 222
for seclusion of pupil, 222
Transparent lens, discission of, 180
Transplantation of conjunctiva, de Wecker's method of, 236
cornea, 246
partial, 247
total, 246
von Hippel's, 247
for pterygium, 262
Trephine, corneal, von Hippel's, 248
Trephining of cornea, 238, 244
for anterior synechia, 238
of sclera for glaucoma, 219
Trichiasis, 51
electrolytic epilation, 61
Flarer operation, 59
Hotz-Anagnostakis operation, 51
Jaesche-Arlt operation, 59
Kuhnt tarsal enucleation, 58
mucous membrane flaps, 60
Panas operation, 56
Snellen operation, 55
Spencer Watson operation, 59
Trichiasis and entropion, 51
Tuberculous lachrymal sac, 18

U

Ulcer, serpiginous, operations for, 241
Upper lid, everting with Groenholm spoon, 258
spasmodic ectropion of, 36

V

Vision, after injuries by foreign bodies, 249
Vitreous, extraction of foreign bodies from, 252
fluid, in myopia, 183
prolapse of, after cataract extraction, 166
during discission, 182
in iridectomy for glaucoma, 202
in linear extraction for soft cataract, 192
in sclerectomy, 209
Von Graefe operation for senile entropion, 63
cataract knife, 139
knife for incision in glaucoma, 197
for transfixion operation, 222
Von Hippel's corneal transplantation, 247
trephine, 248

W

Watson operation for partial trichiasis, 59
Weber's knife, 29
loop, 164
Wenzel, method of cataract extraction, 161
Wolfe graft, 75
Wounds of cornea, with iris prolapse, 232
of lens capsule in iridectomy, 201, 232
in trephining cornea, 238
of sclera, 236